This is a digital copy of a book that was preserved for generations on library shelves before it was carefully scanned by Google as part of a project to make the world's books discoverable online.

It has survived long enough for the copyright to expire and the book to enter the public domain. A public domain book is one that was never subject to copyright or whose legal copyright term has expired. Whether a book is in the public domain may vary country to country. Public domain books are our gateways to the past, representing a wealth of history, culture and knowledge that's often difficult to discover.

Marks, notations and other marginalia present in the original volume will appear in this file - a reminder of this book's long journey from the publisher to a library and finally to you.

Usage guidelines

Google is proud to partner with libraries to digitize public domain materials and make them widely accessible. Public domain books belong to the public and we are merely their custodians. Nevertheless, this work is expensive, so in order to keep providing this resource, we have taken steps to prevent abuse by commercial parties, including placing technical restrictions on automated querying.

We also ask that you:

+ *Make non-commercial use of the files* We designed Google Book Search for use by individuals, and we request that you use these files for personal, non-commercial purposes.
+ *Refrain from automated querying* Do not send automated queries of any sort to Google's system: If you are conducting research on machine translation, optical character recognition or other areas where access to a large amount of text is helpful, please contact us. We encourage the use of public domain materials for these purposes and may be able to help.
+ *Maintain attribution* The Google "watermark" you see on each file is essential for informing people about this project and helping them find additional materials through Google Book Search. Please do not remove it.
+ *Keep it legal* Whatever your use, remember that you are responsible for ensuring that what you are doing is legal. Do not assume that just because we believe a book is in the public domain for users in the United States, that the work is also in the public domain for users in other countries. Whether a book is still in copyright varies from country to country, and we can't offer guidance on whether any specific use of any specific book is allowed. Please do not assume that a book's appearance in Google Book Search means it can be used in any manner anywhere in the world. Copyright infringement liability can be quite severe.

About Google Book Search

Google's mission is to organize the world's information and to make it universally accessible and useful. Google Book Search helps readers discover the world's books while helping authors and publishers reach new audiences. You can search through the full text of this book on the web at `http://books.google.com/`

BOSTON
MEDICAL LIBRARY
8 THE FENWAY

TRANSACTIONS

OF THE

PATHOLOGICAL SOCIETY OF LONDON.

VOLUME NINTH.

INCLUDING THE REPORT OF THE PROCEEDINGS FOR THE SESSION 1857-8.

LONDON:
PRINTED FOR THE SOCIETY BY J. W. ROCHE, 1, LUCAS STREET, ROTHERHITHE.
1858.

30004

The present publication being the Ninth Volume of Transactions, constitutes the Twelfth published Annual Report of the Pathological Society's proceedings.

The Council think it right to repeat, that the exhibitors are alone responsible for the descriptions given of the Specimens exhibited by them, the only change made in the Reports furnished by the authors being such verbal alterations as were absolutely necessary.

53, Berners Street, Oxford Street,
September, 1858.

TABLE OF CONTENTS

OF VOLUME IX.

List of Presidents and of Officers and Members during the Session 1857-8. 1

List of Specimens Exhibited during the Session 1857-8. xvii

List of Plates xliii

List of Lignographs xliv

Diseases, etc. of the Nervous System . . . 1

Diseases, etc. of the Organs of Respiration . . 28

Diseases, etc. of the Organs of Circulation . . 58

Diseases, etc. of the Organs of Digestion . . 188

Diseases, etc. of the Genito-Urinary Organs . . 295

Diseases, etc. of the Osseous System . . . 343

Diseases, etc. of the Organs of Special Sense . . 362

Tumours, etc. 367

Diseases, etc. of the Ductless Glands . . . 400

Miscellaneous Specimens, including Skin, Entozoa, and Malformation, etc. 427

Specimens from the Lower Animals 456

Index 465

Former Presidents.

ELECTED	
1846	CHARLES J. B. WILLIAMS, M.D., F.R.S.
1848	CHARLES ASTON KEY, Esq.
1850	PETER MERE LATHAM, M.D.
1852	CÆSAR H. HAWKINS, Esq., F.R.S.
1853	BENJAMIN GUY BABINGTON, M.D., F.R.S.
1855	JAMES MONCRIEFF ARNOTT, Esq., F.R.S.
1857	THOMAS WATSON, M.D.

OFFICERS AND COUNCIL

OF THE

Pathological Society of London,

ELECTED AT

THE GENERAL MEETING, JANUARY 5, 1858.

President.

THOMAS WATSON, M.D.

Vice-Presidents.

WILLIAM JOHN LITTLE, M.D.
JAMES RISDON BENNETT, M.D.
BENJAMIN GUY BABINGTON, M.D., F.R.S.
C. J. B. WILLIAMS, M.D., F.R.S.
JAMES MONCRIEFF ARNOTT, Esq., F.R.S.
WILLIAM FERGUSSON, Esq.
JOHN SIMON, Esq., F.R.S.
GEORGE BUSK, Esq., F.R.S.

Treasurer.

RICHARD QUAIN, M.D.

Council.

WILLIAM BALY, M.D, F.R.S.
JOHN SYER BRISTOWE, M.D.
WILLIAM CAMPS, M.D.
THOS. HARRINGTON TUKE, M.D.
THEOPHILUS THOMPSON, M.D., F.R.S.
SAMUEL WILKS, M.D.
THOMAS BEVILL, PEACOCK, M.D.
JOHN CLARKE, L.R.C.P.
A. WHYTE BARCLAY, M.D.
LIONEL S. BEALE, M.D., F.R.S.
JOHN MORGAN, Esq.
WILLIAM AUGUSTUS HILLMAN, Esq.
JONATHAN HUTCHINSON, Esq.
JOHN COOPER FORSTER, Esq.
JOHN WOOD, Esq.
THOMAS BLIZARD CURLING, Esq., F.R.S.
ALEXANDER SHAW, Esq.
GEORGE CRITCHETT, Esq.
JOHN JAMES PURNELL, Esq,
J. CHARLES LANGMORE, Esq.

Honorary Secretaries.

JOHN WILLIAM OGLE, M.D. | MITCHELL, HENRY, Esq.

*** *Members are requested to indicate to the Secretaries corrections when necessary.*

LIST OF MEMBERS OF THE SOCIETY.

Honorary Members.

ALISON, WILLIAM PULTENEY, D.C.L., M.D., F.R.S. Professor of Medicine in the University of Edinburgh.

ANDRAL, G., M.D., Professor in the Faculty of Medicine, Paris.

*BENTLEY, EDWARD, M.D., (formerly Honorary Secretary), Physician to the City of London Hospital for Diseases of the Chest, Hackney.

CRUVEILHIER, J. C., M.D., Professor in the Faculty of Medicine, Paris.

HENLE, J., Professor of Anatomy and Physiology in the University of Zurich.

ROKITANSKY, CARL, M.D., Professor of Pathological Anatomy in the University of Vienna.

STOKES, WILLIAM, M.D., M.R.I.A., Regius Professor of Physic in the University of Dublin.

VOGEL, JULIUS, M.D., Professor of Clinical Medicine in the University of Giessen.

Resident and Non-Resident Members.

(C.) Present Members of Council.
† Have paid Life Subscriptions.
* Former Members of Council.
‡ Have paid Composition Fee for Transactions.

GENERAL LIST OF MEMBERS.

Elected Session.

**Orig. Memb.* Adams, William, Esq., Surgeon to the Royal Orthopædic Hospital, 5, Henrietta-street, Cavendish-square.

1847-48 Aikin, Charles A., Esq., 8, Southwick-street, Hyde-park.

1857-58 Alison, S. Scott, M.D., Assistant Physician to the Hospital for Consumption, Brompton, 80, Park-street, Grosvenor-square.

1851-52 Allchin, William Henry, M.B., 7, Pembridge-villas, Westbourne-grove.

1857-58 Anstie, Francis E., M.B., Curator of the Museum at the Westminster Hospital.

1854-55 Armitage, Thomas Rhodes, M.D., Physician to St. Marylebone General Dispensary, 21, Edward-street, Portman-square.

Elected Session.

*Orig. Memb. Arnott, James Moncrieff, Esq., F.R.S., (late President), (V.P.), Surgeon in Ordinary to H.R.H. The Prince Consort, 2, New Burlington-street.

1851-52 Ashton, T. J., Esq., Surgeon to the Blenheim-street Dispensary, 31, Cavendish-square.

1857-58 Avent, Nicholas, Esq., House Surgeon to the St. George's and St. James's Dispensary, 15, Lambeth-terrace.

*Orig. Memb. Babington, Benjamin Guy, M.D., F.R.S. (late President) (V.P.), 31, George-street, Hanover-square.

1854-55 Babington, C. Metcalfe Stuart, F.R.C.P., Physician-Accoucheur to Queen Charlotte's Lying-in-Hospital, 29, Hertford-street, Mayfair.

1856-57 Balding, Daniel Barley, Esq., Resident Medical Officer and Registrar, Middlesex Hospital.

1849-50 Ballard, Thomas, Esq., 10, Southwick-place, Hyde-park.

*1850-51 Baly, William, M.D., F.R.S., (C.) Physician to the Penitentiary, Millbank, and Assistant Physician to St. Bartholomew's Hospital, 45, Queen Anne-street, Cavendish-square.

1851-52 Barclay, A. Whyte, M.D., (C.) Assistant Physician to St. George's Hospital, 23A, Bruton-street, Berkeley-square.

1855-56 Barker, T. A., M.D., Senior Physician to St. Thomas's Hospital, 71, Lower Grosvenor-street.

Orig. Memb. Barker, Thomas Herbert, M.D., Harpur-place, Bedford.

*Orig. Memb. Barlow, George Hilaro, M.D., Physician to Guy's Hospital, 5, Union-street, Southwark.

1852-53 Barwell, Richard, Esq., Assistant Surgeon to the Charing Cross Hospital, 22, Old Burlington-street.

1852-53 Bartlett, William, Esq., Surgeon to the Kensington Dispensary, Ladbroke Lodge, Ladbroke-square, Notting-hill.

1857-58 Basham, William R., M.D., Senior Physician to the Westminster Hospital, 17, Chester-street, Grosvenor-place.

1851-52 Beale, Lionel S., M.D., F.R.S., (C.), Physician to King's College Hospital, 27, Carey-street, Lincoln's-inn.

1855-56 Bealey, Adam, M.D., M.A., 27, Tavistock-square.

1852-53 Beck, Thomas Snow, M.D., F.R.S., 9A, Langham-place.

*1849-50 Beith, Robert, M.D., Surgeon, Royal Naval Hospital, Deal.

1846-47 Bennet, James Henry, M.D., Physician-Accoucheur to the Royal Free Hospital, 60, Grosvenor-street.

*Orig. Memb. Bennett, James Risdon, M.D., (V.P.), Physician to St. Thomas's Hospital, and to the City of London Hospital for Diseases of the Chest, 15, Finsbury-square.

‡1856-57 Bickersteth, Edward, R., Esq., Surgeon to the Liverpool Royal Infirmary, 2 Rodney-street, Liverpool.

*1848-49 Bird, James, M.D., Lecturer on Military Surgery at St. Mary's Hospital, 17, Gloucester-terrace, Hyde-park.

Elected Session.

1855-56 Bird, W., Esq., Surgeon to the St. George's and St. James's, and to the Fulham and Hammersmith General Dispensaries, 11, George-street, Hanover-square.

*1849-50 Birkett, Edmund Lloyd, M.D., Physician to the City of London Hospital for Diseases of the Chest, 48, Russell-square.

**Orig. Memb.* Birkett, John, Esq., Surgeon to Guy's Hospital, 59, Green-street, Grosvenor-square.

1853-54 Black, Cornelius, M.D., Physician to the Chesterfield Dispensary, St. Mary's-gate, Chesterfield.

1849-50 Blagden, Robert, Esq., Stroud, Gloucestershire.

1855-56 Borham, W. H., Esq., 19, Cambridge-terrace, Hyde-park.

*1850-51 Bowman, William, Esq., F.R.S., Surgeon to King's College and to the Royal London Ophthalmic Hospital, 5, Clifford-street.

**Orig. Memb.* Bright, Richard, M.D., F.R.S., (late V.P.), Physician Extraordinary to H.M. the Queen, 11, Savile-row.

*1846-47 Brinton, William, M.D., Senior Physician to the Royal Free Hospital, 20, Brook-street, Grosvenor-square.

1856-57 Briscoe, John, Esq., House Surgeon and Apothecary, Radcliffe Infirmary, Oxford.

*†1850-51 Bristowe, John S., M.D., (C.), Assistant Physician to St. Thomas's Hospital, 3, St. Thomas's-street, Borough.

1851-52 Brodhurst, Bernard E., Esq., Assistant Surgeon to the Royal Orthopædic Hospital, 20, Grosvenor-street.

*1846-47 Brooke, Charles, M.B., F.R.S., Surgeon to Westminster Hospital, 29, Keppell-street, Russell-square.

Orig. Memb. Browne, Joseph Hullett, M.D., Physician to the St. Pancras Royal General Dispensary, 37, Euston-square.

1854-55 Browne, Robert Cave, M.D., Courtney-lodge, Barnet, Herts.

1855-56 Bryant, T., Esq., Assistant Surgeon to Guy's Hospital, 40, Wellington-street, London-bridge.

1854-55 Buchanan, George, M.D., 75, Gower-street, Bedford-square.

1850-51 Bullock, Henry, Esq., 61, Cumberland-street, Bryanston-square.

1852-53 Burton, John M., Esq., Lee-park, Blackheath.

**Orig. Memb.* Busk, George, Esq., F.R.S., (V.P.), Surgeon to the Seamen's Hospital-ship "Dreadnought," 15, Harley-street, Cavendish-square.

*1856-57 Buzzard, Thomas, M.B., 41, Great Marlborough-street.

1856-57 Callender, G. W., Esq., Surgeon to the North London Eye Infirmary, 35, Queen Anne-street, Cavendish-square.

Orig. Memb. Camps, William, M.D., (C.), 40, Park-street, Grosvenor-square.

*1849-50 Canton, Edwin, Esq., Surgeon to the Charing Cross Hospital, 30, Montague-place, Russell-square.

1854-55 Carpenter, Alfred, Esq., M.B., High-street, Croydon.

Elected Session.

1848-49 Carpenter, William Guest, Esq., Amersham, Bucks.

1855-56 Carter, H. V., M.D., Bombay; late of St. George's Hospital.

*1848-49 Chalk, William Oliver, Esq., 3, Nottingham-terrace, Regent's-park.

**Orig. Memb.* Chevers, Norman, M.D., H.E.I.C.S.

1851-52 Childs, George Borlase, Esq., Surgeon to the Metropolitan Free Hospital, and to the City Police Force, 11, Finsbury-place South.

1854-55 Cholmeley, William M.D., Physician to the West London Dispensary, 40, Russell-square.

1851-52 Chowne, William D., M.D., Physician to the Charing Cross Hospital, 8, Connaught-place West, Hyde-park.

1853-54 Clark, Andrew, M.D., Assistant Physician to the London Hospital, 23, Montague-place, Russell-square.

1855-56 Clarke, James F., Esq., Senior Surgeon to the Dorcas Charity, 23, Gerrard-street, Soho.

1849-50 Clarke, John, Esq., L.R.C.P., (C.), Physician-Accoucheur to the British Lying-in-Hospital, 42, Hertford-street, May-fair.

1854-55 Clover, J. Thomas, Esq., 44, Mortimer-street.

**Orig. Memb.* Cock, Edward, Esq., Surgeon to Guy's Hospital, 12, St. Thomas's-street, Borough.

1857-58 Cockerton, Richard, Esq., Surgeon to the Kensington Dispensary, 15, Clarendon Road, Kensington.

1855-56 Cockle, J., M.D., M.A., Physician to the City Dispensary, 63, Brook-street, Hanover-square.

Orig. Memb. Cohen, Daniel Whitaker, M.D., Headley-grove House, near Dorking.

1849-50 Cooper, George F., M.D., Surgeon to the Brentford Dispensary, Brentford.

1850-51 Cooper, William White, Esq., Ophthalmic Surgeon to St. Mary's Hospital, and Surgeon to the North London Eye Infirmary, 19, Berkeley-square.

**Orig. Memb.* Copland, James, M.D., F.R.S., (late V.P., and Treasurer), Consulting Physician to the Royal Infirmary for Children, 5, Old Burlington-street.

1853-54-Cornish, William Robert, Esq., 88, Cambridge-street, Pimlico.

**Orig. Memb.* Coulson, William, Esq., Senior Surgeon to St. Mary's Hospital, 1, Chester-terrace, Regent's-park.

1852-53 Cousins, Edward, Esq., 49. Camden-road-villas.

**Orig. Memb.* Crisp, Edwards, M.D., 21, Parliament-street.

*1848-49 Critchett, George, Esq., (C.), (formerly Honorary Secretary) Senior Assistant Surgeon to the London Hospital, and Surgeon to the Royal London Ophthalmic Hospital, Moorfields, 46, Finsbury-square.

1855-56 Croft, John, Esq., Seamen's Hospital-ship, "Dreadnought."

1853-54 Cross, Robert, M.D., Physician to the Brewer's-court Dispensary, 20, New-street, Spring-gardens.

Elected Session.

1857-58 Cumberbatch, Laurence T. Esq., 12, Cadogan-place, Belgrave-square.

1854-55 Curgenven, J. Brendon, Esq., 11, Craven-hill-gardens, Bayswater.

1854-55 Curling, T. Blizard, Esq., F.R.S., (C.), Surgeon to the London Hospital, 39, Grosvenor-street.

1854-55 Daubeny, Henry, M.D., 40, York-place, Portman-square.

*1846-47 Davis, John Hall, M.D., Physician to the Royal Maternity Charity, and to the St. George's and St. James's Dispensary, 11, Harley-street, Cavendish-square.

**Orig. Memb.* Davies, Herbert, M.D. Physician to the Infirmary for Asthma, &c., and to the London Hospital, 23, Finsbury-square.

**Orig. Memb.* Day, George E., M.D., Chandos Professor of Anatomy in the University of St. Andrews.

1857-58, Delima, Teofilo, M.D., Caracas, South America.

1851-52 Devenish, Samuel Weston, M.B., 7, Billiter-square.

1855-56 Dick, H., M.D., 59, Wimpole-street.

**Orig. Memb.* Dixon, James, Esq., Surgeon to the Royal London Ophthalmic Hospital, Moorfields, 1, Portman-square.

1855-56 Druitt, R., L.R.C.P., Medical Officer of Health for St. George's, Hanover-square, 37, Hertford-street, May-fair.

1851-52 Drury, James Samuel, M.D., 44, Albion-street, Hyde-park.

1846-47 Dudgeon, Robert E., M.D., 82, Gloucester-place, Portman-square.

1851-52 Duff, George, M.D., Prospect-lodge, Elgin.

1848-49 Eden, Thomas E., Esq., Surgeon-Dentist to the Farringdon General Dispensary, 45, Threadneedle-street.

1854-55 Edwards, George N., M.D., Assistant Physician to the City of London Hospital for Diseases of the Chest, 8, Finsbury-pavement.

1846-47 Ellis, Joseph, Esq., Sudbrook-park, Richmond, Surrey.

*1846-47 Erichsen, John, Esq., Surgeon to University College Hospital, 48, Welbeck-street, Cavendish-square.

1853-54 Evans, Conway, M.D., Assistant Physician to King's College Hospital, and Physician to the Public Dispensary, Lincoln's-inn, 30, Brook-street, Grosvenor-square.

*1847-48 Fergusson, William, Esq., F.R.S., (V.P.), Surgeon Extraordinary to H.M. the Queen, Surgeon to King's College Hospital, 16, George-street, Hanover-square.

1851-52 Field, Octavius A., Esq., 20, Sussex-gardens, Hyde-park.

*1846-47 Fincham, George T., M.D., Physician to the Westminster Hospital, 28, Chapel-street, Belgrave-square.

Elected Session.

1853-54 Fisher, W. Webster, M.D., Downing Professor of Medicine, Cambridge.

1855-56 Flower, William H., Esq., Surgeon to the Marylebone General Dispensary, and Assistant Surgeon to the Middlesex Hospital, 15, Queen Anne-street, Cavendish-square.

1851-52 Forbes, J. Gregory, Esq., 9, Devonport-street, Hyde-park.

1849-50 Foreman, Robert Clifton, M.D., Resident Physician to the Asylum for Imbecile Children, Colville-house, Lowestoft.

Orig. Memb. Forster, John Cooper, Esq., (C.), Assistant Surgeon to Guy's Hospital, Surgeon to the Royal Infirmary for Children, 11, Wellington-street, Southwark.

1853-54 Freeman, William Henry, Esq., 21, Spring-gardens.

Orig. Memb. Frere, J. C., Esq., Trinity College, Cambridge.

*1846-47 Fuller, Henry W., M.D., Physician to St. George's Hospital, 13, Manchester-square.

1855-56 Gamgee, Joseph Sampson, Esq., Queen's Hospital, Birmingham.

1855-56 Gamgee, J., Esq., New Veterinary College, Edinburgh.

1850-51 Garrett, Mark Brown, Esq., 3, New-road, St. George's East.

*1846-47 Garrod, Alfred Baring, M.D., F.R.S., Physician to University College Hospital, 84, Harley-street, Cavendish-square.

1855-56 Gaskoin, George, Esq., 3, Westbourne-park, Paddington.

**Orig. Memb.* Gay, John, Esq., Senior Surgeon to the Great Northern Hospital, King's Cross, 10, Finsbury-place South.

1855-56 Gerber, Philip, M.D., 40, Mortimer-street, Cavendish-square.

1854-55 Gibb, George Duncan, M.D., F.G.S., Physician to the West London Dispensary, 14, Queen's-square, Bloomsbury.

1853-54 Gibbon, Septimus, M.D., Assistant Physician to the London Hospital, 11, Finsbury-place.

1857-58 Godfrey, Benjamin, M.D., Carlton-house, Enfield.

1854-55 Goodfellow, Stephen Jennings, M.D., Physician to the Middlesex Hospital, 4, Russell-square.

1856-57 Goolden, R. H., M.D., Physician to St. Thomas's Hospital, 41, Sussex Gardens, Hyde-park.

1857-58 Gowlland, Peter Y., Esq., Demonstrator of Anatomy at the London Hospital, 34, Finsbury-square.

*1848-49 Gray, Henry, Esq., F.R.S., Surgeon to St. George's and St. James's Dispensary, 8, Wilton-street, Grosvenor-place.

1846-47 Gream, George T., M.D, 2, Upper-Brook-st, Grosvenor-square.

1856-57 Greenhalgh, Robert, M.D., Consulting Physician-Accoucheur to St. John's Wood Dispensary, 11, Upper Woburn-place.

‡1854-55 Greenhill, William Alexander, M.D., Physician to the Hastings Infirmary, Carlisle-parade, Hastings.

*1849-50 Habershon, Samuel O., M.D., Assistant Physician to Guy's Hospital, 22, Wimpole-street, Cavendish-square.

Elected Session.

1851-52 Hacon, E. Dennis, Esq., Mare-street, Hackney.

†1851-52 Halley, Alexander, M.D., 7, Harley-street, Cavendish-square.

1856-57 Hancock, Henry, Esq., Surgeon to the Charing-cross Hospital, 37, Harley-street.

1851-52 Hansard, Richard James, Esq., Surgeon to the Radcliffe Infirmary, 5, Broad-street, Oxford.

*1847-48 Hare, Charles John, M.D., Assistant Physician to University College Hospital, 41, Brook-street, Grosvenor-square.

1855-56 Harley, George, M.D., Lecturer on Practical Physiology and Histology in University College, London, 40, Somerset-street, Portman-square.

1857-58 Hart, Ernest, Esq., Junior Surgeon to the North London Ophthalmic Infirmary, 9, Upper Berkeley-street, West.

**Orig. Memb.* Hawkins, Cæsar, H., Esq., F.R.S., (late President), Senior Surgeon to St. George's Hospital, 26, Grosvenor-street.

1851-52 Hawkins, Charles, Esq., Consulting Surgeon to Queen Charlotte's Hospital, and Inspector of Anatomy, 22, Savile-row.

1856-57 Hawksley, Thos., M.D., Physician to the Margaret-street Dispensary for Consumption, 26, George-street, Hanover-square.

1856-57 Heath, Christopher, Esq., Demonstrator of Anatomy at the Westminster Hospital, 28, Gordon-square.

1857-58 Hedger, Alfred, M.D., Resident Medical Officer, Colney-hatch, Asylum.

*1848-49 Henry, Mitchell, Esq., (Honorary Secretary), Surgeon to the Middlesex Hospital, and to the North London Eye Infirmary, 5, Harley-street, Cavendish-square.

**Orig. Memb.* Hewett, Prescott G., Esq., Assistant Surgeon to St. George's Hospital, 1, Chesterfield-street, May-fair.

1854-55 Hewitt, W. M. Graily, M.D., Physician to the Samaritan Free Hospital for Women and Children, and Lecturer and Registrar of St. Mary's Hospital, 17, Radnor-place, Hyde-park.

1854-55 Hillier, Thomas, M.D., Medical Officer of Health for St. Pancras, 21, Gower-street, Bedford-square.

Orig. Memb. Hillman, William Augustus, Esq., (C.), Senior Assistant Surgeon to the Westminster Hospital, 1, Argyll-street, Regent-street.

**Orig. Memb.* Hilton, John, Esq., F.R.S., Surgeon to Guy's Hospital, 10, New Broad-street, City.

1855-56 Hinton, J., Esq., 37, Charterhouse-square.

*1850-51 Hodgson, Joseph, Esq., F.R.S., 60, Westbourne-terrace.

1852-53 Hogg, Jabez, Esq., Assistant Surgeon to the Westminster Ophthalmic Hospital, 6, Gower Street.

1846-47 Holman, H. Martin, M.D., Hurstpierpoint, Sussex.

1854-55 Holmes, Timothy, Esq., Curator of the Pathological Museum of St. George's Hospital, and Surgeon to the North London Eye Infirmary, 39, Curzon-street.

Elected Session.

*1849-50 Holt, Barnard Wight, Esq., Senior Surgeon to the Westminster Hospital, 5, Parliament-street.

1853-54 Hood, William Charles, M.D., Resident Physician, Bethlem Hospital.

1850-51 Hore, Henry A., Esq., Surgeon to the Bristol Royal Infirmary.

1857-58 Hornidge, Thomas King, Esq., 15, Charles-street, Westbourne-Terrace.

1855-56 Hudson, John, M.D., 11, Cork-street.

1854-55 Hulke, John Whitaker, Esq, Assistant Surgeon to King's College Hospital, King's College.

1854-55 Hulme, Edward Charles, Esq., Assistant Surgeon to the Central London Ophthalmic Hospital, and Surgeon to Blenheim-street Dispensary, 19, Gower-street, Bedford-square.

1852-53 Humby, Edwin, Esq., 1, Windsor-terrace, Maida-hill.

1852-53 Hutchinson, Jonathan, Esq., (C.), Surgeon to the Metropolitan Free Hospital, 14, Finsbury-circus.

‡1856-57 Jackson, Henry, Esq., Senior Surgeon to the Sheffield Infirmary, St. James's-row, Sheffield.

‡1853-54 Jardine, J. L., Esq., Brixton-hill, Surrey.

1846-47 Jay, Edward, Esq., 51, Park-street, Grosvenor-square.

**Orig. Memb.* Jeaffreson, Henry, M.D., Physician to St. Bartholomew's Hospital, and Consulting Physician to the City of London Hospital for Diseases of the Chest, 2, Finsbury-square.

**Orig. Memb.* Jenner, William, M.D., Physician to the Hospital for Sick Children, and to University College Hospital, 8, Harley-street.

1854-55 Johnson, Athol A. W., Esq., Surgeon to the Hospital for Sick Children, 37, Albemarle-street.

1854-55 Johnson, Edward, M.D., 211A, Regent-street.

**Orig. Memb.* Johnson, George, M.D., Physician to King's College Hospital, 3, Woburn-square.

*1846-47 Johnson, Henry Charles, Esq., Surgeon to St. George's Hospital, 6, Savile-row.

1856-57 Johnstone, Joseph S., M.D., 59, Inverness-terrace, Bayswater.

*†*Orig. Memb.* Jones, Henry Bence, M.D., F.R,S., Physician to St. George's Hospital, 31, Brook-street, Grosvenor-square.

1853-54 Jones, Sydney, M.B., Demonstrator of Morbid Anatomy at St. Thomas's Hospital, 4, St. Thomas's-street.

1856-57 Jones, George Matthew, Esq., Surgeon to the General Hospital, Old-street, St. Heliers, Jersey.

1846-47 Kent, Thomas J., Esq., 30, Queen Anne-street, Cavendish-square.

1852-53 Kershaw, W. Wayland, M.D., Kingston-on-Thames.

1851-52 Kingdon, J. Abernethy, Esq., Surgeon to the City Dispensary, and to the City Truss Society, 2, New Bank-buildings.

Elected Session.

1856-57 Kingsley, Henry, M.D., Physician to the Stratford Infirmary, Stratford-on-Avon.

1854-55 Kirby, Edmund A., Esq., 32, Euston-square.

1854-55 Kirkes, William Senhouse, M.D., Assistant Physician to St Bartholomew's Hospital, 2, Lower Seymour-street.

1850-51 Langmore, John C., M.B., (C.), 20, Oxford-terrace, Hyde-park.

1857-58 Lankester, Edwin, M.D., F.R.S., Medical Officer of Health for St. James's, Westminster, 8, Savile-row.

*1849-50 Latham, Peter Mere, M.D., (late President), Physician Extraordinary to H.M. the Queen, 36, Grosvenor-street.

1856-57 Laurence, John Z., Esq., Surgeon to the Northern Dispensary, 30, Devonshire-street, Portland-place.

1853-54 Lawrence, Henry John Hughes, Esq., Assistant Surgeon, Coldstream Guards.

1857-58 Leared, Arthur, M.B., Physician to the Royal Infirmary for Diseases of the Chest, 48, Finsbury-square.

1851-52 Lee, Henry, Esq., Surgeon to King's College and the Lock Hospitals, 9, Savile-row.

1852-53 Leggatt, Alfred, Esq., 13, William-street, Lowndes-square.

*1849-50 Liddell, Sir John, C.B., M.D., F.R.S., Director-General of the Medical Department of the Navy, Somerset House.

*1848-49 Little, William John, M.D., (V.P.), Physician to the London Hospital, 34, Brook-street, Grosvenor-square.

**Orig. Memb.* Lloyd, Edward, M.D., Physician to the Royal General Dispensary, 4, Suffolk-place, Pall-mall.

1852-53 Lloyd, Eusebius A., Esq., Surgeon to St. Bartholomew's and Christ's Hospitals, 14, Bedford-row.

1855-56 Macann, Arthur B., Esq., 22, King-street, Portman-square.

1851-52 Mackenzie, Frederick William, M.D., Physician to the Western General Dispensary, 11, Chester-place, Hyde-park-square.

1853-54 Macmurdo, Gilbert, Esq., F.R.S., Surgeon to St. Thomas's Hospital, 7, New Broad-street, City.

1857-58 Marcet, William, M.D., Assistant Physician to the Westminster Hospital, 36, Chapel-street, Belgrave-square.

1851-52 Markham, William O., M.D., Physician to St. Mary's Hospital, 33, Clarges-street, Piccadilly.

1846-47 Marshall, John, Esq., F.R.S., Assistant Surgeon to University College Hospital, 10, Savile-row.

1856-57 Martin, Robert, M.D., Assistant Physician to St. Bartholomew's Hospital, Warden's Residence, St. Bartholomew's Hospital.

1852-53 Martyn, S., M.D., Senior Physician to the Bristol General Hospital, 26, Park-street, Bristol.

Elected Session.

‡1851-52 May, George, M.B., Surgeon to the Royal Berkshire Hospital, Reading.

1857-58 Meller, Charles James, Esq., 31, Aberdeen-place, Maida-hill.

1854-55 Miles, Charles, Esq., 13, Conduit-street West, Hyde-park.

1846-47 Morgan, John, Esq., (C.), 3, Sussex-place, Hyde-park-gardens.

1852-53 Moseley, George, Esq., late of Sandgate.

1854-55 Murchison, Charles, M.D., Assistant Physician to King's College and to the London Fever Hospitals, 31, Sackville-street.

1856-57 Nunn, Thomas William, Esq., Assistant Surgeon to the Middlesex Hospital, 8, Stratford-place, Oxford-street.

*1850-51 Obré, Henry, Esq., Surgeon to the St. Marylebone Eye and Ear Institution, 1, Melcombe-place, Dorset-square.

1852-53 O'Connor, William, M.D., Physician to the Royal Free Hospital, 30, Upper Montagu-street, Montagu-square.

*1850-51 Ogle, John W., M.D., (Hon. Secretary), Assistant Physician to St. George's Hospital, 13, Upper Brook-street, Grosvenor-square.

1853-54 Ogle, William, L.R.C.P., Physician to the Royal Pimlico Dispensary, 9, Lower Belgrave-street, Eaton-square.

‡1855-56 Oldfield, Edmund, Esq., Boscomb Lodge, Finchley-road.

1857-58 Ord, William Miller, M.B., Registrar and Demonstrator of Anatomy at St. Thomas's Hospital, Brixton-hill.

1854-55 Panton, P., M.D., 1, Pembridge-place, Bayswater.

1853-54 Parkinson, George, Esq., 11, Grosvenor-street.

1853-54 Part, James, Esq., 7, Camden-road-villas, Camden-town.

**Orig. Memb.* Partridge, Richard, Esq., F.R.S., (late V.P.), Surgeon to King's College Hospital, 17, New-street, Spring-gardens.

**Orig. Memb.* Peacock, Thomas Bevill, M.D., (C.), (late V.P. and Hon. Secretary), Assistant Physician to St. Thomas's Hospital, and Physician to the City of London Hospital for Diseases of the Chest, 20, Finsbury-circus.

**Orig. Memb.* Poland, Alfred, Esq., Assistant Surgeon to Guy's, and Surgeon to the Royal London Ophthalmic Hospitals, 10, Bolton-row, Curzon-street, May-fair.

*1846-47 Pollock, George D., Esq., (late Honorary Secretary), Assistan, Surgeon to St. George's Hospital, 27, Grosvenor-street.

1850-51 Pollock, James Edward, M.D., Assistant Physician to the Hospital for Consumption and Diseases of the Chest, Brompton, 52, Upper Brook-street.

1854-55 Potts, William, Esq., 12, North Audley-street.

1856-57 Price, Peter Charles, Esq., Assistant Surgeon to the Great Northern Hospital, King's Cross, 7, Green-street, Grosvenor-square.

Elected Session.

1856-57 Priestley, William Overend, M.D., Physician-Accoucheur to the St. Marylebone Infirmary and the St. George's and St. James's Dispensary, 31, Somerset-street, Portman-square.

†1848-49 Purnell, John James, Esq., Surgeon to the Royal General Dispensary, Woodlands, Streatham-hill.

1850-51 Pyle, John, Esq., 56, Oxford-terrace, Hyde-park.

**Orig. Memb.* Quain, Richard, M.D., (Treasurer, late Hon. Secretary), Physician to the Hospital for Consumption and Diseases of the Chest Brompton, 23, Harley-street, Cavendish-square.

1855-56 Rae, J., Esq., Surgeon, R.N., Haslar Hospital.

**Orig. Memb.* Ramsbotham, Francis H., M.D., (late V.P.), Physician-Accoucheur to the London Hospital, 7, Portman-square.

1856-57 Ramskill, J. Spence, M.D., Senior Physician to the Metropolitan Free Hospital, 5, St. Helen's-place, Bishopsgate-street.

1847-48 Randall, John, M.D., Medical Officer, St. Marylebone Infirmary, 14, Portman-street, Portman-square.

1856-57 Ranke, Henry, M.D.

1846-47 Ray, Edward, Esq., Dulwich.

1854-55 Reynolds, J. Russell, M.D., Assistant Physician to the Westminster Hospital, 38, Grosvenor-street.

1856-57 Richardson, Benjamin Ward, M.D., Physician to the Infirmary for Asthma, 12, Hinde-street, Manchester-square.

**Orig. Memb.* Ridge, Joseph, M.D., 39, Dorset-square.

**Orig Memb.* Roe, George Hamilton, M.D., Physician to the Hospital for Consumption and Diseases of the Chest, Brompton, 57, Park-street, Grosvenor-square.

1855-56 Roberts, John Henry, Esq., 16, Finchley-road, St. John's-Wood.

1856-57 Robinson, Thomas, Esq., 50, Southampton-street, Pentonville.

1851-52 Rooke, H. T., M.D., Wisbeach, Cambridgeshire.

1852-53 Salter, Henry Hyde, M.D., F.R.S., Assistant Physician to the Charing-cross Hospital, 6, Montague-street, Russell-square.

1853-54 Salter, Samuel James A., M.B., Surgeon-Dentist to Guy's Hospital, 17, New Broad-street.

1852-53 Sanderson, Hugh James, M.D., 26, Upper Berkeley-street.

1854-55 Sanderson, John Burdon, M.D., Medical Officer of Health for Paddington, 9, Gloucester-place, Hyde-park.

*1846-47 Sankey, William H. O., M.D., Middlesex County Lunatic Asylum, Hanwell.

1857-58 Schulhof, Maurice, M.D., Physician to the Royal General Dispensary, Bartholomew-close, 14, Brook-street.

**Orig. Memb.* Scott, John, M.D., Physician to the H.E.I.C., 13, Stratton-street, Piccadilly.

Elected Session.

1853-54 Scott, John, Esq., Surgeon to the Hospital for Women, Soho-square, 65, Harley-street, Cavendish-square.

1846-47 Seaton, Edward C., M.D., Surgeon to the Chelsea, Brompton, and Belgrave Dispensary, 33, Sloane-street, Knightsbridge.

1856-57 Sedgwick, William, Esq., Surgeon to the St. Marylebone Provident Dispensary, 12, Park-place, Upper Baker-street.

1852-53 Semple, Robert Hunter, M.D., Physician to the Northern Dispensary, 8, Torrington-square.

**Orig. Memb.* Shaw, Alexander, Esq., (C.), (late Treasurer), Surgeon to the Middlesex Hospital, 25, Henrietta-street, Cavendish-square.

1856-57 Shillito, Buxton, Esq., 34, Finsbury-circus.

1855-56 Sibley, Septimus W., Esq., Medical Registrar to the Middlesex Hospital, 14, New Burlington-street.

*1848-49 Sibson, Francis, M.D., F.R.S., Physician to St. Mary's Hospital, 40, Brook-street, Grosvenor-square.

*1847-48 Sieveking, Edward H., M.D., Physician to St. Mary's Hospital, 17, Manchester-square.

1850-51 Simonds, James B., Esq., Professor, Royal Veterinary College.

**Orig. Memb.* Simon, John, Esq., F.R.S., (V.P.), Surgeon to St. Thomas's Hospital, 44, Cumberland-street, Bryanston-square.

1857-58 Siordet, James Lewis, M.D., Physician to the Blenheim Dispensary, 6, Holles-street, Cavendish Square.

**Orig. Memb.* Smith, Ebenezer Pye, Esq., 7, Billiter-square.

1854-55 Smith, Edward, M.D., Assistant Physician to the Hospital for Consumption and Diseases of the Chest, Brompton, 63, Grosvenor-st.

1846-47 Smith, Protheroe, M.D., Physician to the Hospital for Women, 25, Park-street, Grosvenor-square.

1851-52 Smith, W. Tyler, M.D., Physician-Accoucheur to St. Mary's Hospital, 7, Upper Grosvenor-street.

1855-56 Smith, Spencer, Esq., Surgeon to St. Mary's Hospital, 48, Sussex-gardens, Hyde-park.

1856-57 Smith, Thomas, Esq., St. Bartholomew's Hospital.

1854-55 Squire, William, Esq., 6, Orchard-street, Portman-square.

*1847-48 Solly, Samuel, Esq., F.R.S., Surgeon to St. Thomas's Hospital, 18, St. Helen's-place, Bishopsgate-street.

1857-58 Stallard, Joshua Harrison, L.R.C.P., Physician to the Great Northern Hospital, 12, Welbeck-street, Cavendish-square.

*1850-51 Stanley, Edward, Esq., F.R.S., Surgeon to St. Bartholomew's Hospital, 23A, Brook-street, Grosvenor-square.

1856-57 Stephens, Nicholas Henry, Esq., Surgeon, Islington Dispensary, 14, Finsbury-circus.

1854-55 Stewart, William Edward, Esq., Surgeon to St. Marylebone Provident Dispensary, 8, Weymouth-street, Portland-place.

†1853-54 Streatfeild, J. F., Esq., Assistant Surgeon to the Royal London Ophthalmic Hospital, Moorfields, 15, Upper Brook-street.

Elected Session.

†1850-51 Sutherland, Alexander John, M.D., F.R.S., Senior Physician to St. Luke's Hospital, 6, Richmond-terrace, Whitehall.

‡1856-57 Symonds, Frederick, Esq., Surgeon to the Radcliffe Infirmary, 32, Beaumont-street, Oxford.

Orig. Memb. Tamplin, R. W., Esq., Surgeon to the Royal Orthopædic Hospital, 33, Old Burlington-street.

‡1855-56 Tapp, W. Denning, Esq., Senior Surgeon to the Dorset County Hospital, Dorchester.

1850-51 Tatum, Thomas, Esq., Surgeon to St. George's Hospital, 3, George-street, Hanover-square.

1851-52 Taylor, Robert, Esq., Surgeon to the Central London Ophthalmic Hospital, 10, George-street, Hanover-square.

1848-49 Tebay, Thomas G., Esq., 6, Great Smith-street, Westminster.

1852-53 Thompson, Henry, Esq., Surgeon to the St. Marylebone Infirmary, and Assistant Surgeon to the University College Hospital, 16, Wimpole-street, Cavendish-square.

1851-52 Thompson, Theophilus, M.D., F.R.S., (C.), Physician to the Hospital for Consumption and Diseases of the Chest, Brompton, 3, Bedford-square.

1851-52 Todd, Robert Bentley, M.D., F.R.S., Physician to King's College Hospital, 26, Brook-street, Grosvenor-square.

1856-57 Tomes, J., Esq., F.R.S., Surgeon-Dentist to the Middlesex Hospital, 37, Cavendish-square.

**Orig. Memb.* Toynbee, Joseph, Esq., F.R.S., Aural Surgeon to St. Mary's Hospital, 18, Savile Row.

1851-52 Trotter, John William, Esq., Assistant Surgeon, Coldstream Guards.

1857-58 Tudor, John, Esq, Surgeon to the Seaman's Hospital Ship "Dreadnought."

1847-48 Tuke, T. Harrington, M.D., (C.), Manor-house, Chiswick.

1852-53 Tulloch, James S., M.D., 33, Pembridge-villas, Bayswater.

1857-58 Turtle, Frederick, Esq., Resident Surgeon to the St. Marylebone Infirmary.

1856-57 Tyrrell, Walter, Esq., Surgeon to the National Truss Society, 1, St. Helen's-place, Bishopsgate-street.

1853-54 Van der Byl, Philip, M.D., 1, Oxford-square, Hyde-park.

1854-55 Vasey, Charles, Esq., Surgeon-Dentist to St. George's Hospital, 5, New Bond-street.

1856-57 Valpy, William H., Esq., 9, Bedford-street, Bedford-square.

1856-57 Vernon, Henry Hannotte, M.D., Physician to the Great Northern Hospital, King's Cross, 14, Harewood-square, Dorset-square.

Elected Session.

1850-51 Wagstaff, W. R., M.D., Thornton House, Thornton-road, Clapham-park.

Orig. Memb. Waite, Charles D., M.D., Senior Physician to the Westminster General Dispensary, 3, Old Burlington-street.

1851-52 Walker, John Butterworth, Esq., 8, Hamilton-place, St. John's-wood-road.

**Orig. Memb.* Walton, Henry Haynes, Esq., Surgeon to the Central London Ophthalmic Hospital, and Surgeon to St. Mary's Hospital, 69, Brook-street, Hanover-square.

‡*Orig. Memb.* Ward, Joseph, Esq., Epsom, Surrey.

**Orig. Memb.* Ward, Nathaniel, Esq., (formerly Honorary Secretary), Assistant Surgeon to the London Hospital, 1, Broad-street-buildings.

*1846-47 Ward, T. Ogier, M.D., 9, Leonard-place, Kensington.

1857-58 Wardell, John Richard, M.D., St. John's Lodge, Regent's Park.

**Orig. Memb.* Ware, James T., Esq., Surgeon to the Finsbury Dispensary, 51, Russell-square.

1855-56 Watson, Thomas, M.D, (President), Consulting Physician to King's College Hospital, 16, Henrietta-street, Cavendish-square.

1854-55 Webb, Francis Cornelius, M.D., 39, Great Coram-street.

1857-58 Weber, Hermann, M.D., Physician to the German Hospital, 49, Finsbury-square.

1851-52 Welch, Henry James W., Esq., 1, Dalston-terrace.

1853-54 Wells, Thomas Spencer, Esq., Surgeon to the Samaritan Free Hospital for Women and Children, 3, Upper Grosvenor-street.

*1850-51 West, Charles, M.D., Physician-Accoucheur to St. Bartholomew's Hospital, and Physician to the Hospital for Sick Children, 96, Wimpole-street, Cavendish-square.

1856-57 Wilkin, Herbert C., Esq., 39, Connaught-terrace, Hyde-park.

1854-55 Wilks, Samuel, M.D., (C.) Assistant Physician and Demonstrator of Morbid Anatomy at Guy's Hospital, 17, St. Thomas's-street, Southwark.

**Orig. Memb.* Williams, C. J. B., M.D., F.R.S., (formerly President), (V.P.), Consulting Physician to the Hospital for Consumption and Diseases of the Chest, Brompton, 49, Upper Brook-street, Grosvenor-square.

1850-51 Wood, John, Esq., (C.) Assistant Surgeon to King's College Hospital, 4, Montague-street, Russell-square.

1854-55 Wood, Barnes, M.D., 18, Gloucester-place, Hyde-park.

1854-55 Wood, William, M.D., 54, Upper Harley-street.

1853-54 Wordsworth, John C., Esq., Assistant Surgeon to the London and to the Royal London Ophthalmic Hospitals, 41, Finsbury-square.

1852-53 Wright, Edward John, Esq., 13, Montague-place, Clapham-road.

LIST OF SPECIMENS

EXHIBITED AT THE MEETINGS OF THE SOCIETY DURING THE SESSION, 1857-8.

DISEASES, ETC., OF THE NERVOUS SYSTEM.

		Page
1. Case of Encephalocele, presenting at the root of the Nose.	Mr. SHAW	1
2. Cancerous Growths connected with the Membranes of the Brain, and producing Hydrocephalus.	Dr. BRISTOWE	2
3. Effusion of Blood into the Pons Varolii.	Dr. BRISTOWE	7
4. General Paralysis; Softening of the Spinal Cord; Inflammation of the Cerebral Membranes.	Mr. OBRÉ for Dr. BOYD	8
5. Softening of the Spinal Cord; General Paralysis, combined with Mania.	Mr. OBRÉ for Dr. BOYD	10
Report on the above.	Dr. G. JOHNSON and Dr. ANDREW CLARK	11
6. Epithelial Tumour in the Sheath of the Sciatic Nerve.	Mr. W. H. FLOWER	11
7. Pedunculated Villous Growth of a peculiar character, from the Visceral layer of the Arachnöid Membrane covering the upper part of one of the Cerebral Hemispheres.	Dr. JOHN W. OGLE	14

c

		Page
8. Apoplectic Clots.	Dr. T. A. Barker	18
9. Carcinoma of the Brain, as also of other parts; Hemiplegia; Paralysis of Motion and Sensibility; *Increased Temperature of paralyzed parts.*	Dr. John W. Ogle	20
10. Softening, without Discoloration, of the Spinal Cord, from the Pressure of Strumous Matter; Softening of the central parts of the Brain, and Scrofulous Meningitis.	Dr. John W. Ogle.	25

DISEASES, ETC., OF THE ORGANS OF RESPIRATION.

1. Hydatids expectorated from the Left Lung.	Dr. Hare	28
2. Case of Intra-thoracic Cancer, which affected the Lungs and Heart, and projected out of the Chest through an opening in the Sternum.	Mr. T. Holmes	29
3. Fibro-cellular Growth of the Lung.	Dr. Wilks	31
4. Oil from the Cavity of the Pleura.	Dr. Barclay for Mr. Hatfield	32

		Page
5. Ulcer of the Larynx in Typhöid Fever, producing General Emphysema.	Dr. Wilks	34
6. Epithelial Growth from the Larynx.	Dr. Pollock	36
7. Tuberculous Abscess of the Anterior Mediastinal Glands, bursting into the Trachea.	Mr. Thomas Ballard.	38
8. Epithelial Cancer of the Larynx, with Extension of the Disease to the Œsophagus, for which Tracheotomy was performed, twelve months before death.	Mr. T. B. Curling	39
Report on the above.	Dr. Andrew Clark	42
9. Gangrenous Cavity behind the Root of the Lung, opening into the Left Bronchus and Œsophagus.	Dr. Bristowe	46
10. Remains of a Pleural Abscess.	Dr. Markham	51
11. Tubular Cast of the Trachea, at its Bifurcation.	Mr. Hutchinson for Mr. B. Roberts	52
12. Fibrinous Casts of the Bronchial Tubes Expectorated.	Dr. Peacock	53
13. Villous Growth from the Vocal Cords, causing Death by Asphyxia.	Mr. Henry Thompson	55

		Page
14. Specimens of Disease of the Lung, Larynx, and Liver, supposed to be Syphilitic.	Dr. WILKS	55

DISEASES, MALFORMATIONS, ETC., OF THE ORGANS OF CIRCULATION.

		Page
1. Persistent Ductus Arteriosus, etc.	Dr. GRAILY HEWITT	58
2. The Left Common Iliac, the Left External Iliac, and part of the Femoral Veins, with part of the Lower Vena Cava, from a case of Phlegmasia Dolens.	Dr. GRAILY HEWITT	59
3. Obstructive and Regurgitant Disease of the Aortic Valves, probably dependent on Congenital Malformation.	Dr. PEACOCK	61
4. Blocking of the Cerebral Arteries.	Dr. PEACOCK and Dr. BRISTOWE	65
5. Diseased Mitral Valve—Extreme consequent Hypertrophy of the Right Ventricle.	Dr. BRISTOWE	67
6. Dilatation of the Basilar Artery fatal by Rupture and Hæmorrhage.	Dr. BRISTOWE	69
7. Congenital Deficiency of the Sternum, rendering visible the Movements of the Heart.	Dr. C. J. B. WILLIAMS	71
8. Diseased Mitral and Aortic Valves.	Dr. BRINTON	74

		Page
9. Aneurysm of the Arch of the Aorta, fatal by Rupture into an Ulceration of the Trachea. Occlusion of the Sub-clavian Artery.	Mr. W. Squire . . .	74
10. Obstruction of the Cerebral Arteries by Fibrinous Plugs, in connection with Deposits on the Aortic and Mitral Valves.	Dr. Van der Byl . .	76
11. Ulceration of the Aortic Valves, with Aneurysm at their Bases. Old-standing Coagulum in the Left Auricle.	Mr. Shillitoe . . .	79
12. Aneurysm of the Arch of the Descending Aorta.	Mr. T. Smith for Mr. C. Mayo . . .	83
13. Rupture of the Abdominal Aorta in a Child.	Dr. Armitage . . .	85
14. Contraction of the Mitral Orifice, with extensive fibrinous deposits in both Kidneys.	Dr. Armitage . . .	87
15. Cancerous Nodules in the Substance of the Heart.	Dr. Wilks	87
16. Abscess in the Pericardium.	Mr. Obré for Dr. Boyd .	88
Report on this Specimen.	Mr. J. Hutchinson . .	89
17. Case of Sudden Death from Contraction of the Mitral Orifice, and its Obstruction, produced by a Globular Vegetation detached from the Left Auricle.	Dr. Van der Byl . .	89

		Page
18. Perforation of the Septum Ventriculorum; Clots in some of the Pulmonary Arteries, undergoing various changes.	Mr. G. W. CALLENDER	91
19. Injected preparation of the Iliac Arteries from a Male Subject which presented an Example of Talipes Equinus on the Left Side.	Mr. T. W. NUNN	95
20. Aneurysm of the Innominate Artery, opening into the Trachea, with Obstruction of both Sub-clavian Arteries.	Mr. CHRISTOPHER HEATH	95
21. Aneurysm of the Ascending and Transverse Aorta. Death in about three years from Asthenia, the Sac being unruptured. Supervention of Gangrene of the Nose, three days prior to Death.	Dr. COCKLE	97
22. A large, tough, fibrinous Clot, from the Right Ventricle of the Heart.	Dr. FULLER	99
23. Ossific Deposit at the Left Auriculo-ventricular Orifice; Concentric Hypertrophy; Cyst of Kidney, and contracted Pylorus	Dr. S. SCOTT ALISON	102
24. Aneurysm of the Transverse Arch of the Aorta, fatal by Rupture into the Pericardium.	Dr. BRISTOWE	105

25.
Heart, shewing a large patch of striated Muscular Fibre, situated in the Substance of the Anterior Segment of the Mitral Valve; also the Substitution of Muscular Cords for two of the ordinary Tendinous ones. — Dr. JOHN W. OGLE . . 109

26.
Pouch or Cavity formed, apparently, by Fibrinous Coagulum, connected with a perforation of the anterior segment of the Mitral Valve, which was, most probably, the result of Ulceration. — Dr. JOHN W. OGLE . . 117

27.
Case of Ruptured Aneurysm of the Popliteal Artery. — Mr. J. WOOD . . . 122

28.
Simple Hypertrophy of the Heart without Dilatation or Valvular Disease. — Dr. MARKHAM . . . 124

29.
Bruise within the Heart. — Dr. MARKHAM . . . 125

30.
Aneurysm of the right Profunda Femoris Artery; Ligature of the external Iliac. — Mr. THOMAS BRYANT . . 125

		Page
31. Endocarditis on the Right Side of the Heart, caused by small Cancerous Tumours beneath the Endocardium, in connection with extensive Adhesive Phlebitis.	Mr. Septimus W. Sibley	128
32. Ulceration, of the Anterior Curtain of the Mitral Valve, partly of the Anterior and left portion of the Wall of the Left Auricle. Appearance of an Aneurysmal Pouch, produced by adhesion of Fibrin to the Margins of the Ulcerated Opening.	Dr. John W. Ogle	131
33. Heart in which Frothy Blood was found.	Mr. G. May, Jun.	154
34. Spontaneous Laceration of the Femoral Artery.	Mr. Alfred Leggatt	159
35. Affection of the Heart, with Enlargement of the Thyröid and Thymus Glands, and prominence of the Eyes.	Dr. Markham	163
36. Secondary Abscess from Pyæmia within the Walls of the Heart.	Mr. T. Holmes	164
37. Cyst beneath the Pericardium covering the posterior surface of the Right Ventricle, and filled with laminated blood-coagulum. —Calcareous matter in pericardial adhesions.	Dr. John W. Ogle	165

		Page
38. A specimen shewing a large spontaneously healed Aneurysm of the Innominate Artery.	Dr. John W. Ogle	167
39. Spontaneous Cure of Aneurysm of the root of the Cœliac Axis.	Mr. T. Holmes	172
40. Specimens of Hypertrophy of the Heart, with remarks on seventy cases.	Dr. Van der Byl	173
41. Aneurysmal Dilatation of the Arch of the Aorta; chiefly within the Pericardium.	Dr. Hare	180
42. Aneurysm of the Aorta, fatal by bursting into the Œsophagus.	Mr. Part	182
43. Case of Aortic Valvular Disease, with Obstruction caused by a Band of Membrane extending across the Outlet from the Ventricle.	Dr. Peacock	184
44. Extensive Nævus, involving the whole of the Right Leg, in different stages of Development.	Mr. Thomas Bryant	186

DISEASES, ETC., OF THE DIGESTIVE ORGANS.

PHARYNX, ŒSOPHAGUS, STOMACH AND INTESTINES.

1. Tubular Exudation Casts of the Intestine.	Mr. HUTCHINSON	188
Report on the above.	Dr. WILKS and Dr. ANDREW CLARK	189
Supplementary Notes.	Dr. ANDREW CLARK	192
2. Epithelial Cancer of the Œsophagus, causing Death by Hæmorrhage from the Right Sub-clavian Artery.	Mr. B. BALDING	194
Report on the above.	Dr. WILKS and Dr. BRINTON	195
Second Report on the above.	Dr. GOODFELLOW and Mr. SIBLEY	197
3. Perforating Ulcer of the Duodenum.	Dr. MURCHISON	197
4. Perforating Ulcer of the large Intestine, in Typhöid Fever.	Dr. W. BRINTON	199
5. Cancerous Infiltration of a Chronic Gastric Ulcer.	Dr. W. BRINTON	200
6. Epithelial Cancer of the Œsophagus, causing Death by Opening an Intercostal Artery.	Dr. SYDNEY JONES	202
7. Gangrene and Perforation of the Ileum, with Peritonitis, caused by a large Biliary Calculus.	Dr. SCOTT ALISON	203

		Page
8. Malformation of the Rectum.	Dr. Beale for Dr. Elin	205
9. A Fibrinous Cast of the Pharynx, ejected by a Patient suffering from Diphtherite.	Dr. Fuller	206
10. Collöid Cancer of the Peritoneum, involving the Great Omentum, the Ovaries and the surface of the Liver and Gall-bladder.	Dr. Van der Byl	207
11. Intestine, presenting old and recent disease, from a patient who died of Typhöid Fever during relapse.	Dr. Peacock	209
12. Cancer of the Stomach and Œsophagus.	Mr. Christopher Heath	211
13. Cancer of the Liver and Cardiac Extremity of the Stomach, with perforation.	Mr. Christopher Heath	212
14. Pedunculated Polypus from the Rectum.	Mr. T. Holmes	212
15. Rupture of the Colon produced by distention of the Gases within it. Malignant Disease of the Sigmöid Flexure of the Colon.	Dr. Markham	213
16. Scirrhous Cancer of the Omentum, involving the Coats of the Colon at the Junction of the Ascending and Transverse portions; Intestinal Obstruction relieved by Amussat's Operation.	Dr. Septimus Gibbon	214
17. Cases of Diphtherite.	Dr. T. Ogier Ward	217

LIVER AND ITS APPENDAGES.

		Page
18. Cases illustrating the causes and effects of Obstruction of the Hepatic Ducts.	Dr. Bristowe	218
Case 1. Obstruction of one of the Hepatic Ducts by a Tumour developed in its walls. Partial Dilatation of Ducts, etc.	Dr. Bristowe	220
Case 2. Cirrhosis; Abscess of Liver; Stricture and Dilatation of Ducts; Fatty Kidneys.	Dr. Bristowe	222
Case 3. Obstruction of common Duct by a Gall-stone. Dilatation and Destruction of Hepatic Ducts, etc.	Dr. Bristowe	223
Case 4. Knotty Tumour of Liver; Obstruction and Dilatation of Hepatic Ducts; Ascites, etc.	Dr. Bristowe	223
Case 5. Cancer of Stomach, Liver, and Peritoneum; Cancer of Walls of Common Duct; Obstruction and Dilatation of Tubes.	Dr. Bristowe	224
Case 6. Cancer of Lesser Omentum; Obstruction and Dilatation of Hepatic Ducts.	Dr. Bristowe	225
Case 7. Cancer of Pylorus, Duodenum and adjacent parts; Obstruction of Common Duct; Dilatation of Hepatic Ducts.	Dr. Bristowe	225

19.
Medullary Cancer of the Common Bile-duct; Dilatation of all the Biliary Ducts; Enlargement of the Gall-bladder; Cancerous Growth in the Pancreas; Intense Jaundice. — Dr. Van der Byl . . 228

20.
Cirrhosis of the Liver; the Gall-bladder filled with four Biliary Calculi, one of them Encysted. — Dr. Gibb 231

21.
Calculus of Inspissated Bile, associated with Fibrous Tumours of the Uterus. — Dr. Gibb 233

22.
Specimen of Cancer of the Liver, with Remarks on twenty-nine cases. — Dr. Van der Byl . . 234

23.
Large rounded Cyst in the substance of the Liver, containing fluid and surrounded by a thick layer of Carcinomatous material. Cancer of the Pylorus of the Stomach. — Dr. John W. Ogle . . . 237

24.
On the connection between Abscess of the Liver and Gastro-intestinal Ulceration. — Dr. Bristowe . . . 241

Case 1.
Abscesses of Liver; Punctured externally, and opening through the Lung. Dysentery. — Dr. Bristowe . . . 252

Case 2.
Abscess of Liver, punctured externally. Secondary Hepatic Abscesses. Dysentery. — Dr. Bristowe . . . 258

		Page
Case 3. Empyema, Paracentesis. Abscesses of Liver. Dysentery. Incipient Phthisis.	Dr. BRISTOWE	264
Case 4. Dysentery. Abscesses of Liver.	Dr. BRISTOWE	268
25. Specimens of Syphilitic Disease of the Liver.	Dr. WILKS	270
26. On the Modes in which Hepatic Abscesses may be formed in connection with Disease of the various Systems of Tubes which ramify throughout the Liver.	Dr. BRISTOWE	273
Case 1. Pyæmic Abscesses in the Liver.	Dr. BRISTOWE	278
Case 2. Chronic Ulcer of the Stomach, Suppuration, Inflammation of the Stomach and Jejunum; Pus in the Portal Veins.	Dr. BRISTOWE	279
Case 3. Abscess of Liver, with Secondary Abscesses of the same Organ, due to Perforation of the Hepatic Veins.	Dr. BRISTOWE	283
Case 4. Obstruction of the Common Duct by a Calculus; Dilatation, Suppuration, and Destruction of Hepatic Ducts: communication with Branches of Portal Vein and with Lung.	Dr. BRISTOWE	285
Case 5. Hydatid Abscess of Liver. Secondary Abscesses due to Obstruction of one of the Ducts.	Dr. BRISTOWE	290
27. Large Hydatid in the Liver.	Mr. HENRY THOMPSON	294

DISEASES, ETC., OF THE GENITO-URINARY ORGANS.

		Page
1. Two Calculi of Enormous Size, filling the Urinary Bladder.	Mr. HENRY THOMPSON	295
2. Urinary Calculus adherent to the Bladder.	Dr. VAN DER BYL	296
3. Urine containing Cystine.	Mr. B. BALDING	297
4. Enlargement of the Prostate, affecting mainly its Anterior, and only slightly its Lateral and Posterior Portions.	Mr. HENRY THOMPSON	298
5. Three specimens of Fibrous Tumours of the Ovaries.	Dr. WILKS	299
Report on the above.	Dr. BRISTOWE and Mr. J. HUTCHINSON	301
6. Specimen of Enlarged Clitoris.	Dr. SYDNEY JONES	305
7. On the minute Anatomy of the so-called Fibrinous Deposits in the Kidneys.	Dr. G. JOHNSON	305
8. Tubercular Disease of the Testicle.	Mr. C. HEATH	307
9. Extremely degenerated Kidney in Bright's Disease.	Dr. WILKS	308

		Page
10. A Series of Eleven Uteri and Appendages, in which the majority had the Left Ovary placed at a greater distance from the Body of the Uterus, than the Right One.	Mr. NUNN	308
11. Diseased Kidney, with Observations upon Microscopic Cysts of the Kidney.	Dr. BRISTOWE . . .	309
12. A large Hydrocele in the Right Groin; the Testicle being undeveloped and detained in the Inguinal Canal.	Mr. T. B. CURLING . .	316
13. Undeveloped left Testicle, detained in the Groin, outside the Abdominal Ring; Hypertrophy of the Right Testicle.	Mr. T. B. CURLING for Mr. B. PAGE . . .	317
14. An Ovarian Cyst which was tapped four years before the death of the Patient, and did not fill again until a week before her death.	Dr. FULLER . . .	318
15. Multi-locular Ovarian Cyst successfully removed by Ovariotomy.	Mr. SPENCER WELLS . .	321
16. Ovaries shewing False Corpora Lutea with commencing Cystic Disease; peculiar Crystallöid Bodies in the Colouring Matter of the Corpus Luteum.	Dr. GRAILY HEWITT . .	323
17. Large Multi-locular Ovarian Tumour.	Dr. JOHN W. OGLE . .	325

		Page
18. Enchondroma of the Testicle.	Mr. Jonathan Hutchinson	326
19. Recurrent Fibröid Tumour of the Uterus, with Growths of a similar character in the Pericardium, in the Lungs, and in the Body of the Sixth Cervical Vertebra.	Mr. George Callender	327
20. Cystic Tumour of the Cervix Uteri, removed by the Ecraseur.	Mr. Spencer Wells	332
21. Cystic Disease of the Kidney.	Dr. Markham	334
22. Multi-locular Ovarian Tumour successfully removed by Abdominal Section.	Mr. Jonathan Hutchinson	335
23. Rupture of the Urethra of many years duration, which produced but few Symptoms until shortly before Death.	Mr. Mitchell Henry	337
24. Medullary Cystic Disease of the Testicle.	Mr. Thomas Bryant	340
25. Calculus, weighing three ounces and three-quarters, which was adherent to the Bladder, removed by Lithotomy, from a Boy.	Mr. Mitchell Henry	342

DISEASES, ETC., OF THE OSSEOUS SYSTEM.

		Page
1. Comminuted Fracture of the Lower Extremity of the Femur extending into the Knee-Joint; united with considerable Shortening and Deformity.	Mr. ADAMS for Mr. B. TRAVERS, JUN.	343
Mr. B. Travers' History of the above.	Mr. ADAMS for Mr. B. TRAVERS, JUN.	343
2. Fracture of the Neck of the Femur.	Mr. PART	344
3. Necrosis of a large portion of the Lower Jaw.	Mr. THOMAS BRYANT	345
4. Formation of a False-Joint between the Odontöid Process and Body of the Axis.	Mr. SHAW	346
5. Diseased Knee-Joint removed by the Operation of Excision.	Mr. PRICE	347
6. Ulceration of the Under Surface of the Patella, occurring after Removal of the Knee-joint.	Mr. PRICE	348
7. Head of the Femur removed by the operation of Excision.	Mr. PRICE	349
8. Cancer of the Spine.	Mr. C. HEATH for Dr. TODD	350
9. Fibrous Tumour developed within the Lower Jaw, surrounding the Dental Nerve.	Mr. T. BRYANT	351
10. Necrosis of the Tibia, from a Child twenty-eight days old.	Dr. SALKELD JOHNSON	353

		Page
11. Morbus Coxæ. Death from Encephalitis.	Mr. Oliver Chalk	353
12. Fracture of the Neck of the Femur within the Capsule.	Mr. Thomas Bryant	357
13. Impacted Fracture of the Neck of the Thigh Bone.	Mr. Thomas Bryant	357
14. Base of the Skull attacked by Epithelial Cancer.	Dr. R. Bennett	358
15. Edentulous Lower Jaw having no Mental Foramina.	Mr. Christopher Heath	360
16. Three Cases of Disease of the Hip-joint.	Mr. Thomas Bryant	361

DISEASES, ETC., OF THE ORGANS OF SPECIAL SENSE.

EYE AND EAR.

1. Adhesion of the Retina to the Cicatrix, following the removal of the Cornea.	Mr. Robert Taylor	362
2. Pigment in the Tympanum.	Mr. J. Hinton	363
3. Hæmorrhage supervening on the operation of Extraction; immediate Excision of the Eyeball; appearances found in the Dissection of the Eyeball.	Mr. J. W. Hulke	364
4. Malignant Growth within the Eyeball.	Mr. E. C. Hulme	365

TUMOURS, MORBID GROWTHS, CYSTS, ENLARGED GLANDS, ETC.

		Page
1. Fibro-Plastic Tumour of the Humerus; containing Myelöid Cells, for which Amputation of the Shoulder-joint was performed; recurrence of the Disease; Death three months after the operation. Secondary Tumours in the Lungs.	Mr. Mitchell Henry	367
2. Epithelioma (?) of the Female Breast.	Mr. Spencer Wells	375
3. Case of Osteöid Cancer combined with Myelöid Disease.	Dr. Wilks	377
4. Fibro-plastic Tumour in the Calf of the Leg.	Mr. Thomas Bryant	379
5. Double Sub-Pericranial Cephalhæmatoma.	Dr. Gibb	380
6. Tumours, probably Enchondromatous, of the Bones of the Hand.	Mr. T. Holmes	382
7. Blood Cyst from the Thigh.	Mr. T. Holmes	383
8. Two Specimens of Fatty Tumour.	Mr. T. Smith	384
9. Epithelial Tumour of the Breast.	Dr. Van der Byl	385
10. A congeries of very large Cysts containing Milk, developed in the Breast.	Mr. Birkett	386

Page

11.
A Case of Carcinoma Fibrosum, or Scirrhous Cancer of the Breast, with Cysts containing Serum mixed with Blood. — Mr. Birkett . . . 388

12.
An uncommon variety of Cystic Disease of the Breast. — Mr. Birkett . . . 390

13.
Five Cases of Tuberous Cancer of the Breast illustrating the Natural History and Progress of the Primary Growth. — Mr. Birkett . . . 393

14.
Chondro-Osteoid Growth among the Muscles of the Posterior Femoral Region; Excision; Cure. — Mr. Birkett . . . 397

15.
A large Fibro-plastic Tumour, connected with the upper extremity of the Humerus. — Mr. Christopher Heath . 398

DUCTLESS GLANDS.

SUPRA-RENAL CAPSULES.

1.
Cancerous deposit in the Right Supra-renal Capsule. Left one normal. No Bronzed Skin. — Dr. Murchison . . . 400

2.
Exhibition of a Living Rat from which both the Supra-renal Capsules and the Spleen had been removed. — Dr. George Harley. . 401

3.
Diseased Supra-renal Capsule, Removal by Operation from an apparently healthy Animal. — Dr. George Harley . . 401

		Page
4. Scrofulous Disease of the Supra-renal Capsules.	Dr. George Harley .	402
5. Scrofulous Deposit in the Supra-renal Capsules.	Mr. T. Holmes . .	405
6. Two Supra-renal Capsules of a remarkably unusual Form, and occupying a very unusual position. Substance of these Organs healthy.	Dr. John W. Ogle .	406
7. Extensively Cirrhosed and Fatty condition of the Supra-renal Capsules. Absence of any Bronzing of the Skin. Softening of the Left Cerebral Hemisphere. Hemiplegia of the Right Side.	Dr. John W. Ogle	407
8. Extensive Scrofulous Deposit in the Supra-renal Capsules; Death by Acute Pulmonary Phthisis; Absence of Bronzed Skin.	Dr. George Harley .	410
9. Bronzed Skin; one Supra-renal Capsule Diseased.	Mr. Henry Thomson .	411
10. Limited Disease of the Supra-renal Capsules in a Lunatic. Bronzing of the Skin.	Dr. Quain for Dr. Bucknill	412
11. Two Supra-renal Capsules affected by Scrofulous Matter, and taken from a patient who had died of Phthisis and Pneumothorax.	Mr. T. Holmes'. .	414

		Page
12. Disease of the Supra-renal Capsules, without Bronzed Skin.	Dr. Brinton	414
13. Bronzing of the Skin, in a Boy, with old Disorganization of both Supra-renal Capsules.	Mr. Jonathan Hutchinson	414
Special Report on the above cases, by a Committee appointed at the commencement of the Session.	Dr. J. S Bristowe, Mr. Jonathan Hutchinson, Dr. George Harley, Dr. John W. Ogle, Mr. Septimus W. Sibley, Dr. Samuel Wilks	417

THE SPLEEN.

14. Extensive Tubercular disease of the Spleen from a Child suffering from Purpura.	Mr. Septimus W. Sibley	425

MISCELLANEOUS SPECIMENS.

STATES OF THE BLOOD, ETC.

1. Drawing of a Case of Congenital Deficiency of the Latissimus Dorsi, and of the Lower portion of the Pectoralis Major Muscles, the Pectoralis being wanting below the second rib.	Mr. T. W. Nunn	427
2. Case of Polydactylism, in which nine Toes existed on one Foot.	Mr. Athol A. Johnson	427
3. Hydatids, formed and discharged, subsequent to Injury to the Tibia.	Dr. H. Daubeny	430

		Page
4. Femur and Hip-joint taken from a patient who had been affected by Talipes Equinus Paralyticus.	Mr. Nunn	432
5. Fatal Jaundice (?) without discoverable Structural Disease of the Liver.	Dr. J. S. Bristowe	432
Report on the above.	Dr. W. S. Kirkes and Dr. John W. Ogle	438
6. Case of Death from Anæmia. Fibrinous Clots in the Heart.	Dr. Leared	438
7. Spina-bifida in the Lumbo-sacral Region, which had Ruptured in Uterô, associated with Talipes Varus in both Feet. The child lived four days.	Mr. W. Adams	440
8. Neuralgia and Paraplegia, supposed to be due to the long continued use of arsenic, of which a trace was found in the Liver and Bones.	Dr. Gibb	442
9. Sugar in the Tears from a Case of Diabetes.	Dr. Gibb	447
10. Congenital, Supernumerary and Imperfectly Developed Auricles on the sides of the Neck.	Mr. J. Birkett	448
11. Illustrations of the Effects of Infantile Syphilis in marring the Development of the Teeth.	Mr. Jonathan Hutchinson	449
Committee's Report on the above.	Dr. Graily Hewitt, Mr. Henry Lee, Mr. Henry Thompson	455

SPECIMENS FROM THE LOWER ANIMALS.

		Page
1. Pulmonary Entozoic Disease of Sheep.	Dr. H. RANKE	456
2. Absence of the Left Foot in a Cat.	Dr. T. OGIER WARD	460
3. Multi-locular Cystic Tumour, with Villous Intra-cystic Growths, from the Breast of a Bitch.	Mr. SEPTIMUS W. SIBLEY	460
4. Diseased Spleen of a Pig.	Mr. MITCHELL HENRY	462
5. Mulberry Calculi studded with Crystals, from the Kidney of a Horse.	Dr. GIBB	463

PLATES.

PLATE		PAGE
I.	Encephalocele presenting at the Root of the Nose (Mr. SHAW)	1
II.	Neuroma of the Sciatic Nerve (Mr. FLOWER)—Pedunculated Growth from the Arachnoid Membrane (Dr. OGLE)—Mr. Curling's Case of Epithelial Cancer of the Larynx (Dr. A. CLARK's Report)	13
III.	Fibrinous Casts from the Bronchi (Dr. PEACOCK)—Malformation of Aortic Valves (Dr. PEACOCK) . . .	53
IV.	Upper Lobe in Case of Syphilitic Fibroid Deposit in the Lung (Dr. WILKS)	56
V.	Patch of Muscular Fibre in, and Ulcerative Perforation of Anterior Flap of the Mitral Valve, etc. (Dr. OGLE) . .	109
VI.	Spontaneous Ulceration of the Femoral Artery (Mr. A. LEGGATT)	162
VII.	Nævus of the Leg in Various Stages (Mr. T. BRYANT) .	186
VIII.	Mr. J. Hutchinson's Case of Intestinal Casts (Dr. A. CLARK's Report on their Microscopical Structure) . .	190
IX.	Parts of Generation in Case of Enlarged Clitoris (Dr. SYDNEY JONES)—Cystic Tumour of the Cervix Uteri (Mr. SPENCER WELLS)	305
X.	Fibrinous Deposits in the Kidney (Dr. G. JOHNSON)—Mr. Heath's Specimens of Tubercular Disease of the Testicle (Dr. A. CLARK's Examination)—Microscopic Cysts of the Kidney (Dr. BRISTOWE)	308
XI.	Cystic Tumour of the Cervix Uteri (Mr. SPENCER WELLS)—Adhesion of the Retina to a Cicatrized Cornea (Mr. R. TAYLOR)—Malignant Growth within the Eyeball (Mr. HULME)—Fibro-plastic Tumour of the Humerus, with Myeloid Cells (Mr. M. HENRY)	333
XII.	Example of Malformed Teeth, from a Photograph (Mr. J. HUTCHINSON)	450
XIII.	Entozoa in the Lungs of Sheep (Dr. RANKE) . .	458

WOODCUTS.

FIG.		PAGE
1.	Epithelial Tumour of Sciatic Nerve (of the natural size)	12
2.	Section through Pleural Abscess at its lower extremity	51
3.	Tubular Cast of the Trachea (of the natural size)	52
4.	Part of Left Lung, with Clots in the Pulmonary Artery	93
5.	Part of Superior Mesenteric Vein, with Tunnelling of the Obstructing Coagulum	94
6.	Pulmonary Artery from a Tubercular Lung	94
7.	Large Rounded Cyst in the Liver, with Carcinomatous Investment	238
8.	Cystalloid Bodies from the Yellow Matter of False Corpora Lutea	324
9.	Bladder and Portion of Ruptured Urethra	339
10.	Axis and its Separated Odontoid Process	346
11.	Enchondromatous Tumours of the Bones of the Hand	382
12.	Test-tube of the contents of Cysts containing Milk	387
13.	Kidney, with attached Supra-renal Capsule, flattened and misplaced	406
14.	Foot with Nine Toes	427
15.	Swelling on the Tibia, from which Hydatids were discharged	431
16.	Congenital Supernumerary Auricles on the Sides of the Neck	448
17.	Exfoliated Jaw and Fangless Crowns of Four Teeth, the supposed consequence of Infantile Syphilis	452

DESCRIPTION OF PLATE I.

This figure (after a photograph) illustrates Mr. Shaw's case of Encephalocele presenting at the root of the Nose, p. 1.

Arthur West

W West

REPORT.

SESSION 1857-58.

I.—DISEASES, ETC., OF THE NERVOUS SYSTEM.

1. *Case of Encephalocele, presenting at the root of the Nose.*

Mr. Shaw brought to the Society for the inspection of the members, a male infant, then under his care in the Middlesex Hospital, affected with encephalocele, situated in an unusual part, the root of the nose.

The child was æt. three months, had been in good health since birth, was lively, and, for its age, intelligent. The mother was a healthy woman, thirty-four years of age, the wife of a farmer's servant; she had seven children living, and had met with two miscarriages. Her last confinement was a perfectly easy one. The tumour was perceived at birth, and it had the same appearance then as it has presented since; it has become larger, but slowly, as if its growth kept pace with that of the child generally.

The principal characters of the tumour are represented by the engraving, (Plate I.) taken from a photograph. From the apex on the right side a small process or diverticulum projected; otherwise the contour of the tumour was uniformly convex and regular. The skin was sound and of natural colour; it adhered generally to the walls of the tumour, which seemed to consist of thin dense membrane. At the base, the well defined borders of a circular opening in the bones, between the eyebrows and at the root of the nose, could be felt; and below the centre of that opening, the ossa nasi and cartilages of the nose were traced, of their natural size and shape. When steady pressure was made upon the tumour it yielded gradually, till it became level with the adjoining surfaces, and on the pressure being left off, the tumour

quickly returned to its original size. On firmly holding it with a finger on each side, two kinds of pulsation were discerned, similar to what are perceived in fungus cerebri; first, a pulsation synchronous with the pulse at the wrist; secondly, a pulsation corresponding to the variations in the venous circulation of the brain dependant on forced inspiration or expiration.

Mr. Shaw expressed his opinion that the tumour consisted of a membraneous sac, the walls of which were continuous with, or a prolongation from, the dura-mater; that it contained within it serum, derived either from the arachnöid cavity, or ventricles of the brain; and that, perhaps, a portion of the brain itself might be included in its deeper part. He regarded it, in short, as an encephalocele, in which the opening through the skull, instead of being, as in the majority of cases, at or near the occiput, had been formed, in fœtal life, between the sutures connecting the frontal, æthmöid, and nasal bones.

As to the treatment:—when he considered the general good health of the child, the absence of cerebral symptoms, and the slow growth of the tumour, he was averse to performing any operation upon it. The large opening through the skull precluded hopes of the walls contracting and the tumour becoming obliterated by frequent puncture and evacuation of the fluid contained in its cavity; and such repeated wounds, although by a grooved needle alone, inflicted on a membrane continuous with the dura mater, could not be made without hazard. Accordingly, as recorded cases are not wanting of spontaneous cures having been effected in tumours of the same kind met with in other parts of the skull, he thought it preferable to avoid risk, by abstaining from active interference with the processes of nature.

Mr. SHAW, 1*st of December*, 1857.

---

2. *Cancerous Growths connected with the Membranes of the Brain, and producing Hydrocephalus.*

R. D., a child, æt. 2½ years, was admitted into St. Thomas's Hospital under my care, on the 8th of September, 1857. He had been perfectly healthy, and had presented no abnormal condition of the head until the previous March. During the early

part of that month, he was attacked with a slight cough, attended by expectoration, which lasted for a fortnight; after which, without obvious cause, the gums became spongy and inclined to bleed, and continued in this condition, off and on, nearly up to the time of admission. Coincidently with the catarrhal attack, the child's head began to enlarge; and the enlargement has increased gradually up to the present time; in proof whereof, the mother stated, that a cap which she made for him in April, would not nearly fit him in September. In April, the lower extremities began to shew signs of weakness, and in a short time all power over them was lost. Violent retching, coming on every day or two or even at longer intervals, was a marked symptom from the first, but has disappeared during the last six weeks. The appetite, however, has been good all along. During the last three weeks, the child has been getting manifestly worse; has become restless, less sensible, and has, in some measure, lost the power of speech; has begun to grind his teeth at night, and to wake up suddenly with screams; and during the day, to have frequent fits of screaming, together with spasmodic contractions of the legs. He does not appear to have had pain in the head, and the bowels have been generally regular.

Present condition, Sept. 10th.—He lies on his side, or in whatever position he is placed, and does not appear to move the head or the body spontaneously; when lifted up he keeps the neck rigid, and cries or screams as though in pain. The arms are extended, but whenever paroxysms of crying come on, they are moved with a trembling motion towards the head, soon to fall back into their original position without attaining their apparent object. The legs are stiff and extended, and the great toes stand rigidly upwards. The child appears to have no power over them, and little or no sensation in them, but reflex actions are easily excited; and they are always drawn up spasmodically in concert with the corresponding motion of the arms. The eyes are turned to the left, and rarely move (never for more than an instant) from that position; the pupils are dilated and insensible to light. The head is large and hydrocephalic, the anterior fontanelle unclosed. He lies for the most part quiet, but every five or ten minutes whines for a few seconds, and at the same time exhibits the spasmodic

actions before described. He takes but little notice of what is said, yet can be occasionally induced to answer, and is evidently not altogether insensible. Head hot; skin generally warm; breathing quiet; pulse 120, small and regular; tongue clean; appetite good; no sickness; urine and motions passed unconsciously, but bowels regular.

He remained in very much the same state up to the 5th of October. The appetite continued good, the respirations quiet, the pulse rapid and small, and the alvine discharges natural. He manifestly became weaker, however, although there was no loss of flesh; and he very soon ceased to take any notice of what was said to him, and to make any attempt at reply. He was treated at first with small doses of hydrargyrum c̄ creta, leeches to the temples, and ice to the head, together with occasional purgative doses of hydrargyrum c̄ rheo; latterly with iodine paint to the scalp, and iodide of potassium internally.

October 6th.—The child was suddenly taken worse last evening; has been constantly convulsed during the night, but is at present quiet. The head, however, is thrown far back and fixed in that position, the face is flushed, and the superficial vessels of the head and neck are much distended. The arms too, and legs, are very rigid. He has not wholly refused his food, and the bowels are freely open. The convulsions recurred, and he died at 4 P.M. on the 7th.

Post-mortem examination.—The head was considerably enlarged, and presented the form characteristic of hydrocephalus. The calvaria, on removal, was found to be unusually thin and transparent; the sutures were widened and occupied by fibrous tissue, and the anterior fontanelle was imperfectly closed. The portion of dura mater lining the calvaria was healthy. The convex surface of the cerebrum was accurately adapted to the parietes; there was, consequently, little or no sub-arachnöid fluid, and the convolutions were widened and flattened. The larger veins contained but little blood, yet the surface of the brain generally was slightly congested. On removing the brain, there was but little, at first sight, to attract attention; except in the posterior fossa, where the under and back part of the cerebellum was adherent to the dura mater in the neighbourhood of the falx minor, and appeared

to have left a considerable portion of its substance behind. That, however, which looked like brain substance, was found to be a soft, cream-coloured, creamy-juice-yielding growth (or rather collection of growths), altogether as large as a good-sized walnut. This sprung from the free surface of the dura mater on each side of the falx, in an area of about a square inch and a half, and projected into, and was adherent to the corresponding part of the cerebellum, a thin layer of which was left attached to its surface. The portion of it adherent to the brain was much congested. One or two pea-sized hemispherical growths of the same nature as the above were discovered growing also from the parietal arachnöid of other parts of the posterior fossa. In no instance did the disease extend through the entire thickness of the dura mater, and the subjacent bone was always perfectly healthy.

The substance of the brain generally was healthy in regard to consistence and vascularity. The lateral ventricles were very greatly distended, and contained nearly a pint and a half of perfectly transparent limpid fluid; their parietes were everywhere smooth and in no degree softened. The walls of the fifth ventricle measured nearly an inch in their vertical admeasurement, and were exceedingly thin and transparent, but perfect. The foramen of Monro, which formed the only real communication between the opposite cavities, was large enough to admit the little finger. The fornix and velum interpositum were in contact with one another, and healthy; and the choröid plexuses were pale and natural. The cerebral sulci were of course much shallower than usual, and the entire thickness of brain-substance between the ventricles and the surface varied from three quarters of an inch to an inch. The substance of the cerebellum was generally healthy, but on close examination a considerable amount of disease was discovered on its surface. That part to which the tumour, before described, had been attached, was soft and disorganized; but there were also, here and there, seated in the arachnöid or sub-arachnöid tissue, numerous flat patches, having a whitish, but slightly translucent aspect. Many of these were lenticular, from half an inch downwards in width, and from a line and a half to a line in thickness; others were larger and less regular in outline; but all seemed to have

originated in the membrane, and only a few encroached in any way on, or involved the subjacent brain-structure. They were abundant, both on the upper and under surfaces, and especially so about the origins of the nerves. Two or three similar patches were discovered on the surface of the cerebrum; and a mass, about as large as a hazel-nut, was found embedded in the substance of the anterior inner and lower corner of the left cerebral lobe, firmly attached to the arachnöid on one side, and surrounded by softened brain substance in the rest of its extent. Nodules of similar material surrounded (without destroying) the cranial portions of many of the cerebral nerves, or were connected with the surface of the brain near their origins. Thus the dilated extremities of both olfactory nerves were embedded in growths the size of horse-beans; the optic commissure and commencement of the optic nerves were surrounded by the same kind of growths; the origins of the fifth pair were involved in masses as large as peas; and the sixth pair, with the left branch of the seventh, appeared to pass through the substance of small masses immediately before entering their foramina. Most of the other nerves springing from the medulla oblongata were affected in a similar manner to a greater or less extent.

All the growths above described had a whitish, but at the same time translucent aspect, presented a certain amount of firmness, and yielded much creamy-juice on pressure. Some of the larger ones were much congested. Under the microscope they were seen to consist of an imperfect refractive kind of fibröid material, together with large numbers of round or ovöid nuclei, which readily became free, and were a little smaller than pus-corpuscles.

The left orbit was examined and all the nerves in it found healthy.

The thoracic and abdominal viscera, together with the testicles and supra-renal capsules, were in a perfectly healthy condition.

All the symptoms which were manifested in the above case, might well have been ascribed to chronic hydrocephalus; and that they were really due to accumulation of fluid in the ventricles is, I think, rendered very probable by the results of the *post-mortem* examination; for although a considerable amount of cancerous growth was present, it formed for the most part, in connec-

tion with the membranes, small flattened masses only which could not have produced any very serious amount of pressure, and could scarcely have excited much cerebral irritation, inasmuch as convulsions and other characteristic symptoms were for the most part wanting. It seems highly probable, however, that the development of cancer was the exciting cause of the dropsical accumulation, and hence indirectly produced the symptoms under which the child laboured.

It may be a question with some, whether the growths connected with the membranes were really malignant. In reply to this I may remark, first, that they presented the naked-eye characters which are usually assigned to medullary cancer; secondly, that their microscopic structure accorded exactly with that which is most commonly observed; and thirdly, that they were precisely similar to tumours which I have seen in other cases, connected with the cerebral membranes, and at the same time associated with growths of the same nature in other organs of the body.

Dr. Bristowe, *15th of December*, 1858.

---

3. *Effusion of Blood into the Pons Varolii.*

J. W., a pewterer, æt. 44, was admitted into St. Thomas's Hospital, on the 1st of December, 1857, in a state of complete coma, with explosive breathing, and pulse about 60 in the minute, rapidly failing in power. There were no twitchings or convulsions, and he died in about an hour. His fellow-workmen, who brought him in, stated that he had just fallen down in a fit, and added, that he had been subject to this form of affection.

Post-mortem examination.—Height, five feet five inches; weight, nine stone nine pounds; in good condition.

Calvaria and dura mater healthy. The vessels on the surface of the brain contained an ordinary amount of blood, and the sub-arachnöid fluid was in normal quantity. The substance of the brain was generally healthy, both as regards colour and consistence, though, perhaps, a little more congested than usual. The ventricles contained but little fluid, and their parietes were not softened. The pons Varolii appeared unusually plump, and two or three very small clots lay on its surface in the sub-arachnöid

tissue. It was remarkably soft and elastic to the touch, but these characters did not extend to the crura cerebri, or crura cerebelli, or into any adjacent portion of the brain. On making a section, the pons was found to be occupied by a cavity about as large as a moderate sized walnut, which was filled with a soft black-currant jelly-like coagulum, and the internal surface of which was ragged and irregular as though produced by rupture. The thickness of the walls varied from one-eighth to one-sixth of an inch. All other parts of the brain and the cerebral arteries were healthy.

Pericardium healthy. Heart large, weighing nineteen ounces. The walls of both ventricles were thick and firm, the cavities contracted and empty. All the valves were healthy except the aortic; and these did not appear to be incompetent, though their incompetence was not tested. They were a little contracted and thickened, and presented along their attached margins several nodules of earthy matter, from the size of a pea downwards. One, rather larger than the rest, was prolonged on to the base of the mitral. The pleuræ presented a few old adhesions. The lungs were rather large, crepitant throughout, but congested and œdematous. The aorta presented a good deal of atheromatous deposit.

The kidneys were pale, slightly granular, and contained two or three small cysts, but all the other abdominal viscera were perfectly healthy.

The above case is recorded chiefly because a case of the same kind of disease was brought under the notice of the Society last year by Dr. Hare. It will be observed that the twitching of the muscles, which, with a few other features, were present in Dr. Hare's case, and thought by him to indicate hæmorrhage into the pons, were not recognised in that which I have brought forward. Dr. Bristowe, *15th of December*, 1857.

---

4. *General Paralysis; Softening of the Spinal Cord; Inflammation of the Cerebral Membranes.*

A farm labourer, æt. 48, married, was admitted about eleven months ago into the Somerset County Lunatic Asylum, with general paralysis, combined with dementia of twelve

months' duration; from the time of his admission he had been gradually becoming worse; after his admission his spine was blistered, and he took, for some time, small doses of the liq.-hyd. bichlorid; he complained of pain in his back and loins; he had been in the Infirmary during the whole of the time, and able to sit up for a few hours daily till within the last week, when he was entirely confined to bed, and placed on the water bed, as there was a tendency to bed-sores on the hip; he had an ulcer the size of half-a-crown, on the right elbow, from leaning on that side, as for several weeks he could not sit upright, and for the last eight weeks he required to be fed. During the last month or six weeks he used often to cry out with a shrill cry, as if some one were hurting him. Never at any period had he been able to answer a question rationally; he sank gradually at last.

Post-mortem examination.—The body was examined twenty hours after death; weight, ninety-four pounds; height, five feet four inches. On dividing the dura mater in front on the right side, about four ounces of fœtid pus escaped, the anterior lobe of the right cerebral hemisphere, beneath as well as above, being bathed in pus, and the arachnöid lining the dura mater also being thickly covered with it, and when washed, red beneath; the redness, and a coat of fibrin covered the membranes lining both temporal fossæ and the upper orbital portion of the base of the skull on the left side; a portion of these membranes have been sent with the entire brain, which, with the upper portion of dura mater, weighed forty-five ounces and a half. This inflammation of the cerebral membranes is evidently of recent date. But, in addition, I have sent the spinal marrow, which is softened throughout. I may say that I have frequently remarked softening of the spinal marrow in cases of general paralysis. Two eminent microscopists have examined some of these cases, and considered them to be the result of inflammation. In the present case, the symptoms of general paralysis were well and distinctly marked.

The lower lobes of both lungs were advancing towards the second stage of pneumonia. The abdominal organs were in a healthy state. Mr. Obré for Dr. Boyd, *26th of December*, 1857.

---

5. *Softening of the Spinal Cord; General Paralysis, combined with Mania.*

C. F., an army pensioner, and agricultural labourer, æt. 47, married, was first admitted to the Somerset County Lunatic Asylum in October, 1853, in a state of mania. He was most enthusiastic on religious subjects, and stammered very much in the manner of those persons affected with general paralysis, but it was said to be natural to him. His motion was firm, his health indifferent; duration of his illness two months, supposed to be caused by an injury from a blow on the head. He became more rational, his general health improved, and, at the end of eight months, he was taken home by his wife on probation, and was subsequently discharged.

Nearly two years afterwards, he was re-admitted; the symptoms of general paralysis were very decided; his articulation was very indistinct, and his gait unsteady; these symptoms gradually increased, and, at the end of seventeen months, he had to be removed to the Infirmary, where he continued till his death, which occurred three months after. Until within the last month he was able to sit in a low chair, but latterly he was perfectly helpless and unable to swallow solids. The disease progressed very gradually, until he became helpless and unconscious.

Post-mortem examination thirty-seven hours after death.—Weight of the body, one hundred and twenty-five pounds; height, five feet eleven inches. The brain was firm, the lateral ventricles contained about five or six drachms of clear fluid; weight of the brain, forty-three ounces. The upper three-fourths of the spinal marrow appeared to be softened, and the arachnöid thickened, being opaque in one place at the upper part and adherent, or having an adherent false membrane. It was very difficult in this case to get at it.

The cause of death was more immediately pleuro-pneumonia of the right lung; the lower lobe was partially covered with recent lymph, and hepatized as well as the lower portion of the upper lobe; the lung weighed fifty-eight ounces and a half; a portion of the lower lobe of the left lung was also in the first stage of

pneumonia, and weighed thirty-four ounces. There was no disease in the abdominal organs.

Mr. Obré for Dr. Boyd, 15*th of December*, 1857.

Report on the above Specimens.—Mr. Obré having exhibited to the Society, on various occasions, several interesting and valuable specimens of softening of the cord, associated with a given class of symptoms, we thought it desirable to determine, if possible, whether this softening was dependent on chemical causes, infiltration of serum, pathological changes in the structural elements, or disease of the minute blood-vessels.

The cord submitted to us for examination, however, was so much changed by the lapse of time and the action of the fluid in which it was preserved, that no satisfactory result could be obtained, except in relation to the specific gravity and the state of the blood-vessels.

The specific gravity of the cord was found to be lower than that of health; and the blood-vessels were everywhere free from obvious change.

We consider that the value of these specimens would be greatly enhanced by a microscopic examination, made immediately after their removal from the body.

George Johnson, M.D.
Andrew Clark, M.D. 5*th of January*, 1857.

---

6. *Epithelial Tumour in the Sheath of the Sciatic Nerve.*

The specimen was taken from the body of a woman who died in the Middlesex Hospital of cancer of the uterus. Besides the usual sumptoms of that disease, and great œdema of both legs, she had, for about four months before her death, suffered from severe pain in the course of the left sciatic nerve, with partial loss of motion of the extremity, which, latterly, she dragged after her in walking.

On *post-mortem* examination, the whole of the uterus, the upper half of the vagina, and the lumbar glands, were found to be involved in a mass of disease, which presented the usual

appearances, both general and microscopical, of epithelial cancer.

On dissecting the left gluteal region, a tumour was found in the position of the sciatic nerve, just after its escape from the

LIGN. 1.

Represents the tumour of the natural size.

pelvis, the upper part being in contact with the border of the pyriformis muscle. Two branches of the sacral plexus unite, and enter the upper extremity of this swelling; from its lower

DESCRIPTION OF PLATE II.

Figure 1 represents the microscopic structure in Mr. Flower's case of Neuroma of the Sciatic Nerve, p. 13.

Figures 2 and 3 illustrate Dr. Ogle's case of Pedunculated Growth from the Arachnöid Membrane, p. 14.

Fig. 2. A few of the villi, magnified.

* Opaque arachnöid membrane, from which the pedunculated growth arises.

Fig. 3. Fibres from the interior of the above, highly magnified.

a. Connective-tissue fibres.

b. Fibres with peculiar constrictions.

Figures 4 to 13 illustrate Dr. Andrew Clark's Report on Mr. Curling's case of Epithelial Cancer of the Larynx, p. 43.

The tissues are described at length in the text.

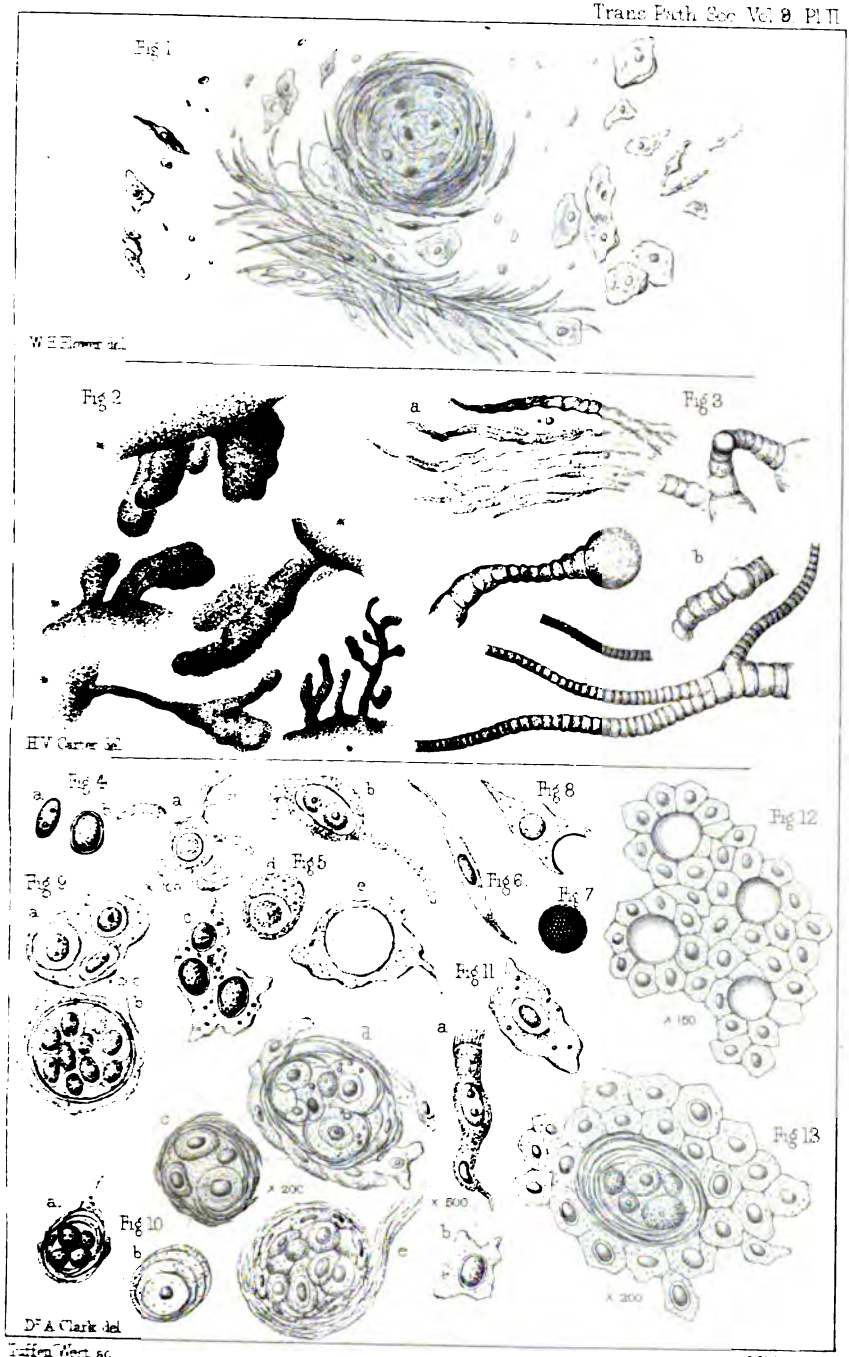
Fig 1
W E Flower del
Fig 2
Fig 3
a
b
H V Carter del
Fig 4
Fig 5
Fig 6
Fig 7
Fig 8
Fig 9
Fig 10
Fig 11
Fig 12
Fig 13
x 150
x 200
x 500
x 200
Dr A Clark del
Taffen West sc
W H Stump

end proceeds the great, and from its inner side, the small sciatic nerve. It is oval in shape, somewhat flattened, smooth, and slightly nodulated on its surface, two inches and a half long, and one inch and a quarter in its greatest breadth (Lign. 1). An incision made into it shews it to consist of a thin, fibrous membrane, evidently the expanded sheath of the nerve, as it is continuous with that structure above and below, and filled up with a whitish, soft, rather dry substance, readily breaking up into flakes. A microscopical examination of this (*vide* Plate II. Fig. 1) shews that it is entirely made up of scaly epithelial cells, most of them large, and of very delicate and characteristic appearance, others shrivelled and in various states of development and degeneration. The cells are mostly collected into laminæ, which appear to be arranged without any definite order, but, here and there, distinct concentric lamellation was observed, and I was able to isolate several good examples of the so called "laminated capsules."

A few imperfect plates of cholestearine were found among the epithelial scales. The deposit occupied not only the whole of the interior of the expanded portion of the sheath, but also invaded, for the distance of more than half an inch, the large branches of nerve at either end of the tumour, infiltrating between the nerve fibres; most of the latter were destroyed, only a few being continuous, and spread out on the inner surface of the sheath, on the under side of the tumour.

The diseased mass of lumbar glands extended on the left side, so as to be quite in contact with the sacral plexus of nerves and sciatic vessels as they leave the pelvis, and at one spot I could trace, by a small opening in the upper part of the sheath of the tumour, a direct continuity between the deposit outside and that within the sheath. At this place a small branch of the sciatic artery enters for the supply of the nerve, and along it, it would seem, the deposit has been conducted, and then, increasing within the sheath, and displacing and destroying the nerve fibres, has formed the tumour above described. I think this is the only solution that can be offered of the occurrence of an epithelial growth in so rare a situation as within the sheath of a large nerve. Mr. W. H. Flower, *5th of January*, 1858.

7. *Pedunculated Villous Growth of a peculiar character, from the Visceral layer of the Arachnöid Membrane covering the upper part of one of the Cerebral Hemispheres.*

The growth was situated on the arachnöid, at the distance of about two inches from the longitudinal fissure, and consisted of a rather glistening whitish-coloured tuft-like body, of about a quarter of an inch in length. On closer inspection, it was seen to consist of a group of two or three finger-like projections, rising from a common base, consisting of rather thickened, pearly arachnöid. The latter membrane around was, to some extent, altered in appearance, being thickened and opaque; and this was so with the arachnöid covering also the other cerebral hemisphere.

Microscopical examination.—On examining the pedunculated growth with a one-inch lens, the various parts of which it was composed were found to arise from a common neck, and to be composed (*vide* Plate II. Fig. 2) of numbers of pouches or glove-like villous or papillary projections, with prolongations here and there, having an arborescent appearance. All these had rounded extremities, the larger kind being also opaque and solid-looking and in places beset with, or containing granular bodies, which often were highly refractile. The smaller projections, were, however, pale and semi-transparent, and only in a very few places shewed anything like granular contents. In some cases, the whitened and thickened base from which these bodies sprang, shewed a quantity of opaque, granular, or molecular material. On tearing up the various parts of these bodies with a fine needle, and examining them with a lens of a quarter of an inch power, I found them to be very tough and tenacious, and histologically, to consist, in addition to small nucleated cells with free oval nuclei and granular matter, of elements which were of two kinds, and presented the following features. Firstly, there were connective-tissue fibres, fine as well as coarse, and tapering at their extremities, most of them also having a wavy, and in places, a jagged outline (Plate II. Fig. 3*a*). These existed in tolerable abundance, but were not so frequent as the other fibres, to be named. Secondly, there were very large numbers of fibres

or tubes, whichever they were, branching out in various directions, (Plate II. Fig. 3*b*.) and so peculiarly and regularly indented in a transverse direction, and that to a considerable depth, that they had the appearance of being surrounded, for the most part at equal intervals, by delicate circular bands or rings, by which they were considerably constricted. Their texture appeared to be homogeneous, and void of any longitudinal markings or nuclei, or nucleoli, even after the addition of acetic acid. The above appearances were seen after the specimen had been immersed in weak spirit and water, but previous to any treatment by other re-agents. Each of the ramifications of which the growth was composed was much shorter than the main branch or trunks from which it emanated, and gradually, but regularly, tapered towards its extremity. It will be seen, that here and there, the out-bulging intervals between the transverse ring-like markings, are longer than usual, and correspondently at these parts the calibre of the fibre or tube is much wider, as if an encircling band had been loosened or taken away.

History.—The specimen was removed from the body of a middle-aged man, who died of malignant disease of the liver, kidneys, &c. The cranium and the brain itself, were in all respects, healthy, but in addition to the opacity of the visceral arachnöid above named, there was found a thin layer of recent fibrin lining the dura mater covering both cerebral hemispheres. The Pacchionian bodies were observed as being not unusually large or numerous.

Commentary.—The peculiar interest connected with this specimen, lies in the unusual appearance of the above-described linear forms. I have never before, or since, seen structures exactly similar. Are they tubes, or are they fibres? This is a question which appeared to me originally, to be of difficult solution. At first sight, one is reminded by them of certain vegetable forms, confervöid growths, etc., but, of course, they cannot be of that nature. Again, one has seen muscular fibre, especially from the lower animals, with an outline somewhat resembling, but far from being exactly like them; and occasionally, newly-formed or forming vessels are met with, marked in a somewhat similar way. But, I think, independent of other considerations, such as the extreme regularity of the lateral bulgings, these bodies cannot be hollow as vessels

would be, seeing that in one or two cases, the divided extremities were observed, as in the plate, especially when enlarged as in one place and very clearly seen, to have a solid homogeneous look, and to leave no trace of any distinct paries or enclosing membrane. These structures must then, I think, be considered as solid and fibrous. But the structure mostly called to mind by the forms under consideration, is that species of fibrous tissue bundles, which is described and figured in many Treatises on Histology, as being surrounded by spiral elastic fibres. These connective-tissue bundles are depicted in all cases as being structures of much greater thickness than the fibres above described, and having out-bulgings at their sides, with a much more irregular and fortuitous and a less bead-like appearance. Moreover, besides the so called elastic spiral fibres, in most cases longitudinal ones also are drawn apparently in the interior of the main bundles, but these latter are never described as tapering after the manner of those which I have figured. Should the structure described in this communication, however, in reality, and in spite of the visible and morphological differences which I have enumerated, be a modification of the same tissue as I have mentioned just above as being described by writers, and should their ring-like transverse markings have an origin, similar to those looked upon by some authors as being occasioned by spiral fibres of elastic tissue coiled round the bundles of areolar tissue, it is of interest to observe, that much variety in opinion exists regarding these so-called spiral fibres, as found in various parts of areolar tissue. Henle seems to have been the first to have given this name and interpretation to the appearance in question, and he has been followed by Sharpey,* who describes and figures the fasciculus as swelling out "between the turns of the wandering fibre" after the application of acetic acid, and says, "it may be always seen in the cellular tissue, accompanying the arteries, at the base of the brain." Kölliker† also figures the same spiral-looking structure in secondary bundles, removed from the arachnöid; describing them as coiled, fine, elastic fibres, and

* *Vide* p. cxvi. of his "General Anatomy." 1848.

† *Vide* p. 62, vol. i. of his "Manual of Histology," as translated by the Old Sydenham Society.

speaking of them, as winding spirally round bundles of connective tissue, and nerves, etc. Again, Gerlach* figures what he terms spiral elastic fibres, which he says "coil round one or more connective-tissue bundles, either continuously, or more seldom in the form of separate rings."

Other physiologists, take a contrary view of these so-deemed elastic spiral fibres, as for instance did Luschka and Reichert formerly, and also Leydig,† who asserts that they are only artificial productions, not in the least existing as peculiar fibres. On the contrary, they are, according to him, portions of the outer layer of the connective-tissue bundles, which, on the addition of acetic acid, swell out, and cause it to be ruptured. This outer layer contracts when torn, producing the spiral-like fibres.

Klopsch also, of Breslau,‡ after reviewing the opinions of most of those who have written upon connective and elastic tissue, including those whom I have already named, as well as Virchow, Donders, etc., has come to the conclusion "that these apparent spiral elastic fibres do not in truth exist, but are produced by partial or circular rupture of the boundary layer of the connective-tissue bundle, which allows of the protusion of the contents; in many cases the lacerated outer layer contracting and forming a ring-like band."

Such are the conjectures respecting the actual interpretation of these spiral-like fibres or markings, conjectures, which of course, should my specimen be in fact, a modification of tissue possessing such spiral-like fibres, will be applicable in its case also.

For myself, however, I am disposed, on the whole, to explain the appearances presented by my specimen in a simpler way. I believe it most likely that the lateral bulgings or bead-like projections, for the most part diminishing in size, in proportion to the gradual tapering of the fibre, if fibre it be, are the relics of the original cell-forms of which the whole was formed. These transparent elements were, I conceive, appended in a linear series, end to end, and finally, absorption taking place of

* *Vide* p. 94 of his "Handbuch der Gewebelehre," etc., 1854.

† P. 31, "Lehrbuch der Histologie," 1857.

‡ Müller's "Archiv. Hft." v. 1857, p. 417.

their apposed walls, constituted a continuous chain of fibres. In fact, I suppose these branching and tapering structures with out-bulging limits to be modifications, or aberrant formations of fibrous tissue, and the transverse markings looking something like the so-called spiral fibres, to be owing to the line of juncture between the various component cell elements being visible through their transparent structures.

In conclusion, I would observe, that the growth which is the subject of this communication, was not an ordinary Pacchionian body. Its locality, removed as it was so far from the central longitudinal fissure, its solitude, its origin from the *visceral* layer of arachnöid, and the freedom of the actual Pacchionian bodies in the same cranium from any similar structures, precludes our ranking it among these bodies. It is, however, interesting to remark, that Wedl*, quoting Luschka, speaks of Pacchionian bodies in certain cases, as containing "numerous bundles which appeared to be surrounded, in an annular or spiral direction, by an elastic fibre." I have, however, above, given reasons for supposing the specimen in hand, not to be a Pacchionian body. Moreover, it could not from its position fulfil the supposed office of those bodies, which is the protection and supporting of the sinuses and veins.

I cannot bring this to an end without alluding to the drawings of certain fibres, found by Dr. Wilks, in connection with certain cysts on the heart. These fibres are depicted in plate v., vol. vi., of these "Transactions," and will be seen to present a peculiar beaded, or varicose appearance, but differed from the above-described structures in containing, in all cases, a central band passing along them longitudinally, as well as in other respects.

Dr. John W. Ogle, 19*th of January*, 1858.

---

8. *Apoplectic Clots.*

A gentleman, æt. 60, of scientific acquirements, of temperate habits, and of great energy both of body and mind, was suddenly seized in the night with violent cramps in the fingers and toes.

* P. 350 of his "Pathological Histology," translated by the Old Sydenham Society.

He was freely bled. In a few months he resumed his usual habits. A year afterwards, he had a well marked epileptic fit, which continued for ten minutes. After this, his sight failed greatly, so that on some days he was almost blind; but in all other respects he remained as he had been before the attack. Between one and two years afterwards, he had an epileptic fit, in a first-class carriage at the London Bridge Station, and was brought to St. Thomas's Hospital at eleven A.M. In a quarter of an hour, he became completely comatose. He was bled, and in the evening became conscious, and could answer questions. He remained in a dull state, but not comatose, for the next few days. A blister was applied behind the ears three days after the attack; in three days more, erysipelas extended over the neck and chest; and he died exhausted in thirty-six hours.

The recent morbid appearances were a small quantity of recently effused coagulated blood, in the sub-arachnöid tissue at the posterior part of each cerebral hemisphere, extending to the bottom of the sulci.

The whole of the under surface of the posterior lobe of the left cerebral hemisphere, that portion in contact with the cerebellum, was hollowed out, and deficient to the depth of half an inch. There was no appearance at this part of convolutions, and the membranes, somewhat thickened, formed a sort of loose, collapsed bag, upon its surface. This was evidently the result of an extravasation of blood (with partial destruction of the surface of the brain) which had ultimately become absorbed; an early stage of which process was manifested in the recent hæmorrhage. There was a little transparent fluid in the ventricles and sub-arachnöid tissues. The surface of the brain was congested, and the large veins at the posterior part were loaded with blood. There were a few spots of atheroma in the arteries at the base of the brain.

Dr. T. A. BARKER, 16*th of February*, 1858.

---

9. *Carcinoma (chiefly the Melanotic form) of the Brain, as also of other parts; Hemiplegia; Paralysis of Motion and Sensibility; Increased Temperature of paralysed parts; Peculiar Movement of the Paralysed Hand during the act of yawning and at other times; Death by Apnœa.*

The specimen shewed two masses of reddish-brown coloured carcinomatous material, of the size of a bantam's egg, occupying the surface of the brain; one situated at the anterior extremity of the left cerebral hemisphere, and the other at the posterior and upper part of the same cerebral hemisphere. In both cases, the masses which could be easily enucleated from the surrounding brain-texture, appeared quite superficially, having the dura mater and arachnöid membranes immediately adjacent, adherent and somewhat thickened and opaque, but not extensively so.

The brain-substance immediately surrounding these masses was somewhat softened, but this softening did not extend to neighbouring parts; and excepting a slightly increased amount of ventricular fluid, the brain and its investments were otherwise healthy. The carcinoma was healthy. Masses of carcinomatous material were also found in many other parts of the body, as in the sub-pleural tissue, upon the surface of the lungs, in the substance of the heart, pancreas, and kidneys, and in the bronchial, mediastinal, axillary, lumbar, mesenteric, inguinal, and other lymphatic glands.

One kidney was so entirely occupied by the growth, that it was of the size of a cocoa-nut, and exhibited scarcely a trace of natural structure. In the heart, masses existed in the walls of both sides, and in those of the right side they projected, in one or two places, considerably into the cavities. These deposits, in different parts, were of various dimensions, and also differed in colour, some being almost quite black or purple, whilst others, as that in the brain were, as before said, of a reddish-brown colour. In one part of the deposit in the brain, a small portion, of about the size of a horse-bean, was of a light cream-colour and presented the ordinary appearance of the soft encephalöid form. One portion of carcinomatous substance, of a dark-purple colour, was conspicuous as projecting from the anterior surface of a piece of the

mesentery at a point about one inch from the small intestine. This mass was of the size of a large walnut.

Microscopical characters.—Portions of the carcinomatous growth from the various parts of the body, presented much the same histological appearances. Independent of admixture of the tissue in which the growths existed, the general elements were round and oval, and elongated nucleated cells containing more or less pigmentary matter. In some places, which were of a lighter hue, as especially in the small cream-coloured portion within the brain, before alluded to, these nucleated cells were seen to be unoccupied by colouring matter. Moreover, in the masses within the brain, considerable remains of extravasated blood were seen, which gave to them their reddish colour.

History.—The specimen was removed from the body of a man, G. K., æt. 36, a labourer, whom I watched in St. George's Hospital, in the middle of 1856. He had, on two separate occasions, previously undergone operations for the removal of tumours from the surface of the body. Mr. P. Hewett had excised some enlarged glands, affected by melanosis from the right groin, and the wound had healed well; and again, seven years before that, Mr. Lawrence, at St. Bartholomew's Hospital, had removed a tumour of three months' growth, from the right hypochondriac region, the scars of which remained.

Since the last operation, that by Mr. Prescott Hewett, tumours had made their appearance in many other parts, and were visible externally as in both groins, the right axilla, the left popliteal and right crural regions, and under the skin of the trunk in various places, although mainly on the left side of the body. The growths in the groin and body were, in places, of a bright purplish hue. When the man was brought into St. George's Hospital, July, 1856, it was found that he had diminished power of movement in the right leg, dragging it after him in walking, and that there was complete loss of motor power in the right arm, hand, and fingers. There was diminished sensibility of the skin of the whole of the right side of the body, that of the left being neither diminished or increased, *and the temperature of the right arm was considerably higher than that of the opposite one. The patient affirmed, that ever since he had been ill, there had been*

increased heat of that side of the body. He also observed spontaneously, that whenever "he gaped, or any thing of the kind," the right (the paralyzed) hand would clench rather forcibly, and again drop when he had finished gaping. All the fingers of the paralyzed hand were much swollen. There was also partial paralysis of the face on the right side, the mouth being drawn to the left, and the right side of the face being expressionless.

There was diminished power of closing firmly the right eye, or moving the alæ of the right nostril, in snuffing the air. There was also slight dropping of the upper eyelid on both sides, which the patient declared had existed for a length of time. No strabismus or spectral illusions existed. Since the last operation, pain, had at times, been complained of, chiefly over the eye, and when this was the case, the patient said he "saw double," and had sickness and vomiting. There was no acknowledgment of twitchings or startings of the limbs, except that on the day before admission, he had several seizures of shaking of the right (the paralyzed) arm, the leg being unaffected.

The speech was very slow and hesitating, and answers given to questions were uncertain. In speaking, the left hand was frequently drawn up to cover the left eye. The tongue, which was clean, was protruded in a straight line. The skin was cool, the pulse regular and quiet, and there was no palpitation, dyspnœa, or cough. The evacuations were natural. Physical examination of the chest elicited nothing indicative of disease. There appeared never to have been any fit or loss of consciousness, but the patient complained that when the agonizing pain came on in the head, he "almost lost his reason." It was stated that the patient's family had, on the whole, been always healthy, but that he had lost a child with some tumour in the belly.

The man was, from time to time, much troubled with vomiting of a green fluid. After a season, the green vomiting ceased, but the food became constantly rejected. On the 26th of July there was very great restlessness, but not any complaint of pain. On the 27th, there was complete ptosis of the left upper eyelid, and he scarcely spoke all day. During the day, without any pain or any distinct attack of convulsions, he suddenly turned purple, and according to the nurse, "made an odd breathing-noise as if he

was getting phlegm up." He vomited a quantity of thick, dark matter, which gave ease to the difficulty of breathing, but in about two hours he gradually got more and more livid, as if strangled, and died.

Remarks.—The history of this man, and the *post-mortem* appearances, present some points of interest.

In the first place, the augmented temperature of the skin of the upper extremity, on the side opposite to that on which the carcinomatous growth existed, is interesting; that on the unparalyzed side, being unaffected. Again, the existence of ptosis on both sides is worthy of observation, whilst the facial paralysis, which was only partial, was on the side of course opposite to that on which was the carcinomatous material; but the ptosis became more interesting when it became more complete on the side corresponding to the tumours, and opposite to the side of the face paralyzed, and this was especially so when it was found after death that the third pair of cranial nerves were in no wise implicated. The existence of diminished sensibility of skin, with loss of motor power in the lower limbs was interesting, pointing to a lesion somewhat high up in the brain; and the œdema of the paralyzed fingers should not pass unobserved, being owing, doubtless, to paralysis of the vaso-motor nerves of this part. The protrusion of the tongue without deviation from a straight line, coincided with the partial character of the facial paralysis.

A very remarkable phenomenon during life was the forcible clenching of the paralyzed hand during yawning, which would immediately drop after the yawning; as also the involuntary muscular motion of the paralyzed arm observed when the patient was about to come to the Hospital and was thereby agitated in mind. The former of these facts is comparable to that first mentioned, I believe, by Abercrombie, of a raising up of the paralytic arm in hemiplegia at each time of yawning. In a letter to the late Mr. Shaw, that physician describes* the case of a man who had not the least power of motion of the left side, except under the following circumstances: — "He was very much affected by

* *Vide* Sir C. Bell on "Nervous System of the Human Body, with Appendix of Cases," etc., 3rd edition, p. 411.

yawning, and every time he yawned, the paralytic arm was raised up, with a firm steady motion, until it was at right angles with his body, as he lay in bed. The arm was raised steadily during the inspiration, and when the expiration began, seemed to drop by its own weight, with considerable force. He continued liable to the affection for a considerable time, and it ceased gradually as he began to recover the natural motion of the limb." This case, Bell adduces, as shewing how independent the automatic respiratory acts are of volitional ones, and as coinciding with the movements of the muscles of the face, shoulders, sterno-mastöid, trapezius, &c., which occur in hemiplegia, through the agency of those nerves which control and combine the muscles in respiration. It is interesting to notice the coincidence of the arm's movement with *in*-spiration.

The agitation of the limbs previous to the patient's coming to St. George's Hospital, was, no doubt, strictly emotional, and seems to be one of those facts from which some physiologists have determined the possible existence of distinct "emotional fibres" in the cerebro-spinal system, apart, either from those which effect the mandates of the will, or from those by which reflex motory actions, truly so termed, are accomplished.

In the above case also, the mode of death, which was sudden and by apnœa, is worthy of observation. It would appear as if the medulla oblongata, and with it the pneumogastric had suffered from counter pressure. Finally, on *post-mortem* examination, the similarity, at first sight, of the growth within the brain to an apoplectic clot, deserves notice. This arose from the fact that much blood had been extravasated into the mass of the carcinomatous growth, but, of course, the microscopical examination at once removed any doubts which might have arisen on this point; and again, the history, the absence of any sudden convulsion or comatose seizure, etc., agreed well with the fact of the comparatively gradual formation of the growth as compared with that of a mass of blood-coagulum. From the history which the patient gave it is not unlikely that the ptosis was the first cerebral symptom which the disease of the brain originated.* Dr. John W. Ogle, *2nd of March*, 1858.

* Since the above case was written, we have had in St. George's Hospital, a

10. *Softening, without Discolouration, of the Spinal Cord, from the Pressure of Strumous Matter; Softening of the central parts of the Brain, and Scrofulous Meningitis, etc. Ptosis, Dysphagia, Vomiting, Double Vision; Partial loss of Sensibility and Power of Motion in the Legs; Deep Coma followed by remarkable return of Consciousness shortly before death.*

The specimen consisted of a part of softened spinal cord, of which portions were exhibited under the microscope. The natural structure was seen to be completely destroyed, but very few fibres of any kind being seen, and those which were present appearing to allow of their contents being squeezed out with unusual ease. A large quantity of granular and fatty matter was observed, and the minute blood-vessels were seen to be very highly diseased, their walls being greatly occupied and studded by oily matter; large compound or granular corpuscles, of oval and rounded form, were also seen.

The part of the spinal cord which had been softened, corresponded to the bodies of the second and third dorsal vertebræ, which were greatly absorbed and surrounded by pultaceous strumous material. This material, besides surrounding the anterior surfaces of these vertebræ, existed in a considerable quantity within the spinal canal, and had, by its pressure, induced the alteration in the cord. The spinous processes of the affected vertebræ projected considerably backward.

The central white parts of the brain, ventricular septum, fornix, and superficial parts of the thalami optici, etc., were much softened, having a yellowish gummy character, and the ventricles contained a large quantity of fluid, by which the surfaces of the convolutions were greatly flattened against the cranium. Moreover, a good deal of yellowish, soft, fibrinous material existed at the base of the brain, corresponding to the floor of the third ventricle, and in masses, matted together, about the optic nerves,

man affected with incomplete hemiplegia, whose paralyzed arm shook vehemently on any emotion being experienced; and whose flexed and paralyzed fingers were extended involuntarily whenever he yawned.—J. W. O.

which were of an unusually firm consistency. At this part, the arachnöid membrane was very opaque and thickened; the olfactory nerves were unwontedly softened.

The lungs were found to contain scrofulous deposit at their apices, and a small vomica was found at the upper part of the right one. Pleural adhesions existed on both sides. The other organs of the body appeared healthy.

History.—The specimen was removed from the body of M. M., æt. 35, who was a cab-driver, but formerly had been a policeman and a boot-maker. He was thin and pale, and was brought into St. George's Hospital in Nov., 1857, and placed under Mr. Cutler's, and subsequently under Dr. Bence Jones's care. He also came under my care whilst acting for Dr. B. Jones.

It appeared that he had been a sober man, and in general good health until five or six years previously, when he became, without apparent cause, subject to pain at the small of the back, and between the shoulders, and a slight numbness of all the body as high as the epigastrium, on getting any cold. Two years previously he had suffered from giddiness at times, and numbness in the legs and loins, with a partial loss of the power of motion in both lower limbs. All these symptoms continued for a year, when he discovered a projection about the lower part of the dorsal region, and since then he had experienced a sensation of numbness over the entire body.

He never had a distinct *fit;* but once he fell down from giddiness on rising from bed, a year before he came into Hospital. During that year he was under treatment in various Hospitals in London, and at Charing Cross Hospital he obtained relief as to pain, from issues established below the dorsal projection. The curvature increased, and he was placed in the Middlesex Hospital.

For the last eight months he had completely lost power of expelling the urine, but there never was any paralysis of the sphincter of the bowels, and the bowels were generally confined.

There seems to have been no family history of phthisis, but the patient had been subject to a cough, and had had one or two attacks of hæmoptysis.

When brought into St. George's Hospital, he had greatly lost power of motion in the legs, but he could walk across his ward,

although with a great deal of trouble. The pulse, bowels, and tongue indicated nothing unnatural, and the patient was treated by general tonics. Restlessness and want of sleep came on about one month after admission, along with some difficulty in swallowing, and in another month frequent and violent headach was complained of. Vomiting and constipation followed. For some days, suffusion of the eyes, and chilliness were complained of, but hardly amounting to distinct rigors, along with want of sleep at night accompanied by frightful dreams causing him to start upright in bed, and drowsiness in the day time. Hitherto, the pulse had not varied much. A sensation of "pins and needles" in both legs as high as the knees was then complained of, and throbbing pain in the temples came on, with vomiting. He also stated, that at times he saw double. The tongue became tremulous and furred. Delirium came on, and slight ptosis of the *left* upper eyelid, but the pupils remained natural, and no strabismus existed. Dysphagia still existed. The light became painful to the eyes, and the temper irritable. The urine contained a large quantity of earthy phosphates precipitated on boiling, and was acid in reaction and dark coloured. Subsequently, it was seen by the microscope to contain blood-corpuscles. Coma came on rather suddenly, and the evacuations were passed involuntarily. Jactitation of the hands, specially of the right one, and clutching of the bedclothes, came on.

After this, he became more sensible, and appeared to recognise his wife, but he could not speak. Eventually, to the great surprise of all, he became quite sensible and conscious, and made signs when he wished to be attended to; still the motions were passed involuntarily. He gradually sank, and died the 29th of December.

As regards treatment, he was at first treated antiphlogistically, but very soon, stimulants with blisters, turpentine injections, etc., had to be resorted to.

Remarks.—In this case, perhaps, the chief point of interest was the fact, that the coma which had come on, left him, and that consciousness was re-established but a few hours prior to death; whilst, however, after death, a considerable accumulation of fluid was found within the ventricles of the brain, and great

softening and disorganization of the central parts of the organ. This appears very much as if the fluid had been in a great part effused immediately before or at the point of death; just as we suppose it happens that effusion occurs into other cavities of the body at this period. Can there have been effusion of fluid, occasioning pressure and coma, and a subsequent resorption of the same so as to have allowed of a return of sensibility, previous to the final struggle when the fluid was again poured forth?

Dr. JOHN W. OGLE, *20th of April*, 1858.

II.—DISEASES, ETC., OF THE ORGANS OF RESPIRATION.

BRONCHIAL AND MEDIASTINAL GLANDS, ETC.

1. *Hydatids expectorated from the Left Lung.*

A youth, W. W., æt. 18, tall, thin, and palish, came under my care on the 17th of October, 1857, in consequence of having had hæmoptysis, a peculiar kind of expectoration, and some cough, the cough being still troublesome.

Except an attack of pleurisy of the left side, nine or ten years before, he had enjoyed fair health; and had not had any constant cough till six months before I saw him, but since then, it had been persistent. Some two or three weeks after the commencement of the cough, he expectorated about a table-spoonful of blood twice in one day, and again the same quantity about a month subsequently; since then, there had only been streaks of blood in the sputa, but the streaks, especially within the last six weeks, had occurred rather frequently. For the six months he had often had pains in the chest, but chiefly in the left side, and more about the mamma and lower parts than elsewhere.

On the 30th of September, he had violent cough for half an hour, it was of a suffocating character, and had a peculiar sound; "you could tell something was different, there was a hoarseness with the cough;" then, quite suddenly, he brought up a thin white membrane, about the size of a florin or half-a-crown, quite empty; this was followed by some puriform expectoration, with

little lumps in it, white, and like "little bits of nuts." No hæmoptysis occurred. He felt easier at the chest than he had done for some time before; but, on the 14th, he again brought up a similar membrane to the one just described, only larger. Subsequently to this event, his cough very materially diminished; and, when I saw him, was only slight; he had also been able to lie on the left side, while, before the expectoration of the second hydatid, he was not able to do so, owing to the pain which recumbency in that position caused.

On examination of the chest, I found the upper part of the left side of the chest much flatter than the corresponding part of the right side, the difference being most marked in the upper part of the mammary region. There was dulness from the apex to the nipple, with bronchial respiration at the apex, and about the mamma some muco-crepitant rhonchus.

The two "membranes" expectorated, were, doubtless, of the same character, but the second one only was brought to me; it was a hytid cyst, ruptured, but had evidently been orginally, from an inch to an inch and a half (if not more) in diameter. Under the microscope, the laminæ of which it was composed, were beautifully distinct. I discovered no echinococci or hooklets, but the cyst, as already stated, was broken, and it had been kept, not very carefully, for three days in water before I saw it.*

Dr. HARE, 20*th of October*, 1857.

---

2. *A Case of Intra-thoracic Cancer, which affected the Lungs and Heart, and projected out of the Chest through an opening in the Sternum.*

This preparation was taken from the body of a man, æt. 23, who was admitted into St. George's Hospital, on the 16th of September, under the care of Dr. Pitman. He had been serving as a marine in the Baltic campaign. There was no history of

* I may add, that since the specimen was exhibited to the Society, the patient has made most favourable progress, and now (June, 1858,) he feels almost as well as ever he did. When I last examined him, there was but a shade of dulness at the upper part of the left lung, and no rhonchus whatever remained.—T. H.

injury to his chest. He had never noticed anything wrong there until March last, when cough came on without any assignable cause, accompanied by pain in the right side, for which he was cupped, with relief. He then noticed a little lump at the right side of the sternum, which increased gradually to the size of a pigeon's egg. He had spat blood on two occasions before admission, and had been complaining for the space of one week of dysphagia, loss of voice, and difficulty of breathing. On admission, a tumour was seen at the upper part of the sternum and towards its right side, which felt almost solid, and pulsated strongly. No aneurismal bruit could be heard, but a systolic murmur was perceived over the tumour and at the base of the heart. His pulse was full and bounding, but there was noticed an inequality in the force of the successive beats at the right wrist. He was a stout well-made man, with a florid complexion; but at times there was some lividity of the features, especially after a fit of coughing. He was much disturbed by the cough and perspired profusely at night; clear breathing could be heard at the back of the lungs, but that of the front and upper part was deficient. The expectoration was frothy and without blood.

It is unnecessary to dwell on the treatment, which was directed to the relief of pain and soothing the cough. The dysphagia and dyspnœa increased, and he died of the latter on the 10th of October.

Post-mortem examination showed a large tumour (half as large as a fist) lying below the pectoral muscle, just below the right sterno-clavicular articulation, of well-marked encephalöid structure. The part which lay above the sternum consisted for the most part of one mass; but there was also a small separate tubercle, which, however, lay so close to it, that it could not be distinguished from it during life. The tumour had completely absorbed the sternum in many places, having apparently made its way from within, as the intercostal muscles were more affected on their deep than their superficial surface. The tumour quite filled the upper part of the chest, and affected extensively both the lungs and the heart. The upper lobe of each lung was quite filled with the morbid deposit, and glued down by it to the pleura and pericardium. The diseased product was extensively infiltrated

into the pericardium, which was firmly united to the heart, and into the muscular wall of the latter. This was especially the case in the right ventricle, the wall of which contained several very large tubercles which projected somewhat into the cavity, encroaching on the aperture of the tircuspid valve, and projecting just below two of its flaps. There were also several scattered tubercles on the surface of the heart.

The aorta, pulmonary artery, and vena cava superior ran through the mass; but were quite pervious, and apparently unaffected. The trachea had been displaced backwards, and had formed a large groove on the back of the tumour; its calibre was not perceptibly diminished; its mucous membrane and that of the bronchi was much injected. The œsophagus was also of course pressed upon, but appeared unaffected by the disease.

Microscopic examination showed a vast number of large oval cells with nuclei, containing granular matter and much fat. There was also some fibrous tissue but in small quantities compared to the number of the cells.

Mr. T. Holmes, *20th of October*, 1857.

---

3. *Fibro-cellular Growth of the Lung.*

The interest of this case lay in the structure of the tumour, its composition being fibrous rather than cellular, and therefore more allied to an innocent than a malignant growth. The clinical history of the case was unimportant, being simply that attending a compression and partial destruction of the lung. The patient was a man, æt. 46, who died in Guy's Hospital in October of the present year. He had much dyspnœa, the left side of the chest was dull and he finally had dropsy. After death, the only disease found in the body was this tumour in the chest; it occupied nearly the whole of the left side, involving and destroying the lower part of the lung, the remainder of this organ being compressed upwards and towards the spine; the root being unaffected. The growth was easily detached from the chest, but was connected with some enlarged glands in the posterior mediastinum. None of the surrounding parts being affected, it appeared as if the tumour had had its origin within the lung

itself. When incised it had not the ordinary appearance of cancer, as it was not opaque and did not emit any milky juice on squeezing, but resembled closely the fibro-cellular or fibro-plastic tumours often removed by the surgeon from the extremities. It was translucent, and in parts had almost a gelatinous appearance; it transuded serum on pressure, and was capable of being torn into long shreds, and thus altogether unlike a simple cancerous formation. The microscope showed its composition to consist mainly of a number of long nucleated fibres lying side by side, also in parts of nucleated cells interspersed, and where this was the case the tumour had a more opaque appearance, and approached somewhat to that of cancer.

Although the surgeon for some time has recognized various forms of growth having various degrees of malignancy among the tumours which he removes from the external parts of the body, yet the same has not been done with reference to internal growths. Mr. Hutchinson has indeed shewn that some instances of so-called cancer of the uterus were in reality recurrent fibröid, and this can be confirmed. The present case exhibits a tumour coinciding in character with these less malignant forms of disease both as regards its anatomical structure, as well as in its mode of development and isolated position.

Dr. Wilks, *3rd of November*, 1857.

---

4. *Oil from the Cavity of the Pleura.*

R. B. W., æt. 58, was last seen in life at half-past six o'clock on the morning of the 18th of October, when his wife left him sleeping quietly; at half-past ten o'clock in the morning, when she again entered his room, he was quite dead. Mr. Hatfield having been summoned, found the body lying on its right side, with the arms firmly fixed over the chest, the face very livid and buried in the pillow. Having been originally in practice as a surgeon he had never had any medical attendant, although he had some years previously retired from the profession, and consequently few particulars could be ascertained regarding his previous state of health. He was alleged to have suffered from gout, and he supposed himself the subject of disease of the heart;

being constantly apprehensive of sudden death, he was in the habit of affixing his name and address on the inside of his coat, and latterly his sleep had been disturbed; he would start up suddenly, exclaiming that he must have died had he not awaked at the time he did. He had suffered for some time past from cough and dyspnœa, and had constant recourse to laudanum and morphia to relieve his sufferings. During the last three weeks of his life he had increased considerably in bulk, but his face did not give the idea of much obesity. He was said to be temperate in his habits, formerly having chiefly drank light French wines, latterly, rarely exceeding a glass of spirits and water in the evening. He was a man of nervous temperament, easily depressed and excited.

Post-mortem examination twenty-seven hours after death.—The body was robust and well-formed, presenting no external marks of violence: the cadaveric rigidity was passing off and decomposition proceeding with extraordinary rapidity. Having remained in the semi-prone position in which he was found, the lower part of the face had become very greatly distended and perfectly black, and a fœtid, frothy discharge issued from his nose and mouth. The anterior parts of the trunk and limbs were also discoloured, and the cuticle in many places raised by infiltration of bloody serum: the scrotum and penis were enormously distended with similar infiltration, and like the face, quite black. In making the first incision through the integuments the cuticle was detached from the skin, much fœtid gas was given off, and a quantity of oil flowed from the cut surfaces in such an amount that it had to be taken up with a sponge; when the sponge was squeezed into a basin of cold water, the oil floated on its surface and quickly solidified.

When the pectoral muscles were reflected, the intercostal spaces on the right side were observed to bulge in such a manner as to convey the impression that empyema or hydrothorax existed on that side. One of the projecting spaces was transfixed, giving vent to a quantity of fœtid gas; and this was followed by a jet of clear oil which was projected to a height of two inches, flowing away over the neck and shoulder of the corpse, and the floor of the room. The whole quantity was estimated at five or six

ounces, and about an ounce was caught in a bottle as it flowed from the opening in the chest; this very soon became opaque and solid, and exhaled a fœtid odour. The right lung was found in many parts firmly adherent to the pleura: the hand passed into the cavity to detach these adhesions became covered with oil. The lung was much congested and feebly crepitant, but floated in water.

The left lung was almost wholly free from adhesion; it was pale and crepitant throughout. No oil was observed in the left pleural cavity.

The heart was exceedingly pale, flabby, and collapsed: there was a large quantity of fat at the base, from which oil flowed on incision; the walls were thin, the valves healthy, and all the cavities empty, and there seemed to be no blood in the venæ cavæ.

The peritoneal cavity was distended with fœtid gas, and the serous surfaces saturated with oil. The stomach and intestines were greatly distended, and their coats crepitant from decomposition. The stomach contained some cheesy-looking substance but very little fluid, the mucous membrane was not congested, and the contents were subjected to the tests for morphia and prussic acid, but with negative results.

The liver was large and perfectly black, it broke down readily on slight pressure, was crepitant from decomposition, and floated in water. The gall-bladder contained a very small quantity of thin bile. The kidneys were healthy in structure, the right one containing more blood than the left.

The scalp was remarkably hard and unyielding, but presented no appearance of injury; no blood escaped when the skull was removed. The membranes and surface of the brain seemed healthy; its substance was remarkably bloodless, but so much softened, apparently from decomposition, that it could not be removed entire; a little blood-stained serum was found in the ventricles.

Dr. Barclay for Mr. Hatfield, 17*th of November*, 1857.

---

5. *Ulcer of the Larynx in Typhöid Fever, producing general Emphysema.*

A lad, æt. 12, was admitted under Dr. Addison's care into

Guy's Hospital, November, 1857, with typhöid fever; the symptoms were well-marked, and the case was altogether a more than usually severe one. About the twelfth day of his illness, the neck was observed to be emphysematous; and, after a few hours, the face, chest, and arms were in a similar condition: this state lasted for ten days, when the boy died, during which time he was nourished by enemata, being scarcely able to swallow. Considerable interest was evinced as to the nature of the lesion which had given rise to this escape of air, and the general impression was, that an adherent portion of lung had sloughed, and allowed the passage of air through the costal pleura. Only one physician had seen a similar case. It appeared, however, not to be unprecedented, for various authors have given instances of its occurrence; and it had also been observed in the Crimea, although the army surgeons had failed to find a cause for it, and the subject was, therefore, still in obscurity.

The *post-mortem examination* of the present case, revealed the ulcerated intestine and other well-known appearances of typhöid fever, and, besides these, a sloughing ulcer in the larynx. At the back part of this organ, at the junction of the vocal cords, was a hollow space the size of a large pea, which was cut in two by the incision. On the left side, a probe passed through this cavity into a space between the trachea and œsophagus; in this was some purulent mucus, proving the communication which had existed during life. The air had thus penetrated into the posterior mediastinum, and thus by the thoracic walls to other parts of the body. This perforation was evidently the cause of the emphysema, and was thus regarded by those who witnessed the inspection; they, however, thought that the disease was a mere coincidence of the fever, and dependent on some accidental cause. Probably this was not so, for many pathologists have described an ulceration or sloughing of the larynx as a part of the typhöid process. Rokitansky, as a morbid anatomist, and Huss, as a physician, have noted the fact (*laryngitis typhosa*), as well as surgeons, and have stated fever to be one of the causes of chronic laryngeal affections which come under their notice. This seems sufficient evidence to prove that this organ is sometimes affected; now, if this be the case, and at the same time it

is true that emphysema occasionally occurs in fever, it is more than probable that these two conditions stand in the relation of cause and effect. There was no doubt that such was the case in the present instance, and therefore, although it would be unwise to speak presumptuously from a solitary instance, yet the specimen, probably, does afford an explanation of an occurrence which sometimes happens in the course of typhöid fever.

Dr. WILKS, *15th of December*, 1857.

---

6. *Epithelial Growth from the Larynx.*

J. C., æt. 52, a rather tall, spare man, of healthy family, presented himself at the Hospital for Consumption, during my absence in May, 1857. For five years he had suffered from partial aphonia and slight cough, with scanty, viscid expectoration. The respiration was considered healthy, with the exception of some slight bronchial rále, and the case was looked on as one of chronic laryngeal irritation.

Towards the end of June, I myself examined him. He had then considerable and increasing dyspnœa, present at all times, but frequently exasperated into violent and sudden fits of gasping. These attacks occurred without warning, often without exertion of any kind, and frequently when in bed. There was also occasional dysphagia. He complained of pain, principally in the back of the neck and between the shoulders, of a shooting character.

The physical signs consisted in a great deficiency of respiration over both sides of the chest. The chest walls were contracted and emaciated, the percussion note uniformly good. No impulse nor murmur could be detected in any part of the chest; the radial and carotid pulses were equal. No external venous distension existed.

There was nearly complete aphonia, the voice never recovering its tone. The nature of his dyspnœa was of a character difficult to describe, but impressed me strongly with the conviction that it was due to pressure on the larger air tubes; and the diagnosis appeared to point to aneurism or tumour of some sort at the root of the lungs. Had the observed deficiency

of respiration been one-sided, this diagnosis would have been materially strengthened; but the supply of air was uniformly diminished to both lungs, and the absence of any other sign of tumour in the chest led us to think that the obstruction was higher up.

The treatment—which consisted of sedatives, as stramonium and conium, chloric æther and anti-spasmodics, and blistering to the larynx—was entirely ineffectual in relieving him. The application of the nitrate of silver to the uvula and about the epiglottis, caused a violent fit of orthopnœa, which lasted for some hours. For the last fortnight he was confined to bed, and under my private care; and my impression of the cause of the dyspnœa being mechanical pressure, was strengthened by very minute examinations.

He died on the 6th of December, having had a series of fits of violent dyspnœa for twelve hours before his death, till within the last few hours, when he sunk into a quiet somnolent state; and he died without a struggle, and with intellects unimpaired to the last.

Post-mortem examination.—A careful examination of the chest and larynx was made, thirty-six hours after death, with the assistance of Mr. Ford. There was no tumour of any kind in the chest. The lungs were healthy, with the exception of the usual congestion of the mucous membrane due to bronchitis, and that they were atrophied. The heart was small, walls thin, valves healthy. Finding there was no obstruction to the entrance of air to be found in the chest, we naturally looked higher up.

The larynx exhibited the appearances now seen in the specimen. A granulated-looking mass, of a soft pultaceous consistence, occupied the upper part of the larynx immediately within the rima, and apparently arising from the anterior wall and the arytenöid cartilages, completely obstructing the entrance of air. Its size might be as large as a walnut. The epiglottis was hard, rough, erect, and pale, and not involved in the growth described. The mucous lining of the larynx and trachea was highly congested. The thyröid and cricöid cartilages, are both, more or less, ossified, and we had remarked that the cartilages of the ribs were also completely converted into bone, necessitating the use

of the saw in opening the chest. No enlargement of the cervical glands had taken place.

On microscopical examination, the tumour appears to offer a specimen of epithelial cancröid growth, resembling that exhibited by Dr. Hawkesley, recorded in vol. viii., p. 88, of the Society's "Transactions." It consists of an abundance of epithelial cells, compressed together, among which are found some few nucleated and elongated.

A practical question arises out of this case. Viewing the obstruction to respiration as of a mechanical nature, would any surgical interference, as opening the trachea, have been justifiable? In the specimen it will be seen that complete closure of the larynx had occurred, while the lungs were comparatively healthy. The patient died of apnœa, and its wasting results on the system. He did not die of the cachexy of malignant disease. Should the question arise in practice, the following must form the data for our decision:—Complete evidence that the obstruction is not seated within the chest, but above the trachea:—the non-existence of cachectic wasting to any severe extent, and the integrity of the rest of the respiratory apparatus.

Dr. Pollock, *5th of January*, 1858.

---

7. *Tuberculous Abscess of the Anterior Mediastinal Glands, bursting into the Trachea.*

This specimen was from an infant, aged five months and a half, the offspring of a phthisical father, the mother being apparently healthy. From two months old, he was noticed to have a slight husky cough, for which, at the age of three months, an application was made to his throat with a sponge probang on two occasions, immediately after the last of which, symptoms of croup came on; he was then placed under the care of a homœopathic practitioner during three weeks, without any relief to the symptoms.

I saw him first on the 7th of November, suffering with impeded respiration, hoarseness, and sonorous cough, but no mucus in the throat. Leeches, antimony, and calomel were carefully employed for a short time, but with only partial relief. The

symptoms continuing after a month, the propriety of performing tracheotomy was well considered, but the idea was abandoned by the advice of Dr. Fuller, who suggested that there was a tumour pressing on the lower part of the trachea.

Three weeks before death, and on several subsequent occasions, a little purulent fluid was coughed up; he continued to suffer much distress until the 2nd of January, when he died rather suddenly.

Post-mortem examination shewed in the anterior mediastinum a mass of tuberculous glands, and an abscess the size of a pigeon's egg containing softened tuberculous matter, which communicated with the trachea through its anterior wall, by a ragged opening half an inch in length, the mucous membrane around and above, for some distance being much ulcerated. The larynx and the tracheal mucous membrane below it, for the space of more than an inch, appeared quite healthy. The pharynx contained a good deal of purulent fluid, such as was found in the cavity of the abscess. Both lungs were entirely studded with masses of tubercle, the pleuræ on the right side being adherent.

The right side of the heart was distended with dark, semi-coagulated blood, thus confirming the suspicion that the child died of asphyxia, caused by a large quantity of the contents of the abscess being discharged into the trachea.

Mr. Thomas Ballard, *5th of January*, 1858.

---

8. *Epithelial Cancer of the Larynx, with Extension of the Disease to the Œsophagus, for which Tracheotomy was performed, twelve months before death.*

M. T. N., æt. 62, applied to Mr. Debenham, Surgeon, of Stepney, early in October, 1856, complaining of hoarseness, laryngeal cough, difficulty of breathing, and inability of speaking above a whisper, which symptoms had troubled him, more or less, for nine months. There was no history of syphilis, but he had been very much exposed to the weather. The case being viewed as one of chronic laryngitis, the patient was put slowly under the influence of mercury, and the throat was repeatedly blistered. Iodine was afterwards applied externally, and iodide of potassium taken internally for a considerable period.

Lastly, a seton was inserted over the thyröid cartilage, and retained, for some weeks, but with no good result; and by the middle of December, his cough was incessant, his breathing much laboured, his lips and fingers of a blueish tinge; he was daily and rapidly losing flesh and strength, he obtained scarcely any sleep, and was quite unable to leave his bed. Although his life was not immediately threatened, it was evident he could not hold out many days with the imperfect supply of air he was able to obtain. Under these circumstances, Mr. Debenham (to whom I am indebted for these particulars of the case), recommended tracheotomy, and I was requested, on the 19th of December, 1856, to meet him in consultation, when I at once sanctioned and performed the operation, and inserted a silver tube into an opening made in the upper part of the trachea. The relief was most striking; the cough ceased immediately, the patient speedily gained flesh and strength, and, four months after the operation, was capable of walking several miles. Shortly after the operation, the tube was fitted with a valve opening inwards, which admitted of the patient's inspiring through the tube, and expiring through the glottis, and thus enabled him to speak as well as he was capable of doing previously. But the disease in the larynx evidently continued to increase. He was not able to employ the valve longer than a few weeks, and, in the May following, the use of it even for half a minute caused him intense distress, clearly showing increasing obstruction in the larynx, and how entirely his life was dependent on the artificial opening. About five months before death, it was observed that the throat had become more bulky externally, and that there were several enlarged glands under the jaw. He complained too, of severe lancinating pain, with occasional difficulty in swallowing. According to his wife's account, the latter symptom did not become distressing until about a fortnight before death, and he was capable of taking fluid nourishment to the last. He died on the 24th of December, 1857, apparently from exhaustion, for he sunk quietly, undisturbed by dyspnœa.

The parts involved in the disease of the throat were removed by Mr. Debenham, twelve hours after death, and kindly sent to me for examination. The upper opening of the larynx was a

mere chink, which would only just admit the handle of a scalpel. There was a free opening in the upper and front part of the trachea, the result of the operation. The larynx and trachea were laid open by section through their posterior walls. The following are the appearances presented from above downwards: —The glands, at the base of the tongue, are much enlarged, and some of them ulcerated. The mucous membrane, at the root of the epiglottis, and at the upper part of the pharynx, are much increased in vascularity, and in the latter region, the epithelial coat is thickened and opaque. The epiglottis is large and hard. Its base in front is studded with enlarged glands. From the upper border of the ventricle to the lower border of the cricöid cartilage, the interior of the larynx is occupied by a reddish and greyish-white, soft, friable, cauliflower-looking growth. A narrow strip of tolerably healthy-looking mucous membrane intervenes between the lower border of the growth and the upper border of the opening formerly made in the trachea. The mucous membrane surrounding the opening, is coated with a membraniform layer, about a quarter of an inch in thickness. From the lower border of the cricöid cartilage, the morbid growth is continued downwards and backwards, between the trachea and œsophagus, and opens into the latter opposite the third tracheal cartilage, by means of a small ragged ulcer. It will thus be seen that the morbid growths pass from the upper and front part of the larynx, downwards and backwards, into the œsophagus, leaving the trachea, except at its upper and back part and around the margins of the artificial opening, free from obvious change. Through the deep fissures in the upper part of the growth, the sharp edges of the broken and ossified thyröid cartilage could be felt. At the lower part on each side projected the naked extremities of the cricöid and upper tracheal cartilages. The mucous membrane of the lower part of the pharynx, and of the upper part of the œsophagus, was of a dead-white colour, thick, wrinkled, and spotted at intervals, with small, circular, slightly elevated patches, as if drops of melted wax had fallen upon it and solidified.

From the history of the case, and the appearances on dissection, I conclude that the disease consisted originally of warty, or epithelial growths, which subsequently assumed a cancerous

action, and this view is confirmed by Dr. A. Clark's minute examination of the morbid structures given below.

Mr. B. Curling, *5th of January*, 1858.

Report on the above specimen.—Preliminary minute examination.—The morbid growth has a well-marked warty or cauliflower-form where it has not been much handled, particularly in the ventricle and pouches of the larynx. The warty masses are thinly studded with papillæ, constricted at their bases and bounded by deep ragged fissures, containing a curdy-looking fluid. The free surfaces of the warty masses and their papillæ are covered with thin whitish desquamating flakes. Beneath the surface these masses appear dry, white, friable, obscurely granular, and studded with minute rounded openings from which a soft white material readily oozes upon pressure. Still deeper and close to the subjacent healthy structures the morbid growth is softer, less friable, of a reddish-white colour, granular, and infiltrated with an opalescent fluid which is coagulated by water into curdy flakes.

The mucous membrane of the larynx, where free from obvious invasion of the new growth, is increased in vascularity; its epithelial coat is much thickened and the epiglottidean, arytenöid, ventricular, and adjacent racemose glands are greatly enlarged and mostly opaque. The mucous membrane of the lower part of the pharynx and upper part of the œsophagus is also increased in vascularity; its epithelial coat is very greatly thickened and capable of removal in the form of a granular-looking membrane; the œsophageal glands are much enlarged, and their orifices filled with an opaque white deposit.* These changes in the laryngeal, pharyngeal, and œsophageal mucous membranes, are most marked in the immediate neighbourhood of the new growth in the larynx. The exposed cartilages are of a yellowish-brown colour, dry, and brittle.

* Small white circular flattened patches, like drops of solidified wax, are scattered over the mucous membrane, in the neighbourhood of the ulcerous communication with the larynx. They appear to be in the sub-mucous areolar tissue; but are really embedded in the hypertrophied epithelial coat, and capable of being removed with it without injury to the subjacent surface.

Microscopic examination. — A. *The structural elements of the New Growth.*—Examinations of the juice, scrapings, and sections of the morbid growth, conducted in various ways, shews that it is composed of the following structural elements, combined in different ways and degrees at different parts:—

1. Proteine and fat granules in considerable abundance.

2. Fibröid tissue in bands and areolæ.

3. Free nuclei of two kinds. Firstly, oval, vesicular nuclei, with single, sharply defined outline nucleoli and granules (Plate II. Fig. 4*a*). Secondly, spherical, vesicular nuclei, with double outline, and containing fluid and granules (Fig. 4*b*).

4*a*. Cells resembling those of old squamous epithelium, but differing generally in regard to their outline and their nuclei. The outline in some of the cells is normal: in the majority it is very irregular, being projected into variously formed processes (Fig. 5*a*) prolonged into poles (Fig. 5*b*) or settled into irregular squares. The nuclei are changed in almost all the cells; they are increased in size, vesicular, granular, have a sharply defined single or double outline, and are surrounded by a more or less broad, clear space. Some of these cells contain several nuclei (Fig. 5*c*); some exhibit vacuoles or spaces containing granular nuclei (Fig. 5*d*) or secondary cells (Fig. 5*b*); others are entirely occupied by vacuoles containing only fluid, and measuring one-hundreth part of an inch in diameter, representing true cysts (Fig. 5*e*).

4*b*. Fibre cells with large vesicular nuclei, few in number (Fig. 6); nucleated fibres, more numerous and derived from the blood-vessels.

c. Compound granule cells (Fig. 7).

d. Large cells resembling those commonly found in fully developed encephalöid cancer;—spherical, oval, or pyriform, with sharply defined, single or double outline, and contained secondary cells, or vesicular nuclei floating in an albuminous fluid (Figs. 5*b*, 8, 9*a*, *b*).

e. Nest cells or laminated capsules, of at least four kinds:—First kind consists, apparently, of a single pyriform cell, containing several nuclei or secondary cells in a vacuole, the margins of which have become fibrillated (Fig. 10*a*). Second kind con-

sists, apparently, of super-imposed flattened cells of different sizes (Fig. 10*b*). Third kind consists of a number of central cells, surrounded by flattened epithelial cells (Figs. 10*c*, *d*). Fourth kind consists of a number of central nucleated cells, surrounded by areolar tissue (Fig. 10*e*).

f. Ciliated cylindrical epithelial cells much enlarged, constricted about the middle, and having usually two oval vesicular nuclei (Fig. 11*a*).

B. *Mode of arrangement of the structural elements.*—The simpler cells (Figs. 11, 11*b*, 5*a*, 5*c*, 5*d*, 6, 10*b*) occupy the surface of the new growth, and are unaccompanied by any fibrous tissue or juice. The deeper parts of the tumour alone contain the juice, the free nuclei, the broad cells and the laminated capsules, and the granule cells. On the surface the cells are arranged without definite order into super-imposed laminæ which are here and there perforated by rounded openings (openings of racemose glands?).

In the deep parts of the growth its structural elements are arranged in a special and notable manner. They are contained in areolar spaces formed of abundant and perfectly healthy areolar tissue, which contains none of the cell elements above described in its meshes, except at certain points about to be noticed. The areolæ have the shape, size, and arrangement of those which surround the racemose glands of the part in health; and the cell elements are arranged in these areolæ in the form of racemose vesicles similar to the normal ones in all respects but their contents. At some parts indeed, the resemblance is complete, for the vesicles and the tubes leading from them contain scarcely any pathological cell-forms, and are lined by the normal epithelium.

When the abnormal contents of the areolæ are turned out, they exhibit the appearance illustrated by Fig. 10*e*. In the deepest parts of the growth, and in the neighbourhood of the carious cartilages the abnormal cell elements have escaped from the areolar spaces, and become infiltrated into the surrounding areolar tissue.

C. *State of the adjoining parts.*—The mucous membrane at the tip of the epiglottis exhibited a healthy condition of its

epithelium and follicles, which for the sake of comparison is illustrated by Fig. 12.

At the base of the epiglottis and in the seemingly unaffected parts of the mucous membrane of the larynx, the layers of epithelium are increased in number and its component cells changed, and the follicles are enlarged and occupied by a morbid growth. In these localities there are as many as fifteen layers of epithelium. Some of the cells are distorted in form, and their nuclei are vesicular, granular, and surrounded by broad clear halos. The follicles in the same situations are enlarged; their orifices are surrounded by layers of flattened nucleated cells, which, seen edgewise, look like fibres; and their cavities are filled by cells resembling the simpler forms found in the morbid growth (Fig. 13). Sections of these follicles represented nest cells (Figs. 10*c*, 10*d*.) as figured Nos. 17 and 18. The same general conditions are found in the epithelial coat and follicles of the œsophagus. In the circular, opaque flattened patches, embedded in the epithelial layers of the œsophagus, and quite unconnected with the sub-mucous areolar tissue, are found the same structural elements as those forming the morbid growth, with the exception of the free nuclei, granule, and brood-cells (Figs. 8, 9*a*, and 9*b*).

Conclusions.—I consider that the above growth must be classed under the head of what is provisionally termed "Cancer," from the subjoined correlation of facts: the presence of a numerous free vesicular nuclei, and of an almost infinite variety of simple and compound cell-forms; the formation of vacuoles, and the evolution of reproductive granules; the occurrence of active endogenous development in the majority of the cells; the association of these changes with the infiltration of much albumen and fat; and the general development of the growth at the expense of adjacent structures, partly by transformation, and partly by disintegration.

I further consider, from the seat of the growth and the prevailing character of its component cells, that it must be referred to that subdivision of cancers, termed epithelial. The growth appears to have arisen in the epithelium, and in the follicles of the affected part, and to have been confined to them in the early period of its development.

I ascribe the origin of the growth to a direct transformation of the involved textures, and not to any free cell development in an exuded blastema, which I believe it never obtains in the evolution of any cellular-growth whatever.

The history of this specimen illustrates two other pathological facts worthy of notice:—1. That a vacuole may form in a cell, and with the cell enlarge to such an extent as to represent a true cyst (Fig. 5*a*). 2. That the so-called nest cells are often merely sections of hypertrophied papillæ, follicles, gland vesicles or their contents. They are certainly not characteristic of epithelial cancer, as I have fully demonstrated elsewhere.

Dr. ANDREW CLARK, *5th of January*, 1858.

---

9. *Gangrenous Cavity behind the Root of the Lung, opening into the Left Bronchus and Œsophagus.*

P. M., a gentleman in reduced circumstances, was admitted into St. Thomas's Hospital under my care, on the 4th of June, 1857. He had ordinarily enjoyed good health, but twenty years previously vomited a large quantity of blood. About five months before admission he began to be troubled with pain in the front of the chest increased by exercise, and with difficulty of breathing and slight cough, accompanied by little or no expectoration. All these symptoms increased steadily, in spite of treatment; the pain became more severe and constant, the cough more troublesome, the expectoration more copious, though never abundant; and the dyspnœa got more intense, without, however, amounting to anything like orthopnœa. During two or three months of this time he attended my Hospital out-patient practice, but I was never able to detect any signs of thoracic disease, beyond slight occasional irregularity in the heart's action, without murmur, and the ordinary indications of mild bronchitis. During the greater part of this time he slept well, his bowels were regular, and his appetite was good, but the latter fell off during the last month.

Nine days before admission he experienced, for the first time, pain in swallowing solid food, which he referred to the upper part of the larynx. This continued till the 1st of June, when difficulty in swallowing fluids was superadded; and the day after

he found himself totally unable to take either solids or liquids, any attempt to take the latter more particularly, being peculiarly distressing.

June 4th.—Experiencing no amendment, he became an in-patient. The symptoms at this time, and for the next three or four days, were precisely those described above. He was totally unable to swallow, though exceedingly thirsty and not altogether devoid of appetite; his tongue was clammy and white, and he complained of a foul taste in his mouth. Ordered: half a grain of opium every six hours; to have a pint of strong beef-tea, as an enema, night and morning, and occasional injections of milk during the day.

June 9th.—Is very weak, but retains the injections, and appears to have derived some benefit from them. His thirst is much diminished. Pulse regular, weak, and rather rapid. Still quite incapable of swallowing any kind of food, although he manages to take the small opium pills. To-day I made him attempt to take some milk in my presence. He first took a tea-spoonful, and performed the act of deglutition in a perfectly healthy manner; but in about a couple of seconds, and at the moment when he was about to repeat the dose, he was attacked with a violent spasmodic fit of coughing, which lasted for some little time, and ended by his bringing up what he had swallowed, in a frothy condition and mixed with mucus. There is no tenderness or swelling about the larynx or trachea, and, on looking down the throat, the fauces, looked healthy; and the epiglottis, which is distinctly seen, looked perfectly healthy. The cough has become much more severe since he has been unable to swallow; the paroxysms are now very frequent, and he expectorates a large quantity of yellowish-brown, slightly tenacious mucus, which, together with his breath, yields an offensive gangrenous odour.

June 11th.—Decidedly weaker. Pulse 100, irregular. Still thirsty, and unable to swallow. Tongue covered with a thick, whitey-brown fur; fauces, healthy-looking. Retains his injections; bowels open; sleeps fairly. Cough troublesome; breath fœtid; expectoration copious and puriform. Anterior part of the chest resonant, with, here and there, a little rhonchus and subcrepitation; upper part of the chest behind, resonant, lower part

duller than natural. Lower half of the left lung decidedly dull, and markedly more so than the corresponding portion of the right. There is considerable deficiency of vocal fremitus over this region; the inspiratory sounds are scarcely perceptible; and near the spine, a little below the angle of the scapula, the expiration is distinctly amphoric and the cough accompanied by a splashing sound. There is some rhonchus and sub-crepitation over the other portions of the chest. Heart's sounds, healthy.

June 12th.—Very much worse. Excessively feeble and short-breathed; pulse irregular, about 140. Did not sleep last night. Has a very severe stitch in the left side, for which a mustard poultice has been applied. This pain has been coming on for the last three or four days. Cough troublesome, expectoration and breath fœtid. A bougie was passed carefully, for the sake of ascertaining whether any obstruction existed in the course of the œsophagus; and, none being detected and no ill effects produced, it was decided that he should have beef-tea, with two glasses of wine, administered twice a day, by means of the stomach-pump.

June 13th.—He was fed yesterday, and again this morning by means of the stomach-pump, yet his weakness increased; he sunk gradually, and died about half-past 10 A.M.

Post-mortem examination.—The body was much emaciated.

Chest.—There were a few adhesions at the posterior part of the right pleural cavity; and, here and there, on the lower part of the visceral pleura, were thin films of recently deposited lymph. The right lung was large and heavy, and slightly emphysematous at both apex and base; it was crepitant, though sparely so, in the greater part of its extent. A considerable portion of its upper lobe had a dark-greenish hue, and a fœtid smell. In the lower lobe was a large mass of blackened, indurated, yet slightly crepitant tissue, which had evidently been produced by by-gone disease; together with several smaller patches, which were also slightly crepitant, but at the same time palê, granular, lacerable, and solid. The pericardium, for the most part, was healthy; but, immediately below the point where the pulmonary veins open into the auricles, was a small patch, in which the membrane was softened, discoloured, and covered with a little lymph. The heart was pale

and flabby; there were a few nodules of earthy matter in the base of the aortic, and a little atheroma on the mitral valve, but both were competent. On opening the left pleural cavity, the corresponding lung was found to be invested, and slightly attached to the parietes, by a layer of soft lymph, which had a yellowish colour, and varied in thickness in different parts. On removing the lung, a gangrenous cavity, about as large as a hen's egg, was discovered immediately behind the root of the organ, between it, the œsophagus, aorta, and heads of the adjacent ribs. The parts were removed in mass, and, after careful examination, the cavity was found to be essentially external to the lung, though the pulmonary surface, in contact with it, was partly destroyed and in a sloughy condition. The terminal portion of the left bronchus, and the commencement of two or three of its first branches, were destroyed posteriorly to the extent of half their circumference, and opened freely into the cavity by a branching orifice, which was altogether about half a square inch in area, and of which the margins were irregular and studded with projecting fragments of denuded cartilage. On laying open the œsophagus, this tube was found to communicate with the gangrenous cavity by a longitudinal slit, about an inch and a half in length, situated halfway between the front and the left side. The orifice looked as though it had been formed by laceration; for the mucous membrane in its neighbourhood was not discoloured, and the margins of the perforation were thin and more or less shreddy. The muscular coat, however, in its neighbourhood had been partially destroyed, and had contributed to form the parietes of the cavity. The aorta was partially surrounded by the abscess, and took part in the formation of its walls, but its own did not appear to be materially injured. The left lung was large and heavy; its upper lobe was crepitant, though sparely so; its lower contained scarcely any air, was nearly solid, lacerable, and had a somewhat greenish tinge; and the bronchial tubes connected with it were almost completely filled with purulent fluid. The larynx, trachea, and right bronchus were healthy, except that their mucous membrane was more or less congested, and, towards the lower part, of a greenish hue. The lining membrane of the left bronchus was thick and much discoloured. Situated between

the two bronchi were numerous large, black, soft, and, in some instances, pulpy bronchial glands; and, from the position of the gangrenous abscess, there seems every reason to suppose that it had had its origin in some of these diseased bodies. Placed behind the left bronchus, it had, at all events, clearly originated in that situation, and had only secondarily affected the lungs, bronchial tubes, and œsophagus. The œsophagus was healthy, except at the point of perforation. All the abdominal viscera were healthy.

I need scarcely say, that during the first two or three months that the patient was under my care, I was unable to come to any conclusion as to the nature of the disease under which he was labouring. But the remarkable symptoms which he exhibited during the nine days he passed in the Hospital prior to death, clearly indicated the character of the mischief that had been going on during the last three weeks of his life. Though, whether his earlier and his later symptoms depended on the same cause, or on different ones, was not yet apparent.

The gangrenous odour which attended the breath and expectoration, pointed unmistakably to gangrene in connection with the lungs; the choking sensation which followed, at an interval of two or three seconds, the act of deglutition, and which was succeeded by the expectoration of the food that had been swallowed, pointed with equal certainty, to a communication between the œsophagus and the trachea, or one of the larger bronchial tubes; and the well-marked cavernous breathing between the left scapula and the spine, over the root of the left lung, clearly indicated the presence of a cavity in that situation, and rendered it more than probable that this was the seat of gangrene, and the spot in which the communication between the œsophagus and air passages had been established. The *post-mortem examination* shewed the correctness of this view; but it shewed also that the gangrenous cavity, though it had eroded the lung, was essentially external to it, and from its position, that it had originated in softening, and probably, suppuration, of some of the bronchial glands; an inference which was strengthened by the existence of disorganized glands in the neighbourhood.

As there was no appearance of visceral disease, beyond what has just been commented upon, and nothing else which could

BOSTON MEDICAL
APR 1) 40
LIBRARY

possibly account for the obscure symptoms of which he had complained during the earlier period of his illness, it seems fair to assume that his symptoms were caused by the disease, which was going on in the bronchial glands;—a disease, which, from its position, would be little likely to give any positive indication of its presence, until either it had become unmistakable by its bulk, or had involved (as in the present instance) neighbouring organs of greater and more vital importance than those which were primarily affected. Dr. J. S. Bristowe, *2nd of February*, 1858.

---

10. *Remains of a Pleural Abscess.*

This specimen is a rare one, and of interest, because it demonstrates the fact of the spontaneous cure of abscess of the pleura.

The man from whom it was taken, died of disease of the heart.

Lign. 2.

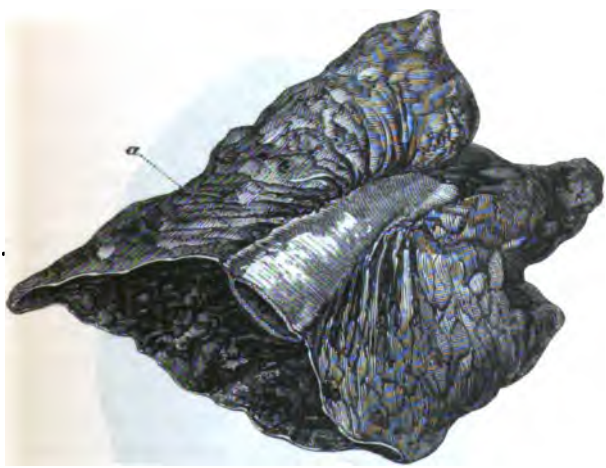

The figure (from a drawing by Dr. Sieveking) represents a section through the abscess (*a*), near its lower extremity, with its attachments.

The specimen, which manifestly represents the dried and shrunken walls of a pleuritic abscess, consists of a closed cartilaginous-like tube, about five inches long, and one inch broad;

its walls are about one-twelfth of an inch thick. When cut across it resembles very closely a flattened aorta. It contains no fluid matter. The hardish, gritty particles scraped from its roughened inner surface, consist chiefly of cholestearine and granular matter. The contracted tube is firmly attached to and embedded in the pleura, being fixed in it, down along the outer side of the left lung. Fine thickened bands of pleura radiated from its borders over the lung, indicating the fact of its contraction. The lung itself has recovered from the compression to which it must have been once subjected by the abscess. From its situation, it may be supposed that the abscess had been encysted.

Dr. MARKHAM, *2nd of March*, 1858.

---

11. *Tubular Cast of the Trachea, at its Bifurcation.*

The patient, a strumous-looking boy, æt. 3, expectorated the

LIGN. 3.

* The figure represents the cast of the natural size.

DESCRIPTION OF PLATE III.

Figures 1 to 4 illustrate Dr. Peacock's cases of Expectoration of Fibrinous Casts from the Bronchi, p. 53.

Fig. 1*a*. Represents two portions as usually voided, in the form of rounded pellets.

Fig. 1*b*. Some of the above portions expanded, shewing their branched character.

Fig. 2*a*. Delicate fibrillated tissue, the chief component of these casts. 2*b*. Blood-corpuscles, more or less altered. 2*c*. Mucus cells from the minute twigs.

Fig. 3. Two views of a mass expectorated, of a kind less commonly met with.

Fig. 4. Microscopic structure of the latter;—imperfect fibrous tissue, numerous ill-formed cells, nuclei, much granular matter, and oil.

Figures 5 and 6 illustrate Dr. Peacock's case of Malformation, probably Congenital, of the Aortic Valves, p. 63.

Fig. 5. The valves seen from the upper or aortic side.

Fig. 6. View of the same from the lower or ventricular side.

Fig 1

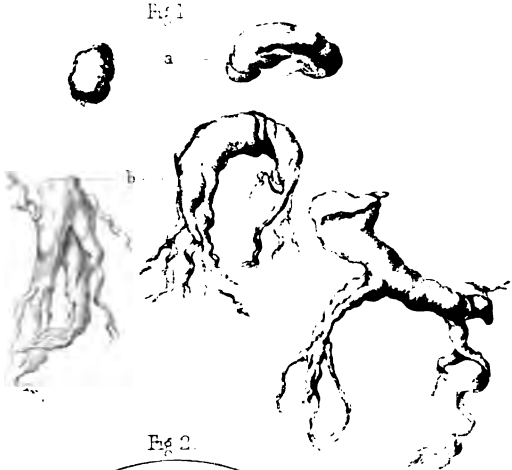

Fig 3

Fig 2

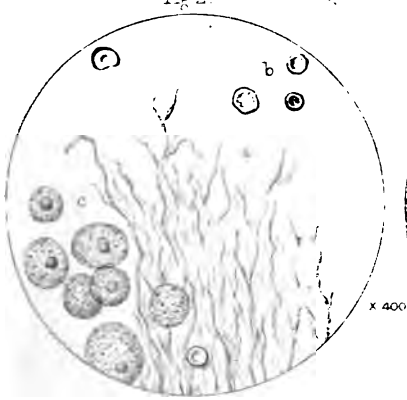

Fig 4

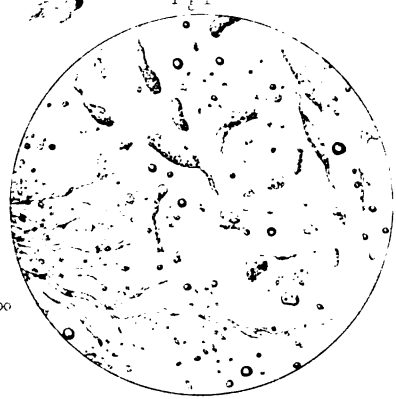

Fig 5

Fig 6

Tiffen West on nat. del et sc

W West imp

cast on the fourth day of an attack of modified croup. Notwithstanding its removal, his illness terminated fatally on the following day. No *post-mortem examination* was obtained. The cast (Lign. 3) was a tubular one, and forked, having evidently been moulded in the bifurcation of the trachea. The child's illness had commenced with a sore throat, and the exudation of a white coating on both tonsils. Throughout there had been but little cough. The embarrassment of breathing had never been extreme, nor had the fever run high. In these respects, the case had differed markedly from what is usual in true croup. Antimonial salines and emetics had been the chief remedies employed, and it was during the action of one the latter, that the cast was expelled.

Mr. HUTCHINSON for Mr. B. ROBERTS, *4th of May*, 1858.

---

12. *Fibrinous Casts of the Bronchial Tubes Expectorated.*

The specimens exhibited, were expectorated by a man, attending as an out-patient at St. Thomas's Hospital. He was 27 years of age, followed the occupation of a lighterman, and lived at Rotherhithe. He had been ill two years; his indisposition commenced with repeated attacks of bleeding at the nose; which had continued to recur, at longer or shorter intervals, up to the time of his applying at the Hospital. About six months before that period, he took cold and had a cough with slight mucus expectoration; and three months after that he began to expectorate the fibrinous casts. He stated, that he felt something in the throat, made a slight cough, and so expelled them forcibly either by the nostrils or mouth. When expectorated, they were rolled up into small pellets, about the size of a pea or bean (Plate III. Fig. 1 *a*); but when placed in fluid, they expanded, and displayed the usual branched form (Fig. 1 *b*). Sometimes they were expelled entirely free from any mucus or other secretion; at others, there was a slight expectoration of mucus at the same time, but their escape was never attended by any spitting of blood, and the casts were always perfectly white. They were brought up at uncertain intervals, sometimes two or three pieces every few days, sometimes only once a week or once a fortnight. The patient was pale and sallow, and resembled a person labouring under disease of the

kidneys, but no albumen was detected in the urine, and the specific gravity was of about the usual standard. He presented evidence of consolidation at the apex of one lung, but had not any cough or expectoration, except when the casts were brought up. During the time that he attended at the Hospital, about six weeks, he improved in appearance and in general health, and the masses ceased to be expectorated. He was treated by chalybeates and tonics.

The form of the casts when first expelled, and after becoming expanded, as well as their microscopic structure, are given in the accompanying plate (Plate III. Fig. 2), from drawings by Mr. Tuffen West.

That gentleman writes:—"The casts displayed, under the microscope, delicate, newly-formed, fibrillated tissue, with blood-corpuscles more or less attached, but without true cells or nuclei. On transverse section of the larger portions with Valentin's knife, they displayed layers of repeated deposit; of which, as many as six were counted, though three or four were the usual number. The deposit was not evenly laid all round, but in irregular patches, the layers on the outer side, or nearest to the bronchial lining membrane, being the most consolidated, and presenting appearances as of channels for the passage of blood. The internal portions were softer, structureless, and very confused; numerous mucus corpuscles were seen in the minute twigs."

Figs. 3 and 4 of the same plate, represent the size, form, and microscopic characters of a mass expectorated by a phthisical man, aged 38, under Dr. Jones's care, at the City Dispensary, Queen Street, Cheapside. It had the appearance of having been moulded after exudation, in a large bronchial tube; other masses of smaller size but of similar character and form, have been expectorated by the same patient for the last few weeks. Mr. West describes the mass as consisting of much granular matter, oil globules, and fibre cells, with a few nuclei and nucleoli, but it was probably considerably altered by decomposition.

The cases offered examples of the most usual form in which the chronic variety of plastic bronchitis occurs.

Dr. Peacock, 18*th of May*, 1858.

13. *Villous Growth from the Vocal Cords, causing Death by Asphyxia.*

A. D., a girl, æt. between 8 and 9, was subject to attacks of impeded respiration threatening suffocation; she died in one of them. Since she had the measles at four years of age, her voice is said to have altered, to have become hoarser, and at times very indistinct. She never had hooping-cough. When six years old, she entered the Infant School at Marylebone Workhouse, and attracted the resident surgeon's attention (Mr. Filliter) by her peculiar wheezing respiration, and occasional loss of voice. During the following year she was treated several times by external irritation to the neck, and by a solution of nitrate of silver internally, which latter aggravated the symptoms.

In June, 1857, Dr. Randall, the present medical officer, was suddenly sent for, and found her exhibiting symptoms of impending suffocation. On regaining consciousness, her voice was gone, and the breathing was loud and roaring. Counter irritation externally appeared to relieve her considerably, and she left the Infirmary, to which she had been removed, for a period of two months. There was a recurrence of the violent attack in March last, and again on the 2nd of May, at ten o'clock at night, when she was found to be dead before medical aid could reach her, otherwise tracheotomy would have been instantly performed.

At the *post-mortem examination*, the larynx being laid open from behind, a warty growth was found occupying the situation of the superior and inferior vocal cord of each side, and intervening ventricle, a very narrow, almost imperceptible interval existing between the opposing growths. On examining the structure, it was seen to be a specimen of the ordinary villous growth, consisting of numerous very minute villi, thickly coated with pavement epithelium.

Mr. Henry Thompson, 18*th of May*, 1858.

---

14. *Specimens of Disease of the Lung, Larynx, and Liver, supposed to be Syphilitic.*

This specimen of the disease in the liver resembles the three

to be hereafter described,* and may be regarded as a fourth example of it: in the present case, we have the additional fact of the fibröid deposit being found in the lung.

As in the other instances, the history was unfortunately wanting, the patient being a sailor, just arrived on shore, and dying without giving any account of himself. The only marks of syphilis on the body were a phymösis, due apparently to a contracting sore on the penis, and the scar as of a bubo in the groin. He was taken into the Hospital almost suffocated with a laryngeal affection, expectorating mucus and blood, and he died in a few hours. The organs found diseased were the larynx, lungs, and liver. The whole mucous membrane of the larynx and trachea was deeply ulcerated, and the walls of the tube much thickened by an infiltration of fibrous tissue into the sub-mucous structure; a great induration of the windpipe was thus produced. The fibrous tissue was, in parts, also diffused through its whole thickness, and on the external surface there was a patch of similar structure. At one spot within, the thyröid cartilage was bare. The lymphatic glands in the neck were enlarged. The liver contained about a dozen, hard, round fibrous tumours, the largest the size of a marble; these were of a yellowish-white colour, tough, and of leathery consistence, quite dry and emitting no juice on pressure. In two or three the circumference of the tumours consisted of a translucent structure, and this was evidently the more recent formation, the opaque and yellow parts being probably similar, undergoing a degenerative change. All these nodules were quite circumscribed, and although projecting on the surface of the liver, had considerably contracted the tissue around. At one spot, between the two lobes, a deep cicatriform appearance was produced by the contraction arising from a group of these small nodules. The microscope shewed the structure of these nodules or tumours to consist of nucleated fibres and simple fibrous tissue.

The disease of the *lung* constituted the most interesting part of the case, as the organ contained some fibrous masses exactly corresponding in structure to those in the liver. In each upper lobe, was a mass of deposit larger than a marble (Plate IV. *a*, *a*);

* See "Diseases of the Digestive Organs," in the present volume.

DESCRIPTION OF PLATE IV.

This figure represents a section of part of the Upper Lobe, in Dr. Wilks's case of Supposed Syphilitic Fibröid Deposit in the Lung, p. 56.

Two nodules of deposit, which have been cut through in making the section are seen:—the one *a a*, hard, dense, and circumscribed; in the other, *b*, a softening action has commenced.

D'Wiles del Taffen West lith

W West imp

which, on being cut through, was seen to be totally unlike any ordinary inflammatory or scrofulous deposit, but consisted of a circumscribed nodule of a firm, yellowish, dry substance, corresponding in all particulars to that in the liver, excepting being somewhat less firm. At the side of one of these masses was another one, softening, breaking up, and in process of forming a cavity (Plate IV. *b*). This was peculiar, inasmuch as the circumscribed space or cavity formed by this adventitious material, also contained in it a part of the softened contents, in the form of distinct layers. The microscope shewed these to consist of fibres exactly resembling those found in the hepatic tubera, and thus widely differing in composition from any ordinary pneumonic or tuberculous deposit, which are formed only of cells and nuclei of various shapes.

The question arises, what is the nature of this disease, affecting three organs of the body? and in answer to any suspicion that it might be a form of cancer, we may state that this assuredly is not the case, as the deposits contained no juice or cells of any kind; and moreover, a cancer of the liver is not associated with a cancer of the larynx, the latter being epithelial, and a local affection. Nor can it be considered a form of malignant fibröid, as hitherto, in all examples of this disease, the growths have commenced externally, or in one part of the body, and subsequently the internal viscera have been affected; besides, the form and character of the growths were altogether different. The term cancer, and malignant disease, suggest a constitutional cause as productive of a similar adventitious deposit in three organs of the body, and no doubt such a cause was present: our own belief is that the cause was syphilis, both from a comparison of the present case with others of a like kind, and from the evidence contained in itself; this being, that the disease of the larynx was, with very little doubt, syphilitic, and therefore, the somewhat similar affection in other organs, was, most likely, to be of the same kind. The disposition in tertiary disease, appears to be towards the production of fibrous tissue due to a slow inflammatory process, and thus tumours are formed within the body, which may or may not soften, and on the cutaneous and mucous surfaces deposits are formed, accompanied by ulceration; the dense tissue beneath an ulcerated pharynx, being often very considerable. Should the case be

altogether such as we take it to be, the most interesting feature of it is the lung disease, as shewing a deposit quite different from the ordinary pneumonic or scrofulous matter. Although many practical physicians believe that pulmonary disease, or phthisis, has had syphilis for its existing cause, yet this has been looked upon merely as one of the means, which, by debilitating the system, bring the latent constitutional affection into play, and not as productive of any specific form of malady; and the question has not been elucidated by *post-mortem examination*, since at the time of death, the lungs are so disorganized, that no peculiarities have been observed; but in the present instance, owing to the early stage of the affection, the deposit was seen to be peculiar, and resembling exactly that met with in other organs of syphilitic subjects, and thus, we think, manifestly proving that the pulmonary affection in syphilis is a disease, sui generis.

Dr. WILKS, 18*th of May*, 1858.

III.—DISEASES, MALFORMATIONS, ETC., OF THE ORGANS OF CIRCULATION.

1. *Persistent Ductus Arteriosus, etc.*

The heart exhibited, is that of a child, aged three months. The child was apparently healthy at birth, but was never suckled, and had always been fed artificially, and, as it appeared, improperly. From birth up to its death, the child continued to lose flesh, cried very feebly, and was during the last month of life, occasionally convulsed. The body of the child after death was hardly as large as that of a fœtus born at term, and very much thinner, being literally almost nothing but skin and bone; the eyes were very sunken, and the skin of a dingy colour.

The heart is exceedingly small, hardly larger than a walnut. It is of normal shape, and the ventricles of the proper proportional thickness. The foramen ovale is open, but the communication between the two auricles cannot have been very free during life. The ductus arteriosus is quite pervious. It forms a canal with walls nearly as thick as those of the aorta, into which it opens, a short distance after the giving off of the left subclavian

artery. Its diameter close to the aorta is three millimetres. The pulmonary artery is much wider at its origin than a short distance beyond.

Other organs present nothing worthy of record. The lungs were not affected with atelectasis.

Dr. Graily Hewitt, 20*th of October*, 1857.

---

2. *The Left Common Iliac, the Left External Iliac, and part of the Femoral Veins, with part of the Lower Vena Cava, from a case of Phlegmasia Dolens.*

The history of the case was as follows:—

M. S., æt. 33, a laundress, the mother of three children, was delivered of a fourth on the 8th of June, 1857. The labour was in its expulsive stage very quick, the placenta followed very shortly. A large clot of blood was removed from the vagina four hours afterwards. Lactation was normal. Up to the eleventh day after labour, her condition gave rise to no uneasiness. It was indeed stated, that before this period she had occasionally complained of pains in the head and want of sleep. Her appetite was good, and on the ninth day, a little porter was given her at her special request. On the eleventh day, in the evening, a violent thunderstorm took place, and she was much alarmed and excited thereby, and was only prevented from throwing the child down by the attendants. For two or three days after the storm, she frequently spoke irrationally, but was easily set right by a word or two from a bystander. On the day following the storm, also, she was sick, but there was no pain in the abdomen on pressure. The night after the storm she got out of bed while alone for an instant, and walked in an excited state from one room to another, across a cold passage. On the fourteenth day, one of her wrists was very painful, and a little swollen; one of her shoulders also was in a like condition. A day or two after this, diarrhœa easily checked by medicine, was noticed.

On the 14th of July, she was admitted into St. Mary's Hospital, under the care of Dr. Chambers. She was then in a state of great prostration, the left leg and thigh being very much swollen, and of a white colour; there was no milk in the breasts.

A hard cord was felt running up the inside of the thigh affected. Delirium, vomiting, etc., soon set in. On the 22nd of July, a hard tumour was perceived above the left groin, very tender and painful, which gradually increased in size. Death took place on the 25th of July, at one o'clock P.M., the swelling in the groin having broken and discharged a puriform fluid, nine hours before the fatal event.

Post-mortem examination on the 27th of July.—Left leg twice the size of the right. Abdomen very greatly distended by flatus. Two inches above Poupart's ligament on the left side, is a small opening communicating with a cavity the size of a walnut, immediately beneath the skin of the abdomen. This cavity is found to be continuous with the superficial epigastric vein, and contains a grumous fluid. The veins of the left side of the thigh and pelvis, up to the junction of the two common iliac veins, contain a fluid of a puriform consistence and of exactly the colour of *café-au-lait*, without clots. A large irregularly shaped cavity communicating apparently with the vein at the junction of the two iliac veins of the left side, and situated behind these vessels, contained a fluid similar in colour and appearance to that within the veins. This abscess was composed of a thinnish wall resembling that of the veins. The arrangement of the veins joining to compose the internal iliac vein was not recognizable, the abscess in question occupying their usual position. No pus was extravasated at any other part of the wall of the pelvis. The left femoral and external iliac veins are lined by a delicate membrane, injected, of a bright red at the valves. The common iliac vein of the left side, presents a different appearance. (This vein, together with a part of the vena cava inferior, of the right common iliac, and the left external iliac and femoral veins, were exhibited.) The vein is lined by a membrane of a darkish-red colour, having the thickness of a millimetre, firmly adherent to the internal coat of the vein. This morbid deposit extends upwards about one inch and a half into the vena cava inferior, on the left side of which vein only it is observed, and it ceases abruptly below where the two common iliac veins join. The vena cava inferior contains a loose, imperfectly-formed, rather light clot, and a fluid of a reddish colour. In the right

iliac and femoral veins is a similar fluid, redder at some parts of the vein than at others. The heart was flabby; being pale on section. Right cavities stained of deep-red colour, the left cavities not stained. No clots in either side of the heart, no fluid in the left. No fluid in the pleura, lungs tolerably healthy, no abscess to be found on section of these organs, or in the liver. Liver very pale. Kidneys congested; also the spleen. The joint at the pubic symphysis distended with pus, the cartilages destroyed, and the surfaces of the bones exposed. Uterus rather soft, no pus in the substance of its walls, ovaries normal.

Careful consideration of the facts of the case, would appear to shew that the obstruction to the flow of blood from the lower extremity was situated in the left common iliac vein, coagulation of the contents of this vein, together with, in all probability, those of the internal iliac vein of this side, having been produced in consequence of some morbid condition of the veins leading from the uterus. The internal surface of the left common iliac vein presented what must be considered to be the remains of the clot, which probably, more or less, perfectly closed the vessel at that situation. The appearance of the contents of the large veins in question, at the time of examination, seemed to shew that two fluids, blood of a tolerably natural colour, and a puriform fluid, had only recently become mixed. This may be accounted for in two ways, by supposing either that the abscess in the pelvis had only recently evacuated itself into the iliac vein; or, that the remains of the clot which at one time obstructed this vein had but just been removed, thereby admitting the puriform fluid into the general circulation; or, lastly, which, on the whole, appears most consistent with the facts observed, that both of these circumstances took place, the latter of these two events preceding the former by only a short space of time.

Dr. Graily Hewitt, 20*th of October*, 1857.

---

3. *Obstructive and Regurgitant Disease of the Aortic Valves, probably dependent on Congenital Malformation.*

This preparation was removed from a gentleman, æt. 40, who resided at Plaistow. He was first seen by Dr. Peacock on the

3rd of July, 1857, and then stated that he had been ill three weeks. He ascribed his indisposition to having taken cold from leaving off a flannel waistcoat during the very warm weather. He first suffered from what was supposed to be a bilious affection, and had two aguish attacks; one about a fortnight before he was seen, the other on the previous day. He had a peculiarly sallow, malarious aspect, and his pulse was quick and feeble. He had a somewhat tumid face and œdema of the ankles, with difficulty of breathing, increased on slight exertion, and palpitation of the heart. On examining the chest the resonance on percussion was found considerably impaired at the lower part of the left side, both before and behind, and in the dull space the respiratory sounds were abolished. The præcordial dulness was found to extend much beyond its natural limits, and a loud systolic murmur was audible over the whole cardiac region, and especially at the base.

He was seen again on the 5th, in consultation with the late Mr. Beale, and was then much worse; the dyspnœa was so extreme that he could not lie down in bed, and the dropsical symptoms were increased; the lower extremities were very œdematous, the abdomen tumid, and the face swollen; the pulse was regular, but powerless and quick; and the dulness on percussion in the chest, and especially on the left side, was much extended, and there was sub-crepitant rhonchus heard on both sides in the dorsal regions. From this time, he rapidly got worse, the anasarca increased, the dyspnœa became still more urgent, and he died suddenly after having got out of bed on the 8th, having been quite sensible to the last.

The following notes of the *post-mortem* appearances were obligingly furnished to Dr. Peacock by Messrs. Beale and Williams, of Plaistow, under whose care the patient had been.

"The body was examined thirty-six hours after death. On removing the sternum, the pleural cavities on each side of the chest were found to contain a large quantity of fluid, probably two quarts. The lungs were healthy, and without any adhesions. The pericardium was full of fluid, and the heart very much enlarged, occupying a considerable portion of the cavity of the chest, and was depressed below its usual situation by the fluid

in the left pleural cavity. On cutting into the substance of the heart, the walls of the auricles and ventricles were much hypertrophied, particularly those of the left ventricle. The ventricles were both filled with coagula, and the external surface of the heart exhibited appearances of recent inflammation. The valves of the pulmonary, and those of the left auriculo-ventricular aperture were not diseased. The ascending aorta was much enlarged, and on dividing it below the arch and passing the finger to its mouth, a hard, stony-like substance was felt, which on examination proved to be a deposit of bony matter occupying the sides of the vessel, and covering the aortic valves. The liver was large and rather pale, the spleen large, and, together with the kidneys, congested. The rest of the abdomen was free from disease."

The appearance of the aortic valvular apparatus is well shewn in the accompanying figures (Plate III. Figs. 5, 6). The three segments are entirely blended together, so as to form what has been termed a diaphragm, extending across the orifice of the artery, but having a triangular aperture in the centre, of about four lines wide, in each direction. The remains of the valves are very greatly thickened, indurated and ossified, so that there must have been not only great obstruction to the flow of blood from the ventricle into the aorta, but also regurgitation from the artery into that cavity.

On first seeing this case, Dr. Peacock stated, that he had much difficulty in forming a satisfactory diagnosis. The patient had never had any of the usual predisponents to disease of the heart, and stated that he had been in good health till three weeks before. The district in which he resided, the aguish attack which he had had, and his peculiar appearance, indicated that he was labouring under the influence of malaria; and, in the absence of any symptoms of recent cardiac affection, it was thought most probable that he had for long suffered from some latent valvular disease; which, though slowly making progress, had been unproductive of any symptoms, till his powers became prostrated by the aguish attacks. A suspicion was, therefore, expressed that the disease might be dependent on some congenital defect of the aortic valves. This opinion proved, it will be seen, to be correct;—at least there can be no doubt of the very old date of the

aortic valvular disease, and that it must have originated in early life, if, as seems most probable, it were not congenital.

Mr. Beale, who had known the patient during all his life, wrote:—"I attended him when a child, and he had then very delicate health, and a feeble circulation; and, if I remember rightly, he had one or two attacks of purpura. On his attaining nineteen or twenty years of age, his constitution became more robust, and it is remarkable that since that period, he has had good health, and has not complained of any disease." Dr. Peacock was also informed by members of the patient's family, that he was of remarkably active habits, and so quick a walker, that few could keep up with him, and that he was never observed to be subject to difficulty of breathing on exertion. He was, however, of somewhat irregular habits, and had had considerable anxiety of mind shortly before his illness.

Dr. Peacock remarked that the case was one of great interest; first, as shewing in a more marked degree than any other which had fallen under his notice, how large an amount of valvular disease may exist during a long period, without giving rise to any symptoms to indicate its presence; and secondly, how suddenly those symptoms may be developed, under the influence of any cause which prostrates the general power, and so renders the heart, no longer capable of overcoming the long existing obstruction. The hypertrophy of the left ventricle in the case, was very marked. Mr. Williams, who, while at the London Hospital, had great experience in *post-mortem examinations*, stated that he had never seen so large and thick a left ventricle. From the notes of the case, it appears that during life there was only a systolic and not a diastolic murmur heard; this probably depended on the prostration of strength, and the feebleness of the circulation at the time. Certainly the rigid state of the aortic valves must have entirely prevented the usual diastolic valvular sound being produced.

Dr. Peacock, *20th of October*, 1857.

---

4. *Blocking of the Cerebral Arteries.*

J. S., æt. 35, a pitman, was admitted into St. Thomas's Hospital under the care of Mr. Le Gros Clark, for hydrocele. The hydrocele was tapped, but from the enlarged condition of the testicle no other treatment was had recourse to. Three or four days after his admission, he began to lose the use of the right arm, and subsequently his speech became affected. On the 17th of July he was removed into the medical wards, and placed under the care of Dr. Peacock. The following notes were taken on the 18th." He appears intelligent, but speaks very imperfectly He has entirely lost the power of moving the right arm, but the sensation does not seem to be impaired, and he can move both legs. The pupils are large and act very imperfectly. He has had small does of hydrag. c̄ creta two or three times, and is profusely salivated, and it is consequently impossible to say whether there is any paralysis of the face and tongue: his pulse is quick; there is no evidence of any cardiac disease." It appears that about six months before his admission into the Hospital, while working in a coal-pit, he had a sudden seizure in which he was paralyzed and became partially blind, and he has not entirely recovered his sight. He was directed to take small doses of magnes. sulph. with sulphuric acid, and use a gargle containing chlorinated soda.

On the 22nd, he was mnch more intelligent-looking, but spoke very imperfectly. The mouth was drawn to the left side; the pupils were largely dilated, (more particularly that of the left eye) and almost insensible to light. He had full power over the right leg, and could partially raise the right arm, but could not extend the wrist. He could swallow solids, but not liquids. The mercurial action still continued, and the tongue was much swollen.

Two days after, the salivation had nearly subsided, when on the 6th of August he was again suddenly seized, became comatose, and contiued so till his death on the 8th.

Post-mortem examination. — Height, five feet seven inches; weight, seven stone four ounces; somewhat emaciated; calvaria and dura-mater healthy; subarachnöid fluid in somewhat diminished

quantity. The larger veins with their minuter branches (ramifying over the surface of the convolutions) were distended with blood; but there appeared to be little or no true capillary congestion, since the brain-surface between the congested venous network was decidedly pale. On section, the white substance was found to be studded with an unusually large number of vascular points; but was normally firm, and healthy in all other respects. The grey matter also was healthy. The ventricles contained but little fluid, and their parietes were sound.

The basilar artery in nearly its whole length was white and opaque, forming a rigid cylinder; and looked as though its walls were extensively diseased. On section, however, the walls were found to be really healthy, but the canal was occupied by a cylindrical body, the anterior extremity of which was rounded, while the posterior was bifid and formed a nipple-like projection into each vertebral artery. The body was hollow, and contained a little colourless fluid; its parietes consisted of a tough, greyish-material, and was thicker at the extremities than at the sides. It was adherent to the arterial coats, but the adhesions were neither dense nor universal; and it is possible that there was room for a little blood to find its way between them.

The cerebral portions of the internal carotid arteries were not more than half their normal diameter; and both they and their branches, to a distance of half an inch, were blocked up by solid adherent coagula of old formation. All the other arteries at the base were healthy, and contained blood either fluid or in a softly coagulated state. The material blocking up the arteries was evidently, in all cases, the remains of coagula deposited some considerable time prior to death.

The heart was large, its cavities contained recently coagulated blood, and there were numerous small extravasations beneath the lining membrane of the left ventricle. There was a small hydrocele on the right side, and the right testicle was in a state of chronic inflammation; but all the other viscera (thoracic and abdominal) were in a healthy condition.

Dr. Peacock and Dr. Bristowe, *3rd of November*, 1857.

---

5. *Diseased Mitral Valve—Extreme consequent Hypertrophy of the Right Ventricle.*

J. P., an engineer, æt. 41, was admitted into St. Thomas's Hospital, on the 28th of July, 1857. He stated that he had had three distinct attacks of rheumatic fever, of which the first occurred at the age of nineteen; that, with these exceptions, he had enjoyed good health up to eight or nine months back, when he began to experience shortness of breath, with occasional pains in the chest; to which were added, about four months before admission, palpitation and anasarca, and subsequently, slight cough.

When received into the Hospital, he was suffering from dyspnœa (almost amounting to orthopnœa), anasarca, cough (with slight expectoration), palpitation, and occasional cutting pains in the region of the heart. The pulse was irregular. The cardiac dulness was increased. Over the aortic valves, the first sound was healthy, though feeble; the second was distinct, but accompanied by a kind of hum or reverberation, which was more marked over the ascending aorta than over the valve itself. I never myself detected a distinct murmur at the aortic orifice, but am quite satisfied, from the statements of others, that a soft, circumscribed, diastolic murmur was occasionally present. The second sound over the pulmonic valves was remarkably loud, but healthy in character. At the apex, both the first and second sounds were indistinct, and their indistinctness was increased by the heart's irregular action; but, on more than one occasion, I clearly recognized a faint systolic murmur. The auscultatory phenomena, presented by the lungs, were nothing more than those belonging to slight bronchitis or œdema.

The patient lived in the Hospital nearly three months; during which time (notwithstanding the treatment adopted) his symptoms, without materially altering in character, became gradually more distressing. The difficulty of breathing became extreme, the anasarca very considerable, and effusion began to take place into the serous cavities. A few days before death, the expectoration, which accompanied his cough, began to be tinged with blood. He gradually sunk, and died on the 17th of October.

Post-mortem examination. — Height, five feet nine inches; weight, eleven stone nine pounds. The body was in tolerably good condition, but very anasarcous.

The left pleura contained about three pints of serum — the right, about a quart. There were a few old adhesions in each; and a little recent lymph, most abundant in the left, roughened the surfaces of the lower lobes of both lungs. The lungs were small, and their lower lobes much compressed, and altered in shape, by the pressure of the fluid external to them; they were neither congested nor œdematous, indeed, almost dry on section; their upper lobes were very sparely crepitant, their lower ones almost entirely airless. There was a small recent apoplectic clot in the right middle lobe; and one of irregular shape, but about as large as a hen's egg, in the lower lobe of the left lung; neither of them reached the surface, and therefore, could not have caused the slight recent pleuritis. The bronchial tubes contained much viscid, reddish mucus, but were themselves healthy.

There were a few ounces of serum in the pericardium. The heart, was large and weighed twenty-three ounces; but its shape was abnormal, since the right ventricle formed its apex. The walls of the left ventricle were scarcely half an inch thick, but of usual consistence and colour; the cavity was a little dilated. The free edges of the aortic valves were somewhat thickened and contracted, but the valves were moveable, and could not have produced obstruction, though they probably allowed of slight regurgitation. The chordæ tendineæ were somewhat thickened and shortened. The orifice of the mitral valve was so much diminished, that it scarcely admitted the tip of the little finger; the valve itself was rigid, and extremely thick, and contained a considerable amount of earthy deposit; some of the thickened masses in connection with it were as large as a hazel-nut. The auricular surface presented several patches, in which slight erosion had taken place. The left auricle was much dilated, and its walls were decidedly and very considerably thickened. The walls of the right ventricle were three-eighths of an inch thick, firm, and somewhat pale; the cavity was not very large, and the valves in connection with it were healthy. The right auricle

was much enlarged. All the cavities, but more especially the auricles, contained large coagula.

The peritoneum held two or three quarts of serum. The liver was of usual size, a little indurated, and much congested. The spleen was small, plump, dark-coloured, and firm; and its capsule was somewhat thickened. Pancreas and supra-renal capsules healthy. The mucous membrane of the stomach had a dusky reddish hue, and that of the jejunum was much congested; but in other respects the intestinal canal was healthy. Kidneys congested. The aorta presented a few patches of atheroma.

The above specimen was brought under the notice of the Society, chiefly to shew the great degree to which the right ventricle of the heart may be hypertrophied, in consequence of mitral valve disease alone. That increase in the size of this ventricle is a usual consequence of chronic bronchitis, and of obstructive disease at the mitral orifice, is a well-known fact, but the subject of the present communication is the most extreme instance of this form of hypertrophy that has fallen under my notice. I have seen greater enlargement of the right ventricle associated with malformation of the heart, but never, as before stated, with disease alone. Dr. Bristowe, *3rd of November*, 1857.

---

6. *Dilatation of the Basilar Artery fatal by Rupture and Hæmorrhage.*

J. J., æt. 60, a coal-heaver, was brought to St. Thomas's Hospital, between four and five o'clock in the afternoon, in a state of syncope, from which he recovered in a very short time, so completely, that, complaining only of pains in his legs, he was anxious to be allowed to leave. A suspicion of something more serious than appearances seemed to indicate, induced the resident medical officer to insist upon his remaining in the Hospital. He was sent to bed, where he remained comfortable, and apparently well, for two or three hours. He then began to get drowsy, and fell off a little before eight o'clock into what, the sister of the ward thought, was a comfortable sleep. In a short time, however his breathing became stertorous; he soon passed into a state of complete coma, and died at half-past eight. It

was subsequently learnt, that about twenty minutes or half an hour before admission, he fell down suddenly, faint and insensible, in the act of carrying a sack of coals from one barge to another; and that he had been in perfect health up to the moment of his attack.

Post mortem examination.—Calvaria and dura mater healthy. The upper surface of the cerebrum was much flattened against the bony parietes, and the inter-gyral spaces consequently were almost obliterated; yet a little bloody-fluid was observed in the sub-arachnöid tissue over the anterior part of each hemisphere. Neither the surface, nor the interior of the brain was congested, and its substance was, for the most part, of normal consistence. The fornix, however, was pulpy, and the lateral ventricles were much distended with bloody serum. A black-currant jelly-like coagulum was observed in each descending cornu, and a little similar material projected on either side from the foramen of Monro. The latter was continuous with a recent soft coagulum, which distended the third ventricle, and extending along the 'iter' was found equally to distend the fourth. On removing the brain from the skull, a large quantity of recently coagulated blood was found diffused through the sub-arachnöid tissue of its base. It surrounded, and almost completely concealed the medulla oblongata and pons Varolii, together with the vessels and the origins of nerves connected with these bodies. It covered, in an almost equal degree, the whole of the under surface of the cerebellum, and the parts corresponding to the circle of Willis; and radiated thence in various directions, but in greatest abundance along the arterial trunks; extending in this manner along the vermiform process of the cerebellum, around the crura cerebelli and cerebri to the fourth ventricle, and inferior cornua of the lateral ventricles, and along each Sylvian fissure. On clearing the clot away, and exposing the arteries at the base, they were found to be much diseased throughout; they were larger and more rigid than natural, and studded rather thickly with atheromatous deposit. The commencement of the basilar artery, for three-quarters of an inch of its course, was considerably dilated, measuring about half an inch in length and nearly as much in thickness. The parietes were thick, opaque, and somewhat brittle; and, to the left, presented a small lacerated opening, by which the effused

blood had escaped. The corpora striata and optic thalami, and, indeed, all parts of the brain not hitherto alluded to, were perfectly healthy. There was no blood, or other kind of effusion in the cavity of the arachnöid.

The heart was somewhat enlarged, but its ventricles were contracted and empty. There was a little atheroma in the mitral valve, and there were a few nodules of earthy matter along the attached margins of the aortic. The aorta was studded throughout with atheromatous patches. All the other organs, thoracic and abdominal, were healthy.

The above case affords a well-marked example of Dr. Abercrombie's second form of apoplexy. On comparing the *post-mortem* appearances with the symptoms during life, there can be no doubt, that the sudden attack of faintness and loss of consciousness (from which the patient recovered,) were due to the shock which attended the rupture of the basilar artery, and the sudden effusion of blood into the sub-arachnöid tissue; and, that his subsequent death by coma was dependent on the increasing pressure produced by the gradual and constant oozing of blood, which took place after the establishment of reaction.

Dr. Bristowe, *3rd of November*, 1857.

---

7. *Congenital Deficiency of the Sternum, rendering visible the Movements of the Heart.**

E. A. G., æt. 26, a native of Hamburg, has for several years been exhibiting himself in the principal towns in Europe, where his case has attracted the attention of many distinguished physicians, especially in reference to the ocular and palpable manifestations which it affords of the movements of the heart.

The congenital fissure in the sternum, leaves a hollow of a conical shape, with the apex downwards; this hollow is covered only by the integuments; and in its middle-third, is seen a body, pulsating in correspondence with the motions and sounds of the heart.

Motions.—That the pulsation thus visible, is chiefly seated in

* The person who was the subject of the malformation presented himself for examination before the Society.

the right auricle, appears to me obvious, from its great resemblance to the same motion, observed in the exposed heart of the ass; and from the fact, distinctly perceptible in slow pulsations, that this motion immediately precedes the ventricular systole, the wave of motion beginning with the auricle, and rapidly passing downwards to the ventricle. In quick pulsations, the motion felt in the sternal space, and the systole of the ventricle as felt and heard in the cardiac region, seem to be simultaneous, but in the more deliberate movements, when the pulse is about 65 in the minute, the wave-like progression can be traced from the auricle to the ventricle, the upper portion of which sometimes comes into view at the lower portion of the sternal fissure. To the rapid systolic movement succeeds a slow dilatation, and that this proceeds from the flow of blood into the auricle from the venous trunks, is made more plain by the fact, that pressure on the abdomen, which forces the blood onwards through the ascending vena cava, accelerates this slow expansion of the auricle. The aorta can be felt pulsating more deeply above the position of the auricle; and a like pulsation of the pulmonary artery may be felt through a part of the auricle close to the left margin of the fissure.

The sounds accompanying the respective motions, can also be distinguished with clearness only in the slowest pulsations. By aid of a small flexible ear-tube, with a narrow end, I was enabled to hear a distinct sound accompanying the commencement of the auricular contraction; it is a faint, short, or flapping sound, and ends in the less abrupt and more distant tone of the ventricular systole. When the stethoscope is placed over the ventricle, the flapping sound of the auricle is not heard; but the ventricle swells or rolls out its peculiar sound until it ends with the sharp clack of the second or diastolic sound. I infer from this, as well as from direct observations made on animals,* that each movement of the heart has it proper sound; and that the reason

* In an experiment conducted, nearly twenty years ago, by the late Dr. Clendinning at the Marylebone Infirmary, the auricles were observed to contract vigorously after all motion of the ventricles had ceased. I pointed this out to those present as an auricular movement, producing a sound of very appreciable intensity. A similar observation has been made in America.

why the auricular sound is not usually heard, is because it is too faint to pass through the intervening lung and walls of the chest.

The diastolic, valvular, or second sound is remarkable for its clearness and loudness in this case. On one occasion, I found it reduplicated, or double; and I had the opportunity of verifying the explanation of this double second sound, which I gave more than twenty years ago. When the end of the stethoscope was placed over the aorta, the diastolic sound was single and clear, but on moving the instrument a little downwards, and to the left, so as to cover a part of the pulmonary artery, the sound became double (as I formerly endeavoured to express it, by the syllables —*lubb-durrup*, instead of *lubb-dup*, the common double sound), obviously from the two sets of valves closing, not simultaneously, but in succession. As this phenomenon often presents itself in disease, it is satisfactory to be enabled thus to trace it to its cause. The reason of the tardier closure of one set of arterial valves, I presume to be a less distended state of the corresponding artery, or a diminished tonicity of its coats.

The only remaining observation which I have to record, is that of a murmur, or short rasping sound in the right carotid artery. This does not appear to have been noticed by any other observer, and I do not think it was present when I examined the man two years ago. These murmurs are not unfrequently heard in the carotids, generally the right, and it is sometimes a question whether they are produced there, or are transmitted from the aorta or its orifice. In this case it was easy to decide that it was not aortic, for not a trace of murmur could be heard when the instrument was placed on that artery, or in the course of the innominata. It was, therefore, a purely carotid murmur, probably dependent on some partial pressure.

In conclusion, I would remark that the examination of this interesting case of exposed heart, seems to me fully to confirm the best established views, which are now commonly taught respecting the motions and sounds of the heart; and although M. Groux's Album records some dissentient conclusions among the remarks of his commentators; these are no more than might be expected in a case requiring, for its investigation, much nicety of observa-

tion, as well as some experience, in this particular branch of semeiology. Dr. C. J. B. WILLIAMS, 17*th of November*, 1857.

---

8. *Diseased Mitral and Aortic Valves.*

A tall, fine looking man, æt. 35, was brought into the Royal Free Hospital, evidently almost moribund, with blue lips, a haggard, and anxious face, and a rapid, feeble, irregular pulse. During the forty-eight hours that preceded his death, he spat up much frothy, viscid, white fluid; only ceasing to expel it as his strength failed. There was little or no anasarca. Urine highly coloured, devoid of albumen.

The respiratory sounds offered noisy, large rhonchus and crepitation, so extremely rough and grating, and causing so much sensible vibration of the thorax, as to suggest pleuritic friction, to one gentleman who examined the patient. The heart was evidently somewhat dilated. Its sounds were feeble and irregular; but the second sound, though softer than natural, suggested a pretty complete closure of the aortic valves. The first sound was less distinct than natural, but unaccompanied by anything like a bellows-sound.

The diagnosis arrived at, was disease of the mitral and aortic valves of the heart, probably of long standing, with mere congestion of the lungs. The *post-mortem examination* shewed an old calcified deposit in the aortic and mitral valves, such as would permit but little regurgitation through either.

Dr. BRINTON, 17*th of November*, 1857.

---

9. *Aneurism of the Arch of the Aorta, fatal by Rupture into an Ulceration of the Trachea. Occlusion of the Sub-clavian Artery.*

A Belgian physician, æt. 50, married, who had resided in England eight years, had suffered peculiar pain on the right side of the head during the whole of this period, and from tightness and pain in the chest for the greater part of it, with occasional seizures of pain through the lower part of the chest; he believed himself to be the subject of heart-disease, but never underwent a medical examination. Four months before death he had a trouble-

some dry cough, this became less troublesome, but never entirely disappeared; soon after, a difficulty of deglutition was complained of, and this increased, but was not always equally troublesome.

November 19th, 1857. He raised a little blood in the forenoon, partook of dinner as usual, walked out a short distance in the evening, and retired to his bedroom alone, where he was found the following morning dead by the bedside, a large quantity of dark bloody fluid being in the hand-basin near, and in the utensil at the foot of the bed. He had been of temperate habits; there was no history of previous disease, except hæmorrhöids, from which he once suffered some loss of blood.

Post-mortem examination—The body was of middle stature, and rather broad and muscular; the surface generally pale, the face slightly livid; the amount of subcutaneous fat small. The anterior margins of the lungs were somewhat emphysematous, they approximated at one point, but a considerable space occupied by dense tissue, with glands and fat, was remarked above, and the surface of the pericardium covered with fat was exposed to some extent below; the right lung was everywhere adherent to the costal pleura by old thin membrane. The lung substance was friable, œdematous, and very dark, and every part was crepitant and floated in water; the surfaces of the bronchial tubes, which contained much thin froth, but no coagula, seemed stained with blood and also injected. The left pleural cavity contained some dark fluid; the pulmonary veins contained much dark, fluid blood. The heart was somewhat enlarged, and there was adhesion between its apex and the pericardium. The walls of the right ventricle were very thin and coated with fat, the cavity slightly dilated, the valves healthy; the left ventricle was healthy, its walls hypertrophied; all the cavities were empty; the first part of the aorta was embedded in fat; two inches from the valves began an aneurismal dilatation, the whole of the arch of the aorta being implicated, and all the walls dilated, the posterior and inferior to a less degree than the anterior and upper; the origins of the innominata and of the left carotid were widely separated; the tumour measured nearly four inches across, and five inches from its commencement to its highest point in the neck, where it was somewhat pointed and closely adherent to the left side of the trachea; much

dense tissue and a few glands extended from this part to the first dorsal vertebra, adhering to its body, and partially enclosing the œsophagus. The left sub-clavian artery arose at a little distance from the carotid, rather at a lower level and towards the posterior aspect of the tumour; it was rather smaller than usual, and its communication with the aorta completely occluded; the vessel was pervious immediately beyond the aneurism. The interior of the aneurism was smooth, all the coats seeming to be entire, and there were patches of atheroma rendering some points thicker than others; there was no greater attenuation of one part than another, except near the point of rupture; and except at this point, the lining membrane was continuous and smooth, there being no trace of coagulum nor of fibrinous layers. There was a small irregular narrow opening at the upper and back part of the cavity communicating with the trachea; no trace of the origin of the sub-clavian artery was perceptible on the inner surface of the aneurism; there was slight thickening at that spot, but the surface was perfectly smooth.

The portion of the trachea implicated, was from about an inch below the cricoïd cartilage to within two inches of the bifurcation, an ulcer of oval shape and well-defined edges extending in a longitudinal direction over the junction of the rings corresponding to this part, and five of the rings of the trachea being partially absorbed on the left side; the opening was in the centre of the ulcer and about a quarter of an inch in length. Some small coagula were noticed in the trachea and larynx, none in the œsophagus: the stomach contained much dark blood, but none seemed to have passed the pylorus.

Mr. W. Squire, 1*st of December*, 1857.

---

10. *Obstruction of the Cerebral Arteries by Fibrinous Plugs, in connection with Deposits on the Aortic and Mitral Valves.*

This is an uncommonly well-marked case of obstruction of the cerebral arteries by fibrinous plugging, and occurred in a woman, æt. 44, who died in the Middlesex Hospital. On examining the vessels at the base of the brain, fibrinous plugs were observed in the basilar artery, in the anterior, middle, and posterior cerebral arteries of the right hemisphere, and in the middle cerebral

of the left. The plugs were situated at the bifurcation of the basilar, and in the other vessels at parts, where large branches were given off. Beyond, and more or less continuous with each plug, there was a coagulum, which extended some distance and was partially discoloured; but these coagula were not so firm and white as what may be called the original plugs. On slicing the brain, two patches of red softening, about the size of nuts, were observed, and these contained compound granular corpuscles. The heart was fatty; the aortic and mitral valves were covered with warty vegetations, which were very easily detached, and seemed peculiarly friable. On being examined with the microscope, the fibrinous plugs in the cerebral arteries were found to be exactly similar in structure to the *vegetations* on the mitral valve; and both consisted of granular and molecular matter, along with cells resembling the white corpuscles of the blood. The kidneys and spleen contained large masses of fibrinous deposit. The uterus was enlarged and its posterior lip thickened; it resembled the uterus of a person who had suffered a miscarriage at about the third month.

The *history* of this patient is briefly as follows:—About three weeks before death, while in good health and at work, she was seized with giddiness, and fell down. She was unconscious for about ten minutes, and on recovering her intellect, found that she had lost the use of her left side; and that she had rather copious hæmorrhage from the womb. A week after this, she was admitted into the Hospital. The uterine hæmorrhage was still copious, but there was no abdominal pain or tenderness. She was sensible, and could answer questions rationally, but there was total loss of power of the left arm and leg, and the face was drawn to the right side; the evacuations passed involuntarily, and she had no power over the bladder. She was troubled with vomiting, but generally retained her food. In the course of three days, the uterine hæmorrhage, which had occurred in gushes whenever the patient was moved, gradually subsided, and she regained so much use of the left leg, that she could draw it up in bed, and stand with assistance. The face was still drawn to the right, and the left arm continued powerless. Subsequently, the sickness occurred more frequently; she, however, became sensible

of a disposition to evacuate the bowels, and could retain the motions for a short time; she could also evacuate the bladder. These symptoms continued with little alteration for a week, and until thirty-six hours before death she remained quite sensible; she then became rather suddenly worse, stertorous respiration set in, and she died comatose.

Remarks.—The formation of fibrinous coagula in the arteries during life, was formerly considered as the usual result of arteritis. Fibrinous coagula may, no doubt, be produced locally by diseased changes in the coats of the vessels, or by obstruction of the capillary circulation; but they may also be transported from a distance, as in this case. The transported coagula (the emboli of Virchow) most frequently arise from deposits on the valves of the heart; and I have noticed that the deposits are generally either very recent, friable, and loosely attached, or very old, and of a fragile, chalky consistence. Sometimes, only a single fragment of a vegetation is carried away by the current of the blood, as in a case I brought before the Society in 1855;* but, in the present specimen, no less than five plugs are distinctly seen. They are principally situated at the points of bifurcation in the vessels, or immediately beyond the part where a large branch is given off. After an embolus is once fixed, it may either cause partial or total obstruction to the circulation; in either case, a secondary coagulum attaches itself to its distal portion; when the obstruction is only partial, coagulation takes place around the embolus, and soon produces total obstruction. The circulation through the vessel being thus arrested, unless a collateral circulation be quickly established, inflammation and gangrene may soon take place. Sometimes, an embolus and its surrounding coagulum produces inflammation of the adjacent coats of the artery; in the case of the cerebral arteries, however, apoplexy, or softening of the brain, generally puts a speedy end to the case. Emboli may vary much in size and shape, and even when very minute, may produce very marked effects. I lately examined a man, æt. 27, who had hypertrophy of the heart, and chalky, friable vegetations on the aortic valves. Fibrinous deposits were found in the heart and spleen. The

* "Transactions," vol. vii., p. 118.

arachnöid was raised by serous effusion, and two or three bloody spots, about half an inch in diameter, were seen beneath it, between the convolutions. On examining one of these bloody patches carefully, a white, angular, chalky speck, smaller than a pin's head, was found in a small vessel of the pia mater, from which the blood had evidently escaped. There were three or four minute apoplectic spots in each hemisphere, but no other concretion or plug could be discovered.

With regard to the uterine hæmorrhage in the first case, it is thought that a miscarriage did actually take place soon after the patient fell down. Dr. VAN DER BYL, *1st of December*, 1857.

---

11. *Ulceration of the Aortic Valves, with Aneurism at their bases. Old standing Coagulum in the Left Auricle.*

The person from whom this specimen was taken died about six weeks ago; he was a tradesman in moderately easy circumstances, had generally enjoyed good health, his only illness being an attack of rheumatic fever sixteen years ago, which he stated was unaccompanied by any heart-affection. He was very abstemious, and had suffered for about three months with symptoms closely resembling those of ague; his symptoms apparently commencing after severe fatigue or when he got wet through. He had a few days of general febrile excitement, pains in the limbs, &c., which ended in an aguish paroxysm, going through the usual stages, the cold and hot fit ending in perspirations. At first, these fits were not very frequent, and there was never any certainty as to the period of their return; at last he had an attack every two or three days, and then they increased to two or three daily, and again declined, so that the last week of his life he twice passed a day without an attack. The chills seldom lasted more than an hour, frequently for only half an hour, and latterly, for only about ten minutes. The hot fits mostly lasted from two to four, or five hours. The perspirations were very variable.

During the early part of his illness there appeared to be no complication, and he was during the intervals able to get about. He took to his bed about one month before his death, and I then once or twice carefully examined him, but could detect no disease, either of the heart, lungs, or abdominal organs. No pain or

tenderness existed in any part; the pulse averaged 68 a minute and was full and regular; tongue moderately clean and moist; appetite variable. He was treated with quinine both in large and small doses, opium, and arsenic, though without any material improvement, the arsenic seeming to have more effect than the quinine in prolonging the intervals.

About sixteen days before his death, he seemed to suffer considerably from præcordial oppression during one of the paroxysms, and soon after this his first heart symptoms were noticed, though even now, when not excited, his pulse fell to 68, but during an attack, or under the least excitement, it rose from 100 to 130, and gave a peculiar secondary impulse. At this time there was a distinct systolic bellows-murmur which rapidly increased, and was heard most clearly above the third right cartilage close to the sternum; there was also a diastolic murmur. The patient himself frequently complained of pain and oppression about the region of the heart, accompanied by severe dyspnœa.

Dr. Watson was called in, and he again saw him a few days later, at which time there was a very considerable increase in the loudness of the murmur, and in the extent of dulness of præcordial region, the pain, etc., was much increased during the paroxysms, being described as of a twisting, tearing character. There was frequent delirium during the paroxysms, and he suffered much from exhaustion afterwards. A blister was applied over the region of the heart, which gave some relief, and when I saw him a few hours before his death, his pulse had considerably improved, and he told me how well he felt, but during the night a violent spasm seemed to attack his heart, and he sank exhausted after about two hours. Mr. Buxton Shillito, *15th of December*, 1857.

Post-mortem examination of the above specimen.—Body considerably emaciated, there being but little fat on the abdomen, and none on the thorax.

The right lung was free from adhesions at the upper part, but was firmly attached to the diaphragm below. There was no false membrane on the pleura, but the cavity contained from half a pint to three quarters of a pint of bloody serum. The greater part of the substance of the lower lobe was involved in a gangrenous abscess.

The left lung presented slight adhesions at the apex, and at the lower lobe. It was crepitant throughout. Both lungs were free from tubercle.

The heart was situated at a somewhat lower level, and further to the left than usual. The pericardium contained from ten to twelve ounces of sanguinolent fluid.

The following notes of the state of the heart were furnished by Dr. Peacock:—

"The heart was of large size, weighing, when deprived of the reflected pericardium, eighteen ounces avoirdupois. Its surface was covered by a thin layer of recent lymph, more especially at the base and on the auricles.

"The right ventricle was of large size, and its walls measured at the base one French line and a half in thickness, at the mid-point two lines, and at the apex one line and a half. The right auriculo-ventricular and the pulmonic apertures were dilated, the former admitting of the passage of a ball measuring fifty-seven French lines in circumference, the latter, of one measuring forty-five lines.

"The cavity of the left auricle was much reduced from the presence of a tumour, which projected from its anterior wall, and was about the size of the half of a duck's egg. This tumour had an elastic feeling, and presented an opening at its extremity the size of a threepenny piece. When cut open, it was found to contain coagulated and partially decolourized blood. The left auriculo-ventricular aperture gave passage to a ball which measured in circumference thirty-six French lines. The free fold of the mitral valve was thickened and opaque, and from the pressure of the tumour the aperture had probably not been capable of complete closure.

"The left ventricle was of unusually large size, and its walls measured six, seven, and three lines in width, at the base, mid-point, and near the apex. The aortic orifice admitted the passage of a ball measuring twenty-four French lines in circumference, and a column of water introduced into the aorta did not freely flow back into the left ventricle. The aortic valves and the base of the left ventricle were, however, most extensively diseased. The right semi-lunar segment was decurtated, and its free edge

was greatly thickened and indurated, and the corresponding sinus much reduced in size. The posterior and left valves were entirely broken down, and replaced by a dense and firm mass, which projected, so as to have occasioned great obstruction to the flow of blood from the ventricle; while the membrane was wanting in places so that a probe could be pushed through soft fibrinous concretions from the aorta into the ventricle. There might thus have been regurgitation during life. Below the aortic aperture there was a long, but narrow opening, which led into a cavity, situated between the semi-lunar valves and the free fold of the mitral. This cavity was excavated in the substance of the base of the left ventricle, at its left and posterior side, and was protruded into the left auricle, so as to form the tumour which has been described. A probe could readily be passed from the left ventricle through the opening into the cavity, and thence into the left auricule; but though the valves also were perforated, there was no direct communication between the cavity and the aorta. The cavity, as before mentioned, was nearly filled by partially decolourized coagula, and the substance of the ventricle around had undergone fibro-cartilaginous degeneration, and was pale and much indurated. The aorta, though somewhat dilated, was otherwise free from disease."

The stomach and intestines were healthy; the liver somewhat large; the spleen large, solid, and containing several firm, fibrinous deposits. Similar deposits were also found in the kidneys.

Dr. Peacock adds,—

"From the dimensions above given, it will be seen that the heart was very considerably increased in size. The right auriculo-ventricular and pulmonic apertures were very large. The mitral orifice somewhat small, and the aortic aperture much less than usual, having only two-thirds its ordinary capacity. Both ventricles were greatly dilated, and the left also much hypertrophied.

"From the condition of the aortic valves, it is not clear what may have been the cause of the disease, but I think it arose from original imperfection of the valves, or from changes of very old date. The left and posterior segments were probably fused together and formed a source of obstruction to the flow of blood from the left ventricle into the aorta, which had been in progress for a long

period. Coincidently with this, the base of the ventricle appears to have undergone slow perforation, till at length the aneurysmal cavity was formed. Subsequently to these changes and at the time at which the symptoms of cardiac disorder became manifest, the base of the ventricle must have become the seat of more acute endocarditis, and so the left and posterior segments were partially destroyed. The tendency to the formation of aneurysms at the bases of the valves in cases of aortic valvular obstruction, has been pointed out by Dr. Thurnum; * and I exhibited in a former session of the Society,† a specimen which illustrated the fact. I am disposed to refer the production of the aneurysm in this case to a similar process. It may, however, be thought by others that the, changes are altogther of more recent origin, and without doubt, that they had progressed very rapidly towards the termination of life. The aneurysm would have ruptured into the pericardium, as well as into the left auricle had life been much prolonged."

Mr. SHILLITOE, 15*th of December*, 1857.

---

12. *Aneurysm of the Arch of the Descending Aorta.*

I was called to visit C. B. on the 15th of August, at ten in the evening, and found him labouring with frightful dyspnœa; sitting nearly upright, with his head thrust back, face and lips blue, hands and feet cold, voice hardly audible, etc. He was æt. 35, and by trade a pipemaker; he had indulged freely in drinking, and had been laid up with sore throat and acute bronchial disease in January and February last. His mother had died at an advanced age, with asthma and heart-disease, in November last; so that it was considered that he inherited his mother's complaints. He had been an out-patient at the Hospital for some months, where the physicians considered his case to be one of chronic laryngitis and bronchial obstruction, without absolute disease of the lungs. Mr. Thomas Forder, the district medical officer, was now in attendance, and the symptoms were so urgent

* "Med. Chir. Trans.," vol. xxi.

† "Transactions," vol. iii., 1850-51, 1851-52, p. 284. See also paper "On Malformation of the Aortic Valves, as a cause of Disease."—*Monthly Journal of Medical Science*, 1853, Case 2; and remarks before.

that we attempted to give him relief by making an opening between the thyröid and cricöid cartilages, and left him for the night with improved pulse, and able to swallow wine, æther, etc.

On the 16th, he had had some hours sleep, and had taken slight nourishment, but became worse at night, and died early on the morning of the 17th.

I assisted at the *post-mortem examination*, the accommodation for which was very inconvenient, so that the investigation was confined to the neck and thorax.

The larynx, trachea, and bronchial ramifications were much thickened and enlarged, the lungs gorged with black blood, and the heart rather flabby, but not enlarged; the semi-lunar valves of the left ventricle were crumpled and ossified, and the aorta arising from it much enlarged, and studded with ossific deposit, bulging out above the left lung into an enormous sac, filled with firm coagulum, weighing about two pounds. The arch was continued from this in an enlarged and thickened state; the innominate, right and left carotid, and sub-clavian arteries participating in this expanded condition. These vessels, with the trachea and œsophagus, being divided in the neck, the contents of the thorax were turned down, and the descending aorta divided close to the diaphragm. The heart, with the sac rather torn from its adhesions to the pleura costalis—and the arch of the aorta, with its branches and the descending portion—were then separated and brought home, as well as the coagulum, and the whole immersed in a solution of bichloride of mercury and hydrochloric acid. On further investigation, after a day or two, I was much surprised to find that there was no communication between the dilated arch, and the descending or thoracic aorta; and that, even on inflating it from below, air escaped only by a small vessel, the size of a crow-quill, which penetrated it obliquely, about midway from above, downwards. In order to satisfy myself more fully as to the impermeability of the descending aorta towards the arch, I slit it up with scissors, and then found a firm clot of fibrinous deposit adhering, but easily detached from the sealed extremity towards the arch; the whole tube was also more or less covered with bony deposit and inelastic, so that it appeared to have been deprived of its functions in the general circulation, and some

progress seemed to have been made in the process of filling up, in the same way as in the aneurysmal sacs above.

These circumstances tend to explain the great development of the innominate, carotid, and sub-clavian arteries, by means of enlarged branches, from which the arterial circulation must have been carried on from above downwards; and it is to be regretted that our *post-mortem* investigation did not extend beyond the thorax, as some important and enlarged anastomoses within the branches of the abdominal aorta might have been discovered; but as the laryngitis and bronchial obstruction, with congestion of the lungs, were considered as the most prominent causes of death, the aneurysm was regarded as only an accidental accessary; nevertheless, the enlarged and thickened vessels pressing on the trachea, and the sac encroaching upon the left cavity of the pleura, may have had no small share in producing or seriously aggravating these fatal symptoms. It is clear also, that had the man been sober and less exposed to vicissitudes of temperature necessarily connected with his trade, the bronchial symptoms might not have been so serious, and there would have been a fair chance of spontaneous cure of the aneurysm, by the gradual development of the collateral circulation. The strong pulsations of the vessels in the neck, and the great hoarseness in the voice, appear to be the chief symptoms that were noticed in relation to the aneurysmal disease, which must have been of many years duration.

Mr. T. Smith for Mr. C. Mayo, 15*th of December*, 1858.

---

13. *Rupture of the Abdominal Aorta in a Child.*

A child, æt. 7½ years, had suffered from palpitations from her earliest infancy. When first seen, five weeks before death, there was extensive dulness in the præcordial region, and a systolic bellows-sound, loudest at the apex, with violent action of the heart. A few days before death she began to complain of severe aching pain in the legs, principally referred to the knees and wrist, in the erect posture. On the 5th of December, 1857, whilst sitting up, she had an attack of convulsions, followed in a quarter of an hour by another. Death occurred within an hour after the seizure.

Post-mortem examination.—Heart uncovered by lung to about double the usual extent. Small patch of tough, false membrane, the size of a fourpenny piece on the front of the heart, smooth on its surface, and apparently old. Heart firmly contracted, empty, weighing, with the large vessels cut off close, four ounces; valves smooth and not thickened; mitral valve short, especially the posterior flap. Peritoneum covering the pelvic organs blood-stained, and on removing it a very large clot was found covering the iliac muscles, dipping deep into the pelvis which it half filled, and passing upwards behind the peritoneum to the kidneys, on each side. This blood had escaped from the rupture in the aorta at its bifurcation.

The aorta being divided at the origin of the inferior mesenteric, and slit up, as well as the two iliacs, along the front of the vessels, it was found that it had given way at the bifurcation, and that rather more of the left iliac had yielded than of the right. The edge of the artery at the bifurcation and in the left iliac was like a clean cut, but from the right iliac a large shred was hanging. The intervening space was occupied by a kind of sac of the size of a walnut, with thin ragged walls, formed of blood, which by its browner colour contrasted with the more recent and larger extravasation.

On the posterior wall of the right iliac, commencing at the bifurcation, and extending for about four lines in the direction of the vessel was a patch about half a line in breadth at its centre, and gradually tapering towards each end. Over this extent the interior and part of the middle coat of the artery had disappeared. It seemed to be an earlier stage of the same process which caused the adjacent rupture. Just at the distal end of this patch was a minute point in which the same change has taken place. No atheroma or roughness existed in the coats of the arteries. All the other organs healthy, but very anæmic. No recent specimen could be obtained for the microscope. The specimen is now in the Museum of the College of Surgeons.

Dr. Armitage, 15*th of December* 1857.

---

14. *Contraction of the Mitral Orifice, with extensive fibrinous deposits in both Kidneys.*

A woman, æt. 36, had had six attacks of rheumatic fever, the first, fourteen years ago, being attended by pericarditis. When under observation, she had most of the usual local and general symptoms of extreme hypertrophy of the heart and contraction of the mitral orifice. No valvular murmurs existed. There was considerable dropsy, and hæmoptysis; no albumen in the urine.

Heart universally adherent to the pericardium. Mitral orifice only just admits the little finger, but the surface of the funnel-like opening is smooth. Great hypertrophy of the heart; no disease of other valves. Pulmonary apoplexy.

Kidneys unusually adherent to the surrounding areolar tissue, so that their removal was attended with difficulty. Capsule firmly adherent. On removing it, bright yellow patches were seen about the size and shape of the original lobes, but many coalesced, and were separated from each other and from the remaining kidney structure, by a border of intense congestion. On section the same appearance was seen. This change occupied about three-quarters of one kidney, and about one-half of the other. In both, the pelvis and infundibula were free. Under the microscope, the bright yellow material seemed to consist of granular matter and oil globules. Dr. Armitage, 15*th of December*, 1857.

---

15. *Cancerous Nodules in the Substance of the Heart.*

This specimen came from a man who died of cancer of the stomach, liver, lungs, etc. In the substance of the left ventricle, and on its exterior, were three or four small cancerous nodules, the largest about the size of a pea. It constituted the exceptional case, which proved the rarity of this form of disease; for, although the heart may be involved in a cancer growing into it from the lungs, or deposits may occur on the pericardium, such an instance as the present could not be found among the *post-mortem* records of Guy's Hospital, kept during the last twelve years, and in which nearly three thousand bodies had been examined.

Dr. Wilks, 15*th of December*, 1857.

16. *Abscess? in the Pericardium.*

J. H., æt. 63, single, in a state of melancholia, of twelve months' duration and from hereditary predisposition on the mother's side, died on the 29th of November, having been ten months in the Infirmary of the Somerset County Asylum, and during the whole time in a very feeble state, requiring to be forced to take food.

Previous to his admission, whilst in the Workhouse, he received a blow on the right eye, wounding the cornea, and causing an inflamed state, which continued more or less for several weeks. At the end of six months his health had improved, and he took his food without being forced, and went out occasionally. In August, he had an attack of erysipelas of the head, and he was confined to bed for several days; after that his general health again improved, and he became rational, but was in too feeble a state to be discharged, his home being in a distant part of the county. On the 28th of November, only the day before his death, he declined taking food, and remained in bed, and in attempting to get out, for the attendant to change his linen, he fell on the floor, slightly wounding the scalp which bled freely. On the following morning he seemed to have rallied, but in the afternoon he sank and died.

Post-mortem examination.—The brain was unusually large, weighing fifty-one ounces, and was firm; on the right side of the cerebellum about half a drachm of blood was effused, and there were about two drachms of clear fluid in the cerebral ventricles.

Chest.—In the apex of the right lung were two miliary tubercles the size of swan-shot, in the lower portion, and at the back of the upper lobe was a tubercle filled with cheesy matter the size of a filbert; both lungs were collapsed, hidden by the pericardium which was prominent, and at the apex of the heart was, what appeared to be, an abscess which contained about one drachm or one drachm and a half of pus; the pericardium was closely adherent to the heart, and the adhesions seemed to be of old standing. The abdominal organs presented nothing unusual. There was no complaint

made, or apparent symptom present at any time, to lead to the suspicion of cardiac disease; the injury to the eye, erysipelas of the head, and disinclination for food, being the prominent features of this case, to which attention was directed whilst in the Asylum.

Mr. Obré, for Dr. Boyd, 15*th of December*, 1858.

Report on this specimen.—At the posterior aspect of the apex of the heart, or at the most dependent part of the pericardium, there is a small cyst, measuring fifteen French lines in its transverse, and ten lines in its longitudinal diameter. This cyst is lined by a membrane partly reticulated, and partly smooth and shining, and its walls are formed by dense fibro-cartilaginous false membrane. The cavity has no connection with the muscular substance of the heart, being separated from its surface by the visceral layer of pericardium in a thickened state, and a layer of loose cellular tissue. It is also separated from the diaphragm by similar false membrance. The pericardium is, in every other part, adherent to the heart by old cellular attachments.

The term, abscess of the heart, is certainly inapplicable to this specimen, and the cyst is, most probably, the remains of pericarditic effusion of very old date. Similar cysts are occasionally seen in cases of pleuritis when the disease is of very long standing, and the fluid nearly absorbed.

Mr. J. Hutchinson, 19*th of January*, 1858.

---

17. *Case of Sudden Death from Contraction of the Mitral Orifice, and its Obstruction, produced by a Globular Vegetation detached from the Left Auricle.*

This specimen of a detached fibrinous coagulum, or "globular vegetation," was found in the left auricle of a woman æt. 25, who died very suddenly in the Middlesex Hospital. She had been suffering for twelve months from shortness of breath, palpitation, frequent catarrh, and troublesome cough. During the three weeks preceding her death, she complained of œdema of the legs, ascites, orthopnœa, and frequent cough. It is noted that "the

heart's action was rather forcible, with mitral regurgitant bruit;" and that she "never had rheumatism." The urine was very albuminous, but contained no casts of tubuli. On the 4th of November, after breakfast, she suddenly fainted; she was seen almost immediately by the house-surgeon, Mr. Tatum, and then appeared insensible; the pulse was scarcely perceptible; the heart's beat was strong and quick; respiration gasping. The heart's action ceased in about a minute; she then gasped four or five times, and died.

Post-mortem examination.—The heart was found enlarged, weighing fourteen ounces and a half. On opening the left auricle, an irregular, shaggy-looking mass was seen sticking in the mitral orifice. When it was washed out and floated in water, it assumed a sac-like appearance, and was about the size of a pigeon's egg. The portion required to complete the sac or capsule was found adherent to the inner surface of the auricular appendix by means of fibrinous bands and processes, which were entwined in the musculi pectinati. Three or four smaller globular bodies, about the size of peas, were found in the left auriclar appendix, similarly fixed. On squeezing one of these, it burst, and yielded a thick greyish, purulent-looking matter, which seemed to form the contents of a capsule, similar to, but smaller than the one found detached in the auricle. There can be no doubt but that the larger capsule was of exactly the same nature as the smaller ones and that they all were fibrinous coagula, in which the central portions had softened or broken up. There was no actual organic union between any of these coagula and the walls of the auricle. The mitral orifice was much contracted, and measured only four-tenths of an inch in diameter. The cordæ tendineæ of both flaps of the mitral valve were much thickened and shortened; the apices of both papillæ to which the cordæ were attached presented a white fibröid appearance; some small warty vegetations projected from the free margins of the contracted mitral orifice. The aortic valves were perforated by several small openings; and on the posterior wall of the left ventricle, half an inch below the aortic valves, the endocardium presented a thick, rough patch, resembling a cicatrix, about the size of a shilling. The brain was healthy, and there was no obstruction in any of

the vessels. In each lung there were two or three firm black masses of recent apoplexy, each about the size of a hen's egg. The liver was nodulated and granular; and, on section, presented radiating patches of extravasated blood. The spleen was marked by a depressed, firm fibröid patch, extending half an inch into its substance. The kidneys were granular; on section, the right at its upper end exhibited a firm yellow patch, extending as deep as the cortical substance, and about two inches in length; at about one inch from this was a smaller yellowish patch, not so firm as the large patch, and more granular; near the lower extremity were three or four cysts, about the size of peas; the left kidney was marked by a superficial yellowish patch.

Remarks.—The origin of these coagula in the left auricle is to be accounted for by the impediment to the circulation caused by the contracted mitral orifice; and the situation of the coagula in the auricular appendix is due to its being furthest away from the circulating current. The interest of this case is connected with the mode in which fibrinous coagula in the heart may produce sudden death. For the pathology of these coagula I must refer to an excellent paper by Dr. Bristowe, in vol. vii. of the Society's "Transactions." Dr. Van der Byl, *5th of January*, 1858.

---

18. *Perforation of the Septum Ventriculorum; Clots in some of the Pulmonary Arteries, undergoing various changes.*

W. R., was admitted into St. Bartholomew's Hospital, on the 8th of October, suffering from the ordinary symptoms of dilatation of the heart, with disease of the aortic valve. He complained of dyspnœa, and, from time to time, experienced pain, of a fleeting character, about the left side of the thorax. He gradually sank, with general anasarca, and died on the 26th of October.

The body was examined fourteen hours after death. The heart was considerably enlarged, owing chiefly to a dilatation, without material hypertrophy, of the left ventricle. Its muscular tissue was pale, but free from fatty degeneration.

The endocardium lining the left auricle was slightly thickened. The mitral valve was natural. The aortic valve consisted of two cusps, the anterior being the larger. Each was rough and wrinkled upon its ventricular aspect, with considerable thickening about its base, and about, what should have been, its thin unattached margin.

A ridge on the inner surface of the aorta remained as the indication of a third cusp, and assisted with its fellows to bound the three sulci usually found between the valve and the arterial wall. The aorta was the seat of slight atheromatous degeneration. Water when poured into its canal did not escape into the ventricular cavity.

The thickening observed about the base of the aortic valve prolonged itself over the adjacent endocardium. Below the junction of the two cusps, at a point corresponding with the centre of the greater flap of the mitral valve, a circular opening perforated the septum ventriculorum. Its edges, bevelled off, and smooth, were clearly defined. The endocardium immediately around it was slightly roughened.

The left cavities contained a few coloured shreds of coagulated blood; the right were occupied by firm separated clots.

The right auricle and ventricle were dilated. The pulmonary valve was natural. The tricuspid was also, in great part, free from disease; but, opposite the opening in the septum, between the large cusp which overlays the entrance to the pulmonary artery and the adjacent smaller one, a mass of decolourized fibrine was firmly attached to the surface, and covered, valve-like, the above-mentioned aperture. To the right side, many smaller coagula clung firmly to the auricular surface of the adjacent cusp. On detaching them, a rough and slightly excavated surface was exposed.

The presence of the valve-like portion of fibrine prevented the passage of the blood from the right to the left ventricle, but offered a very slight obstacle to its escape in the opposite direction.

Viewed from the right side, the perforation of the septum presented a slightly irregular outline, many minute granules projecting from its margin.

The tricuspid valve, though hampered by the clots referred to, sufficed to close its orifice.

The right lung presented a natural appearance. In the left, one of the tertiary divisions of the pulmonary artery was occu-

LIGN. 4

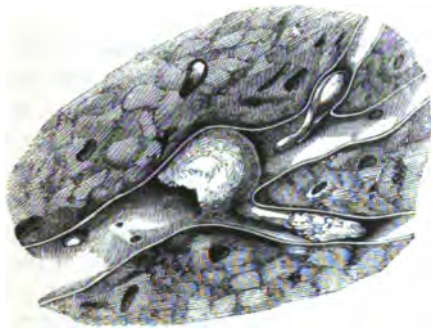

Part of the left lung, with the clots occupying branches of the pulmonary artery.

pied by a thin layer of decolourized fibrine, in the form of a hollow globule (Lign. 4). By means of a small aperture on its cardiac side, the blood had access to its interior. Its inner wall was marked with rugæ. Its outer was smooth, and fitted closely to the parts around. It contained a soft, coloured coagulum. Its diameter was about two lines greater than that of the artery below, so that at this point the vessel seemed to have undergone some slight dilatation. Just beyond the point at which this clot had obstructed the canal, the artery bifurcated. The blood had penetrated one of its divisions by means of a short and narrow channel, formed by the side of the above-mentioned clot. Beyond this channel there existed a firm, fawn-coloured coagulum, broad at its base, pointed at its further extremity. Its interior, hollowed out, and occupied by fluid blood, was stained of a deep red colour.

The other division, completely isolated, contained a firm, shrunken, clot, which occupied about one half of the diameter of

the canal. This clot formed the appendix to a coagulum, the size and shape of a pea, which filled the artery beyond at a point where it again bifurcated. Unlike the others this clot was solid throughout, colourless externally, within of a pinkish tinge. It clung, but was not adherent, to the adjacent wall of the vessel. The portion of pulmonary tissue with which this artery had communicated was in a state of gangrene, as also was its plural covering.

The aspect of these decolourized coagula closely resembled that of the fibrine covering the aperture in the septum. The last-mentioned clot seemed to have been but little, if at all, influenced after its first lodgment by the action of the blood. Its surface was round, smooth, and polished. The two remaining coagula had been subjected to the influence of the current of the blood. In the case of the one the hollowing out of the coagulum seemed to have been attended with a dilatation of the remaining shell, with yielding of the surrounding structures. In the case of the other, the blood appeared to be boring a channel for itself through the centre of the clot. Had this process been continued the perforation might have been completed, and the canal restored, narrowed of course by such remainder of the coagulum as might still cling to the arterial wall.

This change may be not unfrequently observed in the mesenteric veins, obstructed by coagula during the course of chronic peritonitis, and in the pulmonary arteries in cases of phthisis. In such cases the canal of the vessel is often restored without dilatation, and independently of the tunnelling process, by the shrinking of

LIGN. 5.

LIGN. 6.

Lign. 5. Part of a superior mesenteric vein, with tunnelling of the obstructing coagulum.

Lign. 6. Pulmonary artery from a tubercular lung. Its interior contains a shrunken, but pervious clot.

the clot from one side,* and the consequent opening of a channel for the blood. With the exception of some venous congestion, the brain and the other organs presented a natural appearance.

Mr George W. Callender, 19*th of January*, 1858.

---

19. *Injected preparation of the Iliac Arteries from a Male Subject which presented an Example of Talipes Equinus on the Left Side.*

The right common iliac artery (that of the sound side) was larger in respect of its sectional area than the left, in the proportion of five to two.

The right external iliac, in respect of its sectional area was larger than the left external iliac, in about the proportion of three to one.

Mr. T. W. Nunn, 19*th of January*, 1858.

---

20. *Aneurysm of the Innominate artery, opening into the Trachea, with Obstruction of both Sub-clavian Arteries.*

The patient from whom this preparation was taken, was a man æt. 38, a pressman by trade, under Dr. Fincham's care in the Westminster Hospital. He was first admitted in July, 1857, having suffered from pains which he described as "spasms," for nine or ten weeks previously. His pulse was feeble, occasionally intermittent, and imperceptible in the right radial artery, the right hand and arm being colder than the left, and somewhat numbed. His chief complaint was of pain in the epigastric and cardiac regions, much aggravated in paroxysms, and shooting to the right shoulder and upper arm. He was unable to lie flat in bed, on account of the increase of pain produced thereby, and he had slight uneasiness in swallowing, referred to the top of the sternum. There was, at this time, a

* Museum of St. Bartholomew's Hospital. Series xiii., No. 131-133.

systolic murmur of moderate intensity, audible over the upper third of the sternum, in the carotids, and over the right infra-clavicular region; there was not that marked increase of intensity in the bruit as the stethoscope was moved upwards away from the base of the heart, as appeared later in the course of the disease, but it was clear that the sound had not its *maximum* at the aortic valves; the heart was, therefore, not regarded as the seat of the mischief, but rather the aorta or its innominate branch.

He left the Hospital after a short stay somewhat relieved, but was re-admitted on the 8th of December, 1857, complaining of severe and constant pain over the upper fourth of the sternum, and in the right infra-clavicular and clavicular regions, also of shooting pain up the neck and into the arms, so much increased by lying down, that for a considerable period he had been in the habit of sleeping in the sitting posture. The uneasiness on swallowing had increased.

Physical signs.—There was a slight projection of the sternum at a level with the second costal cartilage, and of the sternal half of the right clavicle, pressure producing an increase of pain in both these situations; there was deficient resonance over the upper third of the sternum, the sternal half of the clavicle, and also over the inner third of the infra-clavicular region; the respiration in these situations was very feeble, but no impulse was anywhere perceptible. The heart was heard beating with somewhat diminished impulse and without murmur; but over the sternum at the junction of the third costal cartilage, a faint murmur was audible, distinct from the heart's sound, and gradually increasing in intensity until it became a loud whizzing bruit at the right sterno-clavicular articulation. The bruit could be heard with equal intensity above the clavicle and along the right carotid, and to a less degree in the carotid of the other side. There was a very distinct thrill perceptible on placing the finger on the right carotid, and there was a slight distension of the right external jugular vein. Posteriorly, the breathing was generally feeble, but there was no deficient resonance. There was also no pain at any point of the spine.

On 23rd of December, he first complained of a cough, which was of a harsh tearing character, and on the 26th he spat up a small

quantity of muco-purulent matter, and complained of pain and uneasiness under the mid-sternum, in which situation, as along the upper sternum, tracheal breathing was very distinct. On the 30th of December, the expectoration was slightly tinged with blood. On the 6th of January, 1858, being then much exhausted with pain and want of sleep, he brought up, about 3 P.M., a considerable quantity of florid blood, and continued to do so until 10 P.M., when he died, having expectorated altogether about a porringer and a half full of blood.

Post-mortem examination.—The tumour was found to be caused by an aneurysm of the innominate artery pressing against, but not implicating the bony structure of the clavicle and sternum. On opening the trachea, a small ragged opening was found in its upper part communicating with the aneurysm. The arch of the aorta was dilated and extensively diseased, and on opening it, it was found that fluid would pass into both the carotids, but into *neither* of the sub-clavian arteries, the right being obstructed by the clot in the aneurysm, but the left obliterated close to the aorta, apparently by disease of old date. It is remarkable that the pulse on the left side, although weak, was so distinctly perceptible that no obstruction of the main artery was suspected. The right pneumogastric and recurrent laryngeal nerves were stretched over the tumour caused by the aneurysm.

Mr. CHRISTOPHER HEATH, 19*th of January*, 1858.

---

21. *Aneurysm of the Ascending and Transverse Aorta. Death in about three years from Asthenia, the Sac being unruptured. Supervention of Gangrene of the Nose, three days prior to Death.*

T. B., æt 59, a strongly-built man, of temperate habits, by trade a sawyer, had been ailing upwards of two years. His earliest symptoms were, irritability of the stomach and vomiting, with pain in the situation of the second and third left costal cartilages, darting through the chest to the shoulder blade. Some months subsequently, a pulsating tumour was discovered in the spot named, which rapidly increased. He now suffered from difficulty of breathing, and could only lie upon the right side, and, even in this position, not without pain. At the end of about two

months, however, this difficulty subsided, and he could again lie in any position without much inconvenience. He gradually lost flesh and strength, and his complexion acquired a sallow, unhealthy tinge. Much pain was felt in the swelling, and dyspnœa was induced upon the least exertion. There now supervened, a very peculiar, hoarse, grunting cough, paroxysmal in character and unattended by expectoration. He suffered too, at times, most severely from pain in the epigastrium. His vision was dim and pupils dilated. The extremities generally cold. Occasional attacks of suppression of urine, and lumbar pains were experienced. About this time, a strong heaving systolic and diastolic impulse, without fremitus, was felt over the sac, which presented altogether to the left about the second and third ribs. A murmur was also heard of variable intensity, at times hoarse, attending one or both sounds. But sometimes the second sound over the sac was very loud and clear. After the symptoms and signs had continued some months without any very remarkable alteration the impulse gradually diminished in force, became single, and the murmur also was faint and distant. The sac appeared gradually becoming filled with firm fibrinous deposit. The dyspnœa by degrees passed into orthopnœa. The peculiar cough continued unabated. Dysphagia soon increased to so great an extent that only small quantities of liquid could be swallowed. About three days before death gangrene of the lip and alæ nasi occurred, and, was extending up to the time of death. The left radial pulse could not at last be felt.

Post-mortem examination.—A globose tumour, larger than a full-sized fœtal head, was found occupying the upper and central portions of the chest with an extensive bearing to the left, extensively displacing the lung, and producing erosion of the second and third ribs and their cartilages. The dilatation of the ascending aorta commenced just above the auricle, its walls, in front, as high as within an inch of the tumour, being slightly thickened and atheromatous, but smooth upon the interior. On the posterior surface of the artery, the walls gave way to form the sac, and were much changed in structure. The sac was nearly filled with dense fibrinous deposit of honey-comb-like aspect, having a channel passing almost directly backwards, immediately below and to the right of the origin of the innominate, carotid,

and sub-clavian arteries. The posterior and lower part of the tumour, pressed downwards and backwards upon the right pulmonary artery, which was stretched flat upon the sac and dilated to a remarkable extent, being two inches in diameter. In the left pulmonary artery, a fibrinous mass, three-quarters of an inch in diameter, was observed, lying flat upon the portion of the wall adherent to the sac, and connected by a pedicle with an elevated patch situated upon the same side, and commencing at the origin of the artery. The left auricle and pulmonary veins were slightly compressed. The left innominate vein was pervious only in the lower third, the upper portion of the tube being closed by adhesion. The left bronchus was nearly flattened, and the œsophagus much compressed. Marked hypertrophy of the heart existed, and very general adhesion of the pericardium.

The recurrent nerve was traced, apparently not much compressed; but various branches of the sympathetic nerves had been obviously submitted to pressure. One kidney was very large, and of horse-shoe form.

Dr. Cockle, *2nd of February*, 1858.

---

22. *A large, tough, fibrinous Clot, from the Right Ventricle of the Heart.*

W. S., a butcher by trade, was admitted into the Hope Ward of St. George's Hospital, on the 21st of December, 1857. He had been subject to cough from childhood. On the 10th of the month, he was seized with rigors, followed by cough with profuse expectoration, and extreme dyspnœa; and these symptoms had continued to increase in severity up to the time of his admission.

There was then excessive dyspnœa, with orthopnœa, constant cough, and profuse muco-purulent expectoration. The respirations were 56 in a minute. His face, lips, and nails were livid; the skin was hot and dry; the tongue furred and white; bowels costive; urine loaded with lithates, not albuminous, specific gravity 10·22; pulse 136, weak. There was little expansion of the chest, which was unusually resonant on percussion, especially on the left side. Throughout the chest, the respiratory murmur was marked by loud, sonorous, rhonci, and occasional

large bubbling sounds. The heart's impulse was feeble; its sounds were clear.

The remedies employed consisted of emetics, followed by salines, with squill and tartarized antimony, and the external application of a blister and turpentine fomentations. Under this treatment he so far improved that, by the 28th of the month, he could lie flat in bed; the cough and expectoration had greatly decreased, the extreme lividity of the surface had passed off, and the respirations had fallen to 28, and the pulse to 104 in a minute. He continued in much the same state, fairly comfortable, for two days; but on the 31st, a marked increase was observed in the lividity of the countenance; the pulse rose to 120, and was excessively feeble and unequal; the respiration became more hurried (32 in a minute), and extreme drowsiness supervened. There was no increase of cough or expectoration; day by day the cough decreased, but the other symptoms became gradually worse, the lividity more intense, the drowsiness more constant, the respiration quicker, the pulse weaker and more irregular. On the 7th of January, he fell into a semi-comatose state, from which he could hardly be roused; and on the 8th, he expired gradually.

The *post-mortem examination* of his body was made thirty-six hours after death. The heart weighed fifteen ounces; it was healthy in structure, its walls were somewhat thick, its cavities large, its valves in a normal condition. Large clots existed in all the cavities; in the left cavities they were straw-coloured, and of a gelatinous texture; on the right side they were tough, white, and opaque. The clot in the right ventricle was firmly adherent to the lining membrane of the ventricle, and was entwined around the columnæ carneæ. Towards the apex of the heart, its centre was broken up and diffluent, forming a thick, brownish-white fluid.

Both lungs were adherent to the costal pleura by old and firm adhesions. The lining membrane of the bronchi was congested, and the air-passages contained a considerable quantity of frothy mucus. Both lungs were emphysematous.

The liver weighed two pounds and a half. It was contracted and puckered on its surface, and when cut, presented a nutmeg appearance.

The spleen was very firm, and congested, and weighed eleven ounces.

The kidneys were congested, but healthy, and together weighed twelve and a half ounces.

Remarks.—Two questions arise in connection with this case: viz.:—as to whether the clot found in the right ventricle was formed long prior to death; and, if so, whether it was not the efficient cause of death. There can be little doubt, that the large, tough, decolourized clots (not the gelatinous clots) sometimes found in the different cavities of the heart, adherent firmly to the walls, are formed only in cases in which the blood is highly fibrinized, and at a period when the circulation is extremely languid, or during slow death. That, in certain instances at least, such clots must exist for some time prior to death, is evident not only from the history of the cases, but from the fact that the centre of the clot is diffluent; so that, when the clot is cut open, it presents a cavity containing matter which, to the naked eye, resembles pus, and which in fact, though not purulent in its nature, consists of broken-down fibrin. So it was in the instance before us. The character of the clot and the history of the case alike point to the long existence of the clot. The cough and dyspnœa had greatly subsided, the orthopnœa had ceased, and the lividity of the surface had, in great measure, passed off, when, eight days before death—without any increase of the cough or dyspnœa, and without any increased loading of the bronchi—the lividity began to recur, and, coincidently with its recurrence, the pulse became unequal and irregular. From that time until the day of his death, the irregularity and feebleness of pulse and the lividity of the surface became gradually more striking, in spite of the gradual cessation of the bronchial symptoms; and after death, though the bronchi were found congested, there was not much secretion in the bronchial tubes, and there was nothing in the condition of the pulmonary organs to account for the fatal issue. Indeed, the presence of the clot in the right ventricle, appeared to afford the only feasible explanation of his death; and my own conviction is, that if the ventricle had not been thus blocked up, the patient would have

recovered. My interpretation of the case would be, that the clot began to form during the extreme obstruction to the pulmonary circulation, which existed at the date of the patient's admission into the Hospital; that it gradually increased in size; and that, about the 30th of December, it began to form a serious obstacle to the circulation, and, from that date, formed almost the only serious impediment to the proper circulation and aeration of the blood. Dr. FULLER, *2nd of February*, 1857.

---

23. *Ossific Deposit at the Left Auriculo-ventricular Orifice; Concentric Hypertrophy; Cyst of Kidney, and Contracted Pylorus.*

This specimen is one of ossific formation on the lower edge of the left auriculo-ventricular orifice. A hard, projecting body of the size of a smallish orange-seed, is found at the lower surface of the attached border of the laminæ of the mitral valve. It is very hard, white, rough on its surface, and is covered throughout with endocardium of a healthy character. The ossific formation has the appearance of organization.

The microscope reveals fine lamellæ and canals. The part exhibited, comprises the whole of the left auriculo-ventricular ring and the mitral valve. The ring was materially reduced in size, decidedly contracted, and the inner surface felt more than usually rough and uneven. From great firmness of the ring, due to very minute ossified plates, that part remained more than usually patent. The laminæ of the mitral valves are firm, rather deficient, and opaque. The heart from which this specimen was taken, was greatly hypertrophied. The hypertrophy was concentric. That organ was the size of the head of the infant at birth. Its firmness was very great, almost that of the infant-head, and in weight it appeared to be fully three pounds. The muscular fibre was red and firm; the walls of the left ventricle were about two inches thick. The cavity would not hold more than two ounces of liquid. When a transverse section of the heart was made, the thickness of the walls contrasted remarkably with the diminutiveness of the cavity. The right ventricle was larger, the cavity was greater, while the walls were thinner. The auricules were dilated, but not very much; the left was more dilated than the right.

All the cavities, all the great veins, the aorta and the pulmonary artery were filled with coagulated blood; the upper parts being amber-coloured, the more depressed, very dark. No morbid alteration whatever was found in the semi-lunar valves; a few small, recent, cretaceous points, perfectly level with the surface of the tube were found in the ascending aorta.

This other specimen which I exhibit, is the upper part of the right kidney. It presents a cup-like depression, made by a large cyst, about the size of a small hen's egg. The diameter of the depression at its brim is about one inch, and the depth of the depression is about half an inch. The kidney was rather small, no other cysts were found; no fatty degeneration was made out by the microscope. The left kidney was healthy, rather larger, long, and somewhat lobulated.

This third part is the pyloric end of the stomach, and the commencement of the duodenum. The mucous coat is healthy, but the muscular coat is thick and firm. The specimen is remarkable for its great contraction. It was with difficulty I passed my little finger through the pyloric orifice. The stomach generally was much reduced in size. The specimen shews how much the pyloric orifice of the stomach may be reduced by simple contraction of the muscular coat. The patient had been a small eater, and never suffered from stomach disorder.

History.—The person from whom these parts were taken was a gentleman, æt. 68. When a boy of fifteen, he suffered from violent palpitation of the heart, and ever after was occasionally annoyed with tumultuous action of that organ. In other respects he enjoyed good health, took much exercise, and though a spare and rather delicate man, did not regard himself as in bad health till the end of December. He then suffered from distress at his heart, from dyspnœa, and soon after, finding his feet swell, he came to town.

On the 24th of December, he called at my house, and I then found the heart to be seriously implicated. There was a voluminous, quick, yet, as it were, a distant movement of the organ, felt below the nipple, and below the lower end of the sternum. The first sound of the heart was feeble, and over an area of three square inches, a point a little below the left nipple, being its centre; a

gentle, blowing, systolic murmur was heard. Over the sternum no murmur whatever was perceived, and at the middle and upper part of that bone, a bold, highly-pronounced second cardiac sound was heard. By means of the differential stethoscope, with one cup under the nipple and another on the sternum, the acoustic differences of the two regions were well made out; so much so, that at once I felt assured the aortic orifice was healthy, and the mitral orifice diseased. The feebleness of the first sound at apex, its apparent distance, and the absence of the violent knock or heaving of mere hypertrophy, and of the slap caused by dilatation, suggested the presence of fluid in the pericardium.

The absence of respiration at the base of the chest pointed to fluid in the pleura. The pulse was rapid and small; the recumbent position impossible. Anasarca of legs; urine very scanty; no albumen.

The patient improved much for some days, the heart was calmer, and the fluid was partly removed from the chest; but dyspnœa soon became very urgent, the general strength failed, and he died on the 23rd of January, less than a month from his first visit to me.

It is worthy of notice, that in this case there was present a family disposition to disease of the heart. A brother, æt. 70, is now suffering from great dilatation of the heart, with aortic obstruction. A sister and a nephew died very lately of organic disease of the same organ.

The *post-mortem examination*, besides the facts already stated, discovered the presence of thirty ounces of fluid in the right side of the chest, about fifteen in the left, and six in the pericardium. Lungs, liver, and other organs presented no material morbid condition.

The case presents these remarkable features:—Great duration of disease of the heart, extending to upwards of fifty years; rapid destruction of life after effusion commenced; great muscular development of the heart. Extraordinary contraction of the stomach, without the presence of any disease of the coats. The presence of a large cyst in the kidney, without giving rise to any symptom during life.

Dr. S. Scott Alison, *2nd of February*, 1858.

24. *Aneurysm of the Transverse Arch of the Aorta, fatal by Rupture into the Pericardium.*

J. W., a smith in Woolwich Dockyard, æt. 40, was admitted into St. Thomas's Hospital under my care, on the 4th of December, 1857. He stated that he had enjoyed good health until eight weeks ago, and that he had never, so far as he knew, strained or otherwise injured himself, although his occupation had been somewhat laborious. He had been in the habit of drinking a considerable amount of beer, and occasionally, of spirits.

Eight weeks before admission, he was seized with pain in the left wrist, extending up the arm into the shoulder, across the chest, and down the right arm. The pain in the last situation, persisted only for about a fortnight; but that in the chest and left arm has continued, off and on, up to the present time. From the first he had darting pains at intervals in the region of the heart, but for the last four or five weeks they have been constant. During the last ten days he has had considerable difficulty of breathing, and cough, with expectoration of transparent mucus; he thinks he has been losing flesh, and becoming pale in the face.

At the time of admission he was labouring under frequent cough, with a pretty copious expectoration of transparent mucus; he had much difficulty of breathing, so that he was unable to lie down for any length of time. His pulse was small and feeble, but regular and equal at both wrists. His tongue was clean, and all his digestive functions were healthily performed. The upper part of the sternum, and the left clavicle, were thrown a little forwards, and there was a slight fulness at the lower part of the throat. The anterior part of the left side of the chest, from the clavicle to the nipple, was considerably more prominent than the corresponding portion of the right, and presented marked pulsation—pulsation more pronounced than that over the cardiac region itself. There was complete dulness from the clavicle nearly as far down as the nipple, and from the centre of the sternum to a line leading vertically downwards from the junction of the middle and outer thirds of the clavicle. Below, this merged into the heart's dulness, which seemed to occupy rather a lower,

and at the same time, rather a larger space than usual. Over the area in which abnormal dulness existed, there was a distinct, but not intense, blowing, systolic murmur, which was loudest immediately below the centre of the clavicle. The heart's sounds were feeble at the base, but perfectly healthly at the apex. The remainder of the left side of the chest, and the whole of the right, were resonant throughout; and the breath sounds, (excepting that they were mixed, here and there, with slight rhonchus and subcrepitation), were healthy. The systolic murmur was feebly audible over the left scapular region.

He was treated, during the greater part of his stay in the Hospital, with small doses of antimony, and occasional laxatives; and although there was no change whatever in the local signs of disease, his general health appeared, on the whole, to improve; so much so, indeed, that he began to talk of returning home. At eight o'clock in the evening of the 3rd of January however, exactly a month after his admission, while sitting-up in bed engaged in conversation, he was suddenly seized with pain in the region of the heart, gasped a little, and died in less than five minutes.

Post-mortem examination.—Body of ordinary stature and in good condition. There was a decided protusion of the ribs in the upper third of the anterior surface of the left side of the chest.

On opening the chest, a large fibrous-looking mass (continuous with the upper part of the pericardium and the tissue of the anterior mediastinum) was found occupying the upper third of the left side of the chest, and adherent to the parietes in front. It extended from the apex down to about the fourth rib, and from the right margin of the sternum, to nearly the extreme left of the left side of the thorax. The apex of the right lung was attached to its right margin; and the upper lobe of the left lung (displaced by it backwards and downwards) was adherent to its lower two-thirds, and (gradually becoming thinner) was prolonged upon its lower part to within about two inches of the sternum. The pericardium was pushed a little downwards, but occupied rather more than its usual area, looked distended, and had a bluish tint.

The contents of the chest were now removed in mass, and

examined more carefully. The pericardium was opened, and found to contain a large quantity of blood-stained serum, together with twenty ounces of soft, recent, coloured coagulum, which completely surrounded the heart and was prolonged into all inequalities. The heart was of ordinary size and firmly contracted; but somewhat tilted, so that the right edge of the right ventricle faced almost directly forwards. The auricular appendages were just visible, but the origins of the aorta and pulmonary artery were completely concealed by, what appeared to be, tolerably firm fibrous adhesions between the under surface of the mass before alluded to, and the upper and anterior surface of the right ventricle, together with the contiguous portion of the left. To the right of the adherent portion was discovered a rupture, large enough to admit the tip of the little finger, which had produced a communication between the cavity of the tumour and that of the pericardium. The valves of the heart were healthy, and its ventricles contained a trace of coagulum. The right lung was very firmly adherent to the parietes. It was large, congested, and œdematous, but crepitant for the most part throughout. Its apex contained a good deal of indurated tissue, with a few chalky and putty-like masses. The left lung was small; its lower lobe was congested and œdematous, but crepitant; its upper lobe was much reduced in size, and spread over the lower two-thirds of the left half of the tumour; it reached higher behind than in front, and in the former situation was crepitant, but it diminished in thickness, and became more and more empty of air towards its anterior edge. The bronchial tubes of both lungs contained much thin frothy mucus, but otherwise seemed healthy. The larynx, trachea, and œsophagus took their normal course and were perfectly natural. Since neither the origin of the aorta nor that of the pulmonary artery were visible from the front, the vessels were examined from behind, the auricles (which were healthy) having been first detached. The pulmonary artery and its primary branches were perfectly healthy, but owing to the pressure of the tumour above it, the course of the trunk was more directly backwards from the beginning than usual. The pulmonary veins were healthy. The ascending and descending portions of the arch of the aorta were both of them a little dilated and

irregular—the irregularity being due to unequal thickening of the internal walls of the vessel. The same kind of irregularity, only in a more marked degree, existed in the posterior wall of the transverse arch; but the anterior wall was replaced by a large orifice, through which this portion of the vessel communicated with an aneurysm about as large as a cocoa-nut, which formed the tumour already several times referred to. It is impossible to assign any dimensions to the orifice, since the walls of the artery at both ends, and still more above and below, expanded in a funnel-like manner to take part in the formation of the aneurysm. The origins of the arteries springing from the arch remained connected with the comparatively healthy portion of the vessel, but the intervals between them were widened, and the innominate was dilated. The parietes of the aneurysm were thick, tough, and fibröid, and presented, here and there, a little earthy matter. They were united by their outer surface, as before-mentioned, to both lungs, to the heart, and to one or two other parts, and were continuous also, in several situations, with a considerable quantity of condensed cellular tissue. On examining their inner surface, there appeared to be no definite line of demarcation between them and the arterial walls, and indeed, many parts of the lining membrane of the aneurysm bore a close resemblance to that of the vessel. The aneurysm was almost completely filled with coagulum, a large portion of which was laminated, and adherent, with some degree of firmness, to the parietes. The large veins connected with the heart and upper part of the thorax and neck, did not appear to be materially interfered with; and the nervous trunks seemed to be perfect.

The liver was large and adherent to the diaphragm; it was congested, yet not unhealthy. Spleen rather large, dark-coloured, and soft. Thoracic and abdominal portions of aorta healthy. All the other abdominal viscera, and the contents of the skull were healthy.

The chief point of interest in the above case is, that it furnishes an example of rupture of an aneurysm of the *transverse* arch into the *pericardium*, a comparatively infrequent termination of aneurysm arising in this situation. A subordinate point, however, struck me at the post-mortem examination, in connection with the

DESCRIPTION OF PLATE V.

Figure 1 illustrates Dr. Ogle's case of the large patch of Muscular Fibre (*a*) in the substance of the Anterior Flap of the Mitral Valve, with a thick muscular cord passing up to it from one of the fleshy columns of the Ventricle, p. 109.

Figure 2 illustrates Dr. Ogle's case of Ulcerative Perforation of the Anterior Flap of the Mitral Valve, p. 117.

Figure 3 refers to the same case as fig. 2, and shews the posterior or auricular aspect of the above-mentioned Mitral Valve Flap; the Ulcerated Aperture being plugged up by a cap of precipitated Fibrin.

Fig 1

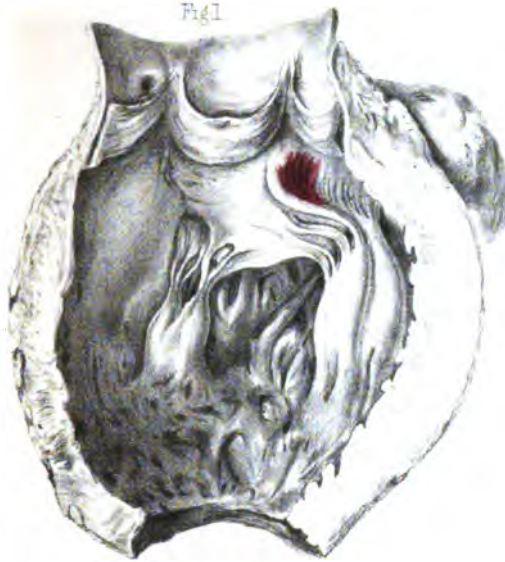

Fig 2

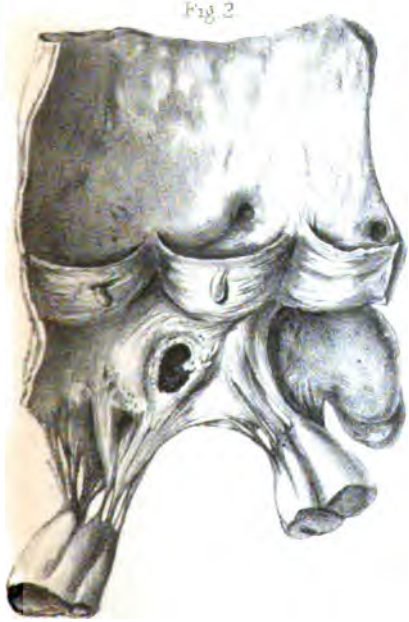

Fig 3

H. T. Carter del. Tuffen West lith. W. West imp.

condition of the heart, and the immediate cause of death. The general opinion, I believe, and one in which I fully concur, is, that death following rupture of the heart, of the origins of the large vessels, or of aneurysm into the pericardium, is due, not so much to syncope from loss of blood, as to compression of the heart by the pericardial accumulation. And it has appeared to me, in several instances which have fallen under my observation, that the *post-mortem* conditions corresponded with this view; for, I have found the heart empty, yet its ventricles not firmly contracted and plump as they would have been had their emptiness depended on their own contraction, but somewhat flabby, and having, especially in the case of the right ventricle, the anterior and posterior walls flattened against one another, as though they had been subjected to pressure from without. In the present instance, however, the heart was firmly contracted; and coupling this fact with the the extreme suddenness of the patient's death, I am induced to think that the fatal event, though probably aided by the pericardial effusion, was essentially due to the syncope which attended the sudden escape of blood from the circulating system. Dr. Bristowe, *2nd of February*, 1858.

---

25. *Heart, shewing a large patch of striated Muscular Fibre, situated in the Substance of the Anterior Segment of the Mitral Valve; also, the Substitution of Muscular Cords for two of the ordinary Tendinous ones, passing to the same Segment from a Columna Carnea, one of which cords joins the above-mentioned Muscular patch. Observations, in connection with the above, upon the presence of striated Muscular Fibre in the Valves of the human Heart, as a natural condition.*

The muscular patch was about the size of a fourpenny-piece, and was situated between the two layers of the endocardium forming the valve-flap, rising considerably on the ventricular aspect above the level of the surrounding surface of the flap. With it communicated a thick, fleshy cord of muscular tissue (Plate V. Fig. 1), passing from the large columna carnea, which usually sends a tendinous cord to that part of the valve-segment where the patch was situated. Another cord also, passing to

the margin of this segment, from one of the fleshy columns, though much thinner and finer than the other one, was formed of muscular tissue. Both the muscular patch and the muscular cords were of a brightish-red colour, contrasting forcibly, when recently removed, with the neighbouring part of the valve; and, on *microscopical examination*, they were found to be composed of well-formed, striated muscular tissue, having every physical resemblance to that of the walls of the heart. The anterior flap of the mitral valve presented also an opaque and whitish-yellow patch, of atheromatous deposit; and the lining membrane of the ascending aorta shewed one or two spots of atheromatous material. Otherwise, the heart and pericardium exhibited nothing unusual.*

History.—The specimen was removed from the body of a man (J. H., æt. 25), who died in St. George's Hospital with disease of the kidneys and ulceration of the bowels. There was nothing in his lifetime—no cardiac bruit, or other indication, to lead to the conjecture that there was anything diseased or malformed about the heart.

Remarks.—The existence of any visible muscular fibre whatever, and much less of any large masses of it, in any of the segments composing the cardiac valves, has been so rarely observed, and the utility of such a formation is so far from obvious, that I am quite at a loss for any teleological explanation of the unusual appearance presented by the heart now exhibited. Had any deficiency been noticed in the mechanical apparatus of the left ventricle, by which the onward progress of the blood-tide is naturally favoured and its retrogression hindered, or had any such interference with the other parts composing the mitral valve existed, as would seem to necessitate a modified action of the valve-flap containing the muscular patch, then, one would naturally have assigned to the presence of so unusual a formation some vicarious purpose; but what object such an arrangement subserved, especially seeing that, in all other respects, the valves, orifices, and walls of the left ventricle were, to all appearance, healthy, is a

* The preparation shewing the above-described state of the mitral valve has, since its exhibition to the Society, been added to the St. George's Pathological Museum, and may be seen as No. 8, sub-series iv., series x.

question to which I cannot suggest a reply with any satisfaction.

One is, of course, driven to the assumption that the formation of a large quantity of any tissue, such as this mass of muscular fibre, so much out of place (to use such phraseology with reserve) is, most probably, but an instance frequently met with in the animal economy of an unwonted and exaggerated development of what exists ordinarily but only in a slight degree.

Numerous examples of so-called malformations, apparently explicable in no other way, might be quoted, were not the task superfluous. The query then suggests itself, whether such an explanation of the mal-formed mitral valve in question is to be obtained in like manner. Is the presence of this large patch of muscular fibre in the anterior lip of the mitral valve, merely an excess of an element which naturally exists between the serous reduplication forming that part of the heart? This is, I think, more than possible—judging from my own inquiries and examination into the histological constitution of the cardiac valves. I will, for the purpose of illustration, adduce a few of the observations made at various times by anatomists, regarding these valves.

I find that Winslow, writing in 1733, spoke of finding fleshy fibres in the duplication of the membranes forming the semi-lunar valve. This, he says, he did by aid of the microscope. Lancisi also, writing about the same time, speaks of the chief part of the valves of the heart as being "semé de fibres musculaires." Several others, such as Glassius, Morgagni, Cooper, and Haller, spoke in like-way concerning the heart's valves; and to them Senac alludes, after himself asserting that muscular fibre is contained in these valves;* he declares that it requires no microscope to see them. In later times, Kürschner† has asserted that he was the first to trace (in 1840) muscular fibres from the walls of the auricle into the tricuspid valve;‡ and this statement, as also those on the subject by Senac, are alluded to in Quain and Sharpey's "General Anatomy."§ By the latter authors,

* "Traité de la structure au Cœur," 1783, vol. i., p. 82.

† Article "Herzthatigkeit in Wagner's Handworterbuch der Physiologie," 1844, p. 44.

‡ See Froriep's neue Notizen, 1840.

§ Vol. ii. p. 1111.

it is affirmed, confirmatory of Kürschner's statement, that a few muscular fibres occur in the bicuspid or mitral valve segments. Lieutaud, however, writing in 1742,* although he describes the nature and composition of these valves, makes no mention whatever of any muscular element.

In a similar manner, Bouillaud speaks of the arrangements of the fleshy columns and their tendons, but there is no mention made by him of muscular fibres being conducted from the columns into the valve-flaps.† So also is it with Bertin. In more recent times also, Reid,‡ alluding pointedly to this very subject, (speaking of the auriculo-ventricular valves) asserts, that he "could never observe any distinct traces of muscular fibre in these valves in the human heart, either when fresh or after boiling;" and speaking of the tendinous fibres in these valve-flaps, he warns observers against mistaking them when tinged with blood, for muscular fibres. He proceeds to observe, that in the dog he had seen a distinct band of transverse muscular fibres in the "base of the lower lip of the mitral valve; and in the heart of the ox and horse, he had observed very distinct longitudinal muscular fibres in the auriculo-ventricular valves of both sides." Reid states that Bouillaud, to whom I have above alluded as being silent respecting these muscular fibres, was of opinion that in some cases, as in hypertrophy of the valves, muscular fibres may be found in the valves of the heart; but, he adds, that Bouillaud seems to have come to this conclusion, not from any actual and well-marked instances of the same, but chiefly from the fact that such muscular fibres are found in the auriculo-ventricular valves of the ox, and from a single case which Reid terms "inconclusive."

In still more recent times Kölliker,§ makes no mention of muscular fibres whilst describing the valves of the heart; and Gerlach,‖ whilst describing them, speaks distinctly of their being strengthened by processes from the tendinous cords, etc., but says nothing of any muscular fibres entering into their

* "Essais Anatomiques," p. 232–4.

† "Traité Clinique des Maladies du Cœur," vol. i. p. 14.

‡ Article "Heart," in Todd's "Cyclopædia of Anatomy and Physiology," p. 589, written in 1836.

§ See his "Manual of Human Histology."

‖ "Gewebelehre," 1853, p. 204.

composition. Again, Dr. Peaslea, an American author, in his work lately issued,* speaks of the existence of three layers, forming the auriculo-ventricular valves, namely, two lamellæ of the endocardium, and a third intervening or middle one, formed of areolar tissue with elastic network. He, however, says not a word regarding any muscular fibre being found between the two endocardial lamellæ.

Thus, from the above quotations and allusions, it is clear that observers differ greatly in their statements on the subject alluded to. I do not find anything sufficiently conclusive to make me suppose that the older observers discovered genuine striped muscular fibre in the cardiac valves; and with the exception of Winslow, there is no mention of the microscope being used to settle the question in hand. Senac states, that no microscope is called for, but that muscle is seen by the unaided eye in these valves. I have been at the pains of examining a number of hearts in respect of this point, and from what I have found, I am greatly inclined to imagine that when Senac, following others already mentioned, spoke of the ease with which this muscular tissue is observed in the valves, he was referring merely to portions of the general tendinous valvular structure, reddened, as it almost always is, by sanguineous imbibition. Had he at all referred to muscular cords in contra-distinction to the ordinary tendinous cord, which, at times, are found to exist, as I have seen, in the place of the tendinous cords, I think he would have said so, and would have drawn attention to the fact pointedly; but this he does not do, and, as it appears to my mind, he simply had reference to, what he believed to be, muscular tissue in the middle parts, but especially at the margins of the respective valve curtains. And this I deem the more probable, inasmuch as anyone carefully examining the valves of the human heart, as they are seen in an ordinary *post-mortem examination*, that is, several hours after death, and after what may be termed maceration in the blood for some time, will see how much like muscle certain points of the tendinous valve appear to the naked eye. This is especially the case at the edges of both the anterior and posterior flaps of the mitral valve, which are reddened, thickened, nodulated, and

* "Human Histology," 1857, p. 499. Philadelphia.

softened. On carefully dividing, with a fine and sharp scalpel, the uppermost layer of endocardium, which enters at this part into the composition of these structures, and tearing out with a needle the subjacent part—not easily accomplished,—it will soon be demonstrated, that the appearance which, at first sight, so nearly resembled muscle, was only due to infiltration by the blood of a looser and more textile portion of the flap, which, at this part, more widely separates the two endocardial layers. This tissue, so well able, from its looseness, to imbibe surrounding fluid, and consequently to tumefy, will be seen under the microscope to consist merely of a plentiful and delicate network of fibrous tissue, with fine, nucleated, spindle-shaped fibres, of various lengths, and occasional elastic curled fibrillæ. Certainly no muscular tissue is here found as a rule, and I have hitherto, but very rarely found it in this position. Had the various above-named authors referred, however, to the cords by which the auriculo-ventricular valve flaps are united to the fleshy columns, and so placed under the action of these muscular structures, they might have justly said that these cords, tendinous as they are ordinarily, are frequently replaced by muscular ones, which are simply continuations of the fleshy columns; but they could not speak of their existence as the rule, or as anything but exceptional. Of course, I have hitherto been only animadverting upon the condition of the valves, as they are found in the human heart; and I would here remark, that on this subject, as on many others, I believe that many of the older anatomists applied their observations, derived solely from the lower animals, to the description of human anatomy; and that their accounts of many parts are taken from ordinary domestic animals, and from them alone, and these are often inapplicable concerning our own species. How Reid came to declare that he had found a transverse band of them in the lower lip of the mitral valve in the heart of the dog, but that he had in vain looked for such muscular fibre in the human cardiac valves, I do not know. I can only suppose, that he either did not examine a sufficient number of human hearts, and generalized too hastily, or that he imagined that such fibres, if they did exist, must have found their way thither, so to say, from the auricular walls, and only searched for them in the vicinity of the walls of the auricle,

i.e., at their bases. It is just possible that he exposed himself to the charge which he prefers against Bouillaud, of determining from too limited a number of cases, although the justly deserved reputation of this observer for exactness and amount of research, goes far to discredit such a fancy.

As before stated, I have myself sought to establish what the real case was as regards the question mooted, and although I have not yet concluded my investigations, or yet accomplished sufficient for the purpose of placing the matter at rest, as to many necessary particulars, yet I have in several instances, found, and shewn to others (as to my friends Mr. Gray and Mr. Holmes), distinct, well-formed, and natural muscular fibre, in the anterior and larger, and more moveable mitral valve flap of the human heart. In one or two cases examined, I have been quite unable to meet with any trace of striped muscular fibre in this valve, but in the majority of instances I have done so. I would observe, that in many cases, a little care will shew that certain of the tendinous cords which pass to the edges or to the surface of the anterior flaps, from their flexor muscles, the columnæ carneæ, are replaced by muscular ones; so that this part of the fleshy column is in fact wanting in its tendinous attachments, and has very much the appearance of those others which are well known as not passing to the valve-segments at all, but merely joining some other portion of the wall of the ventricle. These muscular cords are easily visible on close inspection, and without the assistance of the microscope, when they do occur. As yet I have not examined a sufficient number of instances so as to be enabled to give any statistical information as to their frequency.

When these muscular cords have existed, I have invariably found striped muscular fibre in the middle part of the valve-segments, as well as in the muscular cord itself, at a point totally apart from the base, where, if at all, would be found such fibres as emanate from the auricular walls. I have, however, certainly found muscular fibres in the anterior mitral segment, when there was no muscular cord passing into it from any fleshy column. I should say, that I have found that when a tendinous cord has been substituted by a muscular one, it has, most frequently, been a strong one, emerging from the thickest and largest fleshy column in the

ventricle, and proceeding to coalesce with the ventricular surface of the valve flaps at about a quarter of an inch from its margin. This is the situation, as will be seen, of the fleshy cord, in the preparation, (*vide* Plate V., Fig. 1), and I believe that extended research will shew this to be the tendinous cord most commonly replaced by a muscular one.

In one heart, which presented the most complete instance of a muscular cord vicarious to a tendinous one, the muscular column carried a large, clearly-seen, blood-vessel, some distance upwards from the fleshy column from which it proceeded. This was a heart of huge size, shewing great hypertrophy, with dilatation of its left ventricle, along with an unusually large mitral orifice. The mitral valve flaps were, consequently, very large and much thickened and strengthened, the endocardium of the cavity generally being increased in thickness and opacity. In this case muscular fibres of a large size were seen in the middle of the valve segment, as well as between it and the part joined by the fleshy cord. And moreover, several of the muscular fibres there found, were in a fatty state.

It may then, I think, from the foregoing statements, be granted, that the most probable interpretation of the presence of the large muscular patch in the substance of the mitral valve flap, as shown in my specimen, is, that it is an instance of a congenital accumulation (amounting to malformation) of the transversely-striped muscular fibre, found naturally, but very sparingly, to exist in the part. What the exact function of these muscular fibres may be, existing in such minute quantities as they do,—what part they play in the due and proper adjustment of the valve flap, is a point which has not been settled or apparently sought into. Reid alludes to the desirability of determining the use of such longitudinal muscular fibres as he had found in the cardiac valves of the ox and horse, but of course, regarding these fibres, as found in the heart of man and of the lower animals, the purport of this communication is, owing to the nature of this Society, too strictly pathological to admit of any hypothesis here. I hope, in another place, to be able to give more scope to the consideration of an inquiry so strictly physiological.

Dr. John W. Ogle, *2nd of February*, 1858.

26. *Pouch or Cavity (simulating a true Aneurysmal Pouch), with thick and firm Parietes, formed, apparently, by Fibrinous Coagulum, connected with a perforation of the anterior segment of the Mitral Valve, which was, most probably, the result of Ulceration. Note of cases of true and false Aneurysmal Pouching of the Cardiac Valves.*

The perforation (Plate V., Fig. 2), which was of the size of a pea, was somewhat irregularly oval in shape, with rather roughened margins, to which were adherent one or two masses of yellow fibrine.

The pouch (Plate V., Fig. 3), into which it led would have held about a large pea, and had its inner surface roughened by projecting coagulum. The walls of this pouch, as before said, were thick and quite smooth externally, that is, on their surface as seen from the left auricle of the heart. That portion which formed the apex of the pouch was somewhat flattened, as if it had been subjected to pressure; and the edges of the walls of this pouch corresponded so accurately with the margins of the perforation on the auricular side, that the pouch had the semblance of a cap, fitted, as it were, upon the aperture. The endocardium of the auricle around the pouch projecting from the mitral valve flap, was in no degree thickened or altered by deposit, etc., of any kind; but in the ventricle, around the orifice of the opening, this membrane was very much thickened and roughened. Moreover, in another part of the left ventricle, at a point a little below and to the left of the aperture in the valve flap, the endocardium was roughened, and presented the appearance of slight excavation and ulceration.

The aortic valve flaps were seen to have one or two yellow, tough shreds of fibrin adherent to their ventricular surface; but there was no disease obstructing the passage of the blood, or allowing of its regurgitation through the valves; the aorta, both at its root and to a great extent upwards in the direction of the arch, was much dilated, and greatly thickened and scabrous as to its walls, owing to the excessive deposition of atheromatous and some calcareous material. The walls of the left ventricle were a little thickened, but nothing more was remarked about the heart.

History.—The specimen was removed from the body of a man who died of disease of the bladder and abscess of the kidney, associated with stricture of the urethra. It was presented by Mr. Cæsar Hawkins to the Museum of St. George's Hospital. No further history is recorded.

Commentaries.—On looking at this specimen, the interesting question suggests itself whether it be, as it appears at a cursory glance, a genuine aneurysm of the mitral valve flap, such as we know to exist sometimes, consisting, as it may do, of a protrusion of all the parts of the flap, or of only one layer of the serous membrane, the other being destroyed by ulceration or by the deposit of calcareous and atheromatous matter? Another question arises, whether there has been simply ulceration of all the component elements of the flap leading to complete perforation, and subsequent accumulation of fibrinous deposit from the blood (for conservative purposes) around the resulting orifice on the auricular surface, which has eventually plugged up the opening, but at the same time has become so excavated and modelled with the regurgitating stream of blood as to form a cup or pouch-like covering to the opening in the flap? I am inclined to suppose that the latter supposition is the right one. There is yet another view which might be taken, which is, that a true aneurysmal pouch may have been in the first instance formed, and that the apex of this pouch if much diseased, may have become ulcerated, or even ruptured mechanically by the blood, and so a direct perforation established, which has subsequently been invested with the fibrinous cap or false pouch.

Microscopical examination of the walls of this false pouch gave results so completely identical with those obtained on examining old-standing fibrinous clots and deposits, and which I need not, in this place, specify, that I have no hesitation, fortified by the general appearances before detailed, in concluding that it was not the parietes of a true aneurysm of the flap, merely thickened by disease, that I was regarding.

In default of full particulars as to the patient's history and antecedents, we may suppose, either that inflammation of the endocardium had existed at one time, leading to softening and ulceration, or that the deposition of calcareous and atheromatous,

and so-called steatomatous matter had originally existed, and undergone disintegration at the part where the perforation was produced. This idea is the more tenable when we find, as in the case now exhibited, that in other places and in other ways, the valve flap is found to be rigid and thickened; or again when, as in this case, the lip of the valve in other parts exhibits positive signs of an ulcerative process having taken place.

Independent of its own substantive interest, this case is worthy of record as a sequel to those three cases brought before the notice of this Society, by my friend, Mr. Prescott Hewett, in the session 1850-51, and fully described at p. 78 of the third volume of our "Transactions," in connection with the subject of aneurysms of the *mitral* valve flap. On looking over the description of those three preparations of Mr. Hewett's, it will be seen that the two first shewed well-marked and true aneurysmal pouches in the anterior flaps of the mitral valve, projecting into the auricles, and having their tunics formed of the lining membrane of the ventricle entire. In the third and last preparation, however, to which Mr. Hewett remarks that he had never seen the like, there was a perforation in the anterior mitral flap, which led into a cavity formed in the centre of a clot of blood adherent to the margin of the opening. As he says, "one side of the coagulum was easily detached from the opening, and the true nature of the appearances were at once made evident." In this last case it seems, I think, quite manifest that, however the orifice in the flap had been formed originally, the cavity into which it conducted, and which appeared, "at first sight, to be that of a small aneurysmal pouch," was only due to the hollowing out, by the action of the blood in motion, of such coagulum as had gradually accumulated around the edges of the perforation. This aggregation of coagulum had, no doubt, for its object the reparative closure of the aperture. In fact, I look upon the specimen which I have now shewn, as being identical in character with that third one of Mr. Hewett's, before alluded to, differing only in the greater perfectness of the fibrinous pouch capping the perforation. As far as my own experience goes in *post-mortem examinations* at St. George's Hospital, true aneurysmal pouches of the valves of the heart as well as those perforations leading to the production of

fibrinous pouches similating true aneurysms, are to be considered as rare. In our Pathological Museum we have but these two preparations illustrating this kind of perforation, plugged up by a cap of fibrine. They are catalogued as follows: that shewn by Mr. Hewett to the Society, and alluded to above, as No. 4*f*, sub-series iii., series x.,* and that just described by myself as No. 6*f*, in the same sub-series. We have also only two well-marked instances of real pouching, or aneurysms of the cardiac valve flaps. Of these, the first was a case of pouching of one of the *aortic* valve flaps, and was brought before the notice of this Society by myself in the session 1851-52, and described at p. 296 of the volume for that year. In this case one of the flaps was very attenuated indeed, and presented a well-marked pouch in the direction of the ventricle, as if occasioned by the pressure of blood towards that cavity in a direction from the aorta.

The subject of this affection was a man, æt. 33, who never had had rheumatism, and could assign no cause for his illness. He had had palpitation of the heart and dyspnœa for a period of two years, and was admitted into St. George's Hospital in the year 1852 with symptoms of hypertrophy of the heart. There was a loud diastolic murmur at the apex, and a double murmur, audible at the base of the heart, and the pulse was very jerking. After death, which was preceded by hæmoptysis, the walls of the left ventricle were found much thickened, and the right ventricle was dilated. The valve flap, which was pouched, as before said, had been ulcerated at its extremities, and torn down from its attachments, and so united at a lower level than its neighbouring flaps. There was a great amount of atheromatous deposit in the coats of the aorta.

The other case is the first of those which, as before stated, Mr. Hewett brought before this Society in 1850-51. In this case are seen two aneurysmal pouches projecting into the left auricle, one of which has a peculiar vermiform character. The valve flap is also extensively ulcerated.† In addition to those before men-

* This specimen is also alluded to in our new Catalogue as 4*b*, sub-series iii., series x., owing to great thickening and rigidity of the affected flap, and as 3*f*, sub-series iii., series x., by reason of ulceration of the flap.

† This perforation is also alluded to in our Catalogue as 1*f*, sub-series iii., series x., as affording an instance of ulceration of the valve flaps.

tioned as having been brought before this Society, one or two others might be quoted. As an enumeration of these may be interesting, I will here give them.

Thus in vol. iii., (the same in which Mr. Hewett's case will be seen,) are described, at p. 71, a case by Dr. Peacock, in which, along with injury to the aortic valves from violent muscular efforts, we have mention made of so-called aneurysm of one of the *mitral* valve flaps. This was, however, evidently not any true aneurysmal dilatation of the valve flap, but was like the one which I have now brought to the Society, inasmuch as it shewed "a small orifice," near the edge of the flap, communicating with the interior of a long body, "resembling an ordinary vegetation." This patient had never had rheumatic fever.

Again in the same volume, at p. 77, a case is described by Mr. Coulson, in which, along with other, and extensive disease of the *aortic* valve flaps, we have one of these flaps having a "small sac" opening into the corresponding sinus of Valsalva, and also a "similar, though still smaller, cavity" in the free fold of the *mitral* valve, communicating with the ventricle. These sacs in the flaps are mentioned by Mr. Coulson, along with the one of Dr. Peacock's above referred to, as being of the same nature; but it would appear, though the description of them resorted to is not very clear, that they were veritable aneurysmal pouches of the flaps, and not mere perforations communicating with cavities within adherent coagula. The subject of this affection had suffered from rheumatic fever ten years previously.

Again at p. 285 of the "Transactions" for the session 1851-52, is described by Dr. Peacock, a case (forwarded to him by Dr. Thurnam), of a small, partly biloculate, aneurysm of the posterior fold of the *mitral* valve and the left ventricle. The patient had been very intemperate, but there was no history of his having suffered rheumatic fever. Lastly, at p. 157 of vol. vi. is related by Dr. Habershon, a case of extensive disease of the aortic valve, in which the anterior curtain of the *mitral* valve, at a point close to the aortic valve, presented a circular space about three quarters of an inch in diameter, much thickened, and *bulging* considerably towards the left auricle. The flap was also perforated at its central portion by a minute opening, "capable

of admitting a small probe, and filled with a clot of blood." The patient had had pain in his limbs, but had never had a regular attack of rheumatism.

The above constitute all the cases of true or false aneurysm of the various valves of the heart which I can find in the "Transactions" of this Society.* Including the one which is the immediate subject of this communication, we have altogether ten instances. It is worthy of observation that of these we have no less than eight in which the *mitral* valve was the one occupied by perforation, and true or false aneurysm, whilst there are only two in which the *aortic* flaps are affected, and of these two one was associated with a similar condition of one of the *mitral* flaps. Dr. JOHN W. OGLE, *2nd of February*, 1858.

---

27. *Case of Ruptured Aneurysm of the Popliteal Artery.*

The specimen shews an aneurysm of the popliteal artery at the point of departure of the several branches. It is of an elongated shape and of the size of a large pear, inclining to the inner side of the popliteal space, with the internal popliteal nerve stretched across it. The walls are remarkably thin, especially at the lower end of the tumour, under the bifurcation of the gastrocnemius muscle. At this point the walls of the sac had given way by the formation of a ragged, irregular opening about an inch long. A few delicate layers of fibrin lined the interior of the sac at its upper part, the rest was filled by a loose coagulum. The effused blood had made its way down the leg between the gastrocnemius and soleus muscles, and had thence escaped into the sub-cutaneous textures on the back of the leg, giving rise to much gangrenous ecchymosis, which was very apparent on the surface, and raised the cuticle into large vesications. Under the tendon of the semi-membranosus muscle the blood had passed into the bursa which is found there, and evidently communicated with the synovial cavity of the knee-joint at the inner condyle.

A short summary of the *history* of the case is as follows:—

The leg was removed from a patient in King's College Hospital, by Mr. Fergusson, on the 16th of February, 1857. The man

* *Vide* a case related in the present Vol. by Dr. Peacock.

was a coal porter, æt. 50. On the 8th of February, while carrying a sack of coals up the ladder of a waggon, his right foot slipped and he fell, twisting his knee; upon the lower rail. When seen by Mr. Wood, eight hours after the injury, the knee and ham were very tensely swollen and discoloured by ecchymosis and very painful to the touch. He complained of much pain in the limb, and a feeling of numbness extending down to the toes. Pulsation was not very apparent in the swelling at this time, but on questioning the patient a day or two afterwards, he stated, that twenty years ago he had experienced a similar injury to the same knee, and that ever since it had been weaker than the other, and he thought that a swelling had remained behind the knee up to the present time, but had not grown larger nor caused him much annoyance of late. About this, however, he was not very clear or decided. It gradually became apparent, by the increase of the swelling, the more decided evidences of pulsation throughout the tumour, especially towards the inner side, and by the absence of pulsation in the anterior and posterior tibial arteries; that the popliteal artery had given way, either from the previous existence of an aneurysm or from ossification of its coats. The numbness of the toes and pain in the leg increased, gangrenous discolouration followed, and upon the toes and heel patches of vesication and the more decided evidences of sphacelus were apparent. These gradually extended over the whole foot. On the 11th, sensation was lost up to the middle of the leg, and at the site of the injury, and over the calf, several dark-coloured vesications had formed and assumed a decidedly sphacelated appearance. The leg, at and below the knee, was much swollen and œdematous. No line of demarcation becoming apparent, and the patient's health beginning to give way, with deficient appetite and foul tongue, it was deemed advisable not to delay, but to perform amputation above the injured point. His pulse continued tolerably firm though frequent up to the time of the operation.

The operation was performed by lateral flaps at the junction of the middle and lower thirds of the thigh. Remarkably little blood was lost in its performance. The flaps were somewhat infiltrated by serous effusion. For some days after, the patient

suffered from sickness, pain, and sleeplessness. The discharge from the stump was small in quantity, and of a dark, grumous, putrid character. Partial adhesion of the flaps took place at the upper part, but altogether there was a great want of healthy action apparent, the surface being ash-coloured, and the granulations sparing and weak. On the 20th, he was attacked by violent delirium. Under the administration of stimulants and strong beef tea, this passed off after two days, but the patient continued in a very unsatisfactory condition, low and depressed. On the 8th of March, secondary hæmorrhage suddenly occurred in the track of the ligatures to the extent of a pint of blood; and though temporarily arrested by opening up the wound and by pressure, it continued, at intervals, till the patient was very much reduced. A ligature was at length placed upon the superficial femoral. Some days afterwards the bleeding recurred from the original site and re-amputation was performed higher up. This was effective in restraining the hæmorrhage, but he still continued in an unsatisfactory state until the 22nd of May, when a pulsating tumour was observed in the upper part of the superficial femoral artery above the point of ligature, which continued to get larger until the death of the patient.

A *post-mortem examination* was refused by the friends, but the stump was opened up, and a large cavity filled with grumous pus and blood clots was found at the extremity of the superficial femoral artery, which terminated abruptly about half an inch from the profunda. Mr. JOHN WOOD, *6th of February*, 1858.

---

28. *Simple Hypertrophy of the Heart without Dilatation or Valvular Disease.*

The man from whom the heart was taken, died suddenly from apoplexy. The heart weighed twenty-four ounces; its muscular tissue was firm and healthy; its valves all competent. A large clot of blood was found in the brain. All other organs and parts of the body were perfectly healthy in appearance, with the exception of the arteries. The cerebral vessels were very atheromatous, and so also was the aorta, but not in an advanced degree. Dr. Markham remarked, that the condition of the cerebral vessels was,

in all probability, the condition of the smaller arteries in all parts of the body; and that their obstruction to the circulation of the blood caused by them, was the cause of the cardiac hypertrophy. Cases of hypertrophy of the heart are occasionally met with, in which there is no apparent cause of the hypertrophy. In such cases, it is possible that a similar state of the smaller arteries would have been found if had been sought for. The case also shews, that the degree of atheroma existing in the aorta is no index of the extent of the atheromatous degeneration in the smaller vessels. Dr. MARKHAM, *2nd of February*, 1858.

---

29. *Bruise within the Heart.*

In this heart there was a distinct ecchymosis as large as a crown-piece on the inner surface of the septum in the left ventricle.

The heart was taken from a man who fell from an omnibus, and in falling, struck his side and then his head. He died from cerebral effusion of blood. The bruise was doubtless caused by the violence of the blow on the thorax.

Dr. MARKHAM, 16*th of February*, 1858.

---

30. *Aneurysm of the right Profunda Femoris Artery; Ligature of the external Iliac.*

J. W., a baker, æt. 26, residing at Woolwich, was admitted into Guy's Hospital, on the 18th of November, 1857, under Mr. Cock. He stated, that he had enjoyed good health, had never had rheumatic fever, and had lived temperately.

Four weeks prior to his admission, when at work, he experienced a sharp pain in his right groin extending downwards to the knee. He paid little attention to it, regarding it as rheumatic, and continued at his work. The pain gradually increasing in severity, he applied for advice to a surgeon at Woolwich, but not obtaining any relief he came to Guy's Hospital.

When admitted he had a pale and haggard appearance, and complained of severe pain in his right groin, extending down to the knee, which had deprived him of sleep for three nights. Upon

examination, a large pulsating tumour was detected in the upper third of the thigh, in the course of the femoral artery; all pain and pulsation were arrested by pressure upon the external iliac, but returned immediately upon its removal.

A spinal curvation was observed in the upper dorsal region, and indications of regurgitation at the aortic valves.

The pain continuing intense, and being undiminished by rest and the slight pressure of a sand bag over the tumour, an operation was proposed for its relief, and upon the 22nd, it was performed by Mr. Cock, under the influence of chloroform. The incision adopted was the semi-lunar, above and in the line of Poupart's ligament no difficulty was experienced, the external iliac artery being easily found and tied, all pulsation in the tumour ceasing immediately. Upon recovering from the chloroform, the man expressed himself as being comfortable and free from pain; and everything went on well. Upon the 7th of December, on the sixteenth day after the operation, the ligature came away, and the aneurysm had become smaller and somewhat harder. Upon the 21st of December, the wound had nearly healed, and the man had gained strength, his general health having much improved. He had never put his foot to the ground to rest upon it, but had been dressed and placed before the fire. Upon the 7th of January, or the forty-seventh day after the operation, and the thirty-first after the removal of the ligature, a gush of blood took place from the small fistulous opening, which was said to have been about a pint in quantity; the hæmorrhage was easily arrested by pressure, and did not recur. He rallied and went on favourably till the 23rd, when he complained of feeling poorly, and of pain in his chest. Upon the 24th he had slight hæmoptysis, and upon the 25th he died, having survived the operation nine weeks.

At the *post-mortem examination* both lungs were found much congested, and the bronchial tubes contained sanguineous mucus. The heart was uniformly enlarged, and the left ventricle dilated and hypertrophied; the aortic valves were extensively diseased, and all appearance of their original shape having disappeared, the partition between them was destroyed, and there merely remained a thin edge attached, from which hung down several large vegetations containing cretaceous matter. The aorta, except a few atheromatus patches above the valves, was healthy. The viscera

were in a healthy condition, and the peritoneum at the seat of the operation, presented no appearance of having been disturbed.

The parts, including the line of incision, common iliac artery, femoral artery, and aneurysmal sac, with the muscles of the groin were removed and subsequently dissected. The line of incision had nearly healed, a small fistulous opening alone remaining. The external iliac artery, from its origin to the point of the application of the ligature, was filled with a firm clot, the artery below this spot was empty and quite natural, no atheromatous deposit or aneurysm being visible: a probe directed from below passed into the vessel above, proving that direct union had taken place after the removal of the ligature; a probe also passed through the wound, and came out in the line of junction of the divided vessel. It is probable that the secondary hæmorrhage had come from the lower part of the vessel. It will be seen that the epigastric and obturator arteries arise from a common trunk; about half an inch below the point where the ligature was applied, they were quite open and free from plug, and it is through them that the circulation must have been partially carried on; it is fair to believe that it was through them that the secondary hæmorrhage took place.

Upon examining the aneurysmal sac, it will be seen, that it is very large, passing upwards beneath the tendons of the psoas and iliacus muscles, and backwards to the bone, which was rough and scabrous, and to which it had become attached below the small trochanter. The sac contained much fluid blood, but very little fibrin; upon examining it carefully it appears to have had its origin from the profunda femoris just after its separation from the femoral.

This specimen I believe to be of much interest, being a unique one of aneurysm of the profunda, at least, I know of no recorded instance of a similar condition. Reviewing the symptoms, I am not aware of any means by which such an aneurysm could be diagnosed, and although in this instance a fatal termination took place, there is every reason to believe, that if other and more serious disease had not existed, a more fortunate result might have been obtained.*

Mr. Thomas Bryant, 16*th of February*, 1858.

* Since recording the above, my attention has been called by Mr. Erichsen to a case of the same disease, published in his work on "Surgery."

31. *Endocarditis on the Right Side of the heart, caused by small Cancerous Tumours beneath the Endocardium, in connection with extensive Adhesive Phlebitis.*

M. L., a married woman, æt. 45, died in the Middlesex Hospital in January, 1858, under the care of Mr. Shaw. Eighteen months before her death, she noticed a small hard lump in the right labium; this slowly increased in size, causing some little pain, and at length becoming ulcerated, she was admitted into the Hospital on the 25th of August, 1857. At this period, the disease was limited to the labium and clitoris, in which situation there was an irregular unhealthy sore, with indurated edges; the glands in the groin were not enlarged. Mr. Shaw then destroyed the disease by the caustic paste. The slough having separated, and the remaining wound being nearly healed, the patient was discharged on the 13th of October.

The disease soon re-appeared in the wound, and the glands in the groin also having enlarged, she again applied for admission. After this, the disease continued to advance steadily. Three weeks before her death, she was attacked with pain in the left thigh, swelling of the foot, and the usual symptoms of adhesive phlebitis. A few days after this, some swelling occurred in the right foot, and a week before her death the left hand and arm became swollen. The original disease at the same time continued to advance, discharging and causing great suffering: she gradually sank and died, her intellectual faculties remaining clear up to the time of her death.

Post-mortem examination on the following day. Some œdema existed in the lower extremities, especially about the right foot. There was extreme emaciation.

The diseased parts of the labium was much shrivelled, and presented the appearance of an irregular, sloughing sore, with very little cancerous tissue about its edges. The glands in each groin, the lumbar glands, and also much of the tissue surrounding the great vessels, were transformed into cancerous tissue, presenting on section, a dense whitish structure, with abundant creamy juice. This tissue surrounded very closely the iliac veins and

vena cava, but the walls of these vessels were neither thickened nor infiltrated with cancer.

Both the iliac and the right femoral veins were completely filled with a firmly-adherent coagulum, the upper portion being wanting in colour, and softer than the lower. The vena cava itself was incompletely filled with a partially organized coagulum, which was firmly adherent to the walls of the vessel. The clot extended to within two inches of the spot where the vena cava enters the heart, but it did not entirely block up the whole diameter of the vessel.

The left axillary, and some of the veins of the left arm, were completely filled with partially decolourized clots of blood. The tissue around these vessels, as well as the lymphatic glands of the heart were extensively affected with cancerous disease. The walls of these, like the walls of the veins before mentioned, were not themselves cancerous.

On opening the chest, a considerable amount of clear, serous fluid was found on both sides. The lungs themselves were healthy.

The heart was of average size, the blood was partially coagulated on both sides, and the coagulum did not adhere to the endocardium. On the left side of the heart, the lining membrane was perfectly smooth and transparent, the valves were not thickened. The endocardium on the right side, however, was thickened in places, and presented a number of small masses of fibrin adhering to its surface. These masses were very numerous, both in the ventricle, in the auricle, and in the auricular appendage. The fibrin was rough, and moderately firm, but was not closely adherent to the endocardium beneath. Few of these little masses of fibrin were more than a quarter of an inch across.

On passing the finger over these deposits, a hard nodule was felt beneath each. On section, the nodules presented the usual appearance of scirrhus cancer. The largest was nearly the size of a nut, but most of them were much smaller. They were embedded in the muscular substance of the heart, the endocardium being, in most instances, traced to cover them; the warty, fibrinous deposits

adhering to the free surface. There were no similar growths beneath the endocardium of the left side.

Under the microscope, they were seen to be built up of cells, similar to those of the cancer in other parts of the body. The muscular tissue near the tumours was in a state of fatty degeneration. The fibrinous deposits on the endocardium, exhibited a similar microscopical structure to that which usually exists in warty growths on the left side of the heart; *viz.*, an irregular, fibrillated structure, in which numerous granular cells are enclosed, no distinct connective tissue being detected.

The kidneys were both of them very large, and somewhat paler than natural. The section presented a very remarkable appearance, caused by nearly all the veins of the kidney being affected with adhesive phlebitis. In each kidney there was an irregular patch, which presented a yellowish colour, and a very granular section. The pelvis, and a portion of the ureter, on both sides, was intensely injected, and contained some puriform fluid.

The liver presented no unusual appearance, the veins, both portal and hepatic, being healthy. The spleen was of moderate size and firmness.

The principal feature of interest in the foregoing case is, that it appears to afford an example of the extension of inflammation from the veins to the endocardium of the right side of the heart. A careful review of the various facts of the case, does not bear out such an hypothesis; but, on the contrary, proves that the endocarditis arose from an independent cause, and was not a simple extension of inflammation.

The blocking up of the iliac and other veins, arose, no doubt, from the irritation produced by the proximity of cancerous tissue around the vessel, and was an example of a condition which is often noticed in veins passing through or near to cancerous disease. The fibrin was deposited on the endocardium from a similar cause, that is, the irritation produced by cancerous tumours immediately beneath the endocardium. It was a remarkable circumstance in the case, that the left endocardium was perfectly natural, there being no cancerous tumours beneath it.

Mr. Septimus W. Sibley, *2nd of March*, 1858.

32. *Ulceration, partly of the Anterior Curtain of the Mitral Valve, and partly of the Anterior and Left portion of the Wall of the Left Auricle. Appearance of an Aneurysmal Pouch, produced by adhesion of Fibrin to the margins of the Ulcerated Opening. Cavity in the Heart's Walls in connection with the above, containing broken down Fibrin. Peculiarity in the Sounds of the Heart.*

The orifice of the pouch-like cavity in question was of about the size of a sixpenny-piece, and was situate below the juncture of two of the aortic valve flaps. Its margin was surrounded by prominent masses of recent fibrin, which were also adherent to the ventricular surface of the contiguous aortic valve flaps. The cavity was of about the size of a hazel-nut, and in pressing backwards it bulged into the left auricle, and was empty, its walls only being lined by firm, yellow fibrin. In connection with this cavity, and to its left, in the middle of the heart's walls, was a small excavation containing a slight amount of soft, broken-down fibrinous material, which appeared to have been the result of ulceration. Recent fibrin was found deposited upon all the valves of the heart, though much less so on the right side than on the left; and much recent fibrin was found coating the pericardial surface of the heart. The cavity of the right ventricle was enlarged, and its walls were thickened.

There was also found a mass of fibrin in the substance of the lower parts of the left lung, broken down into a pus-like material (about three ounces in quantity), and the neighbouring parts of the lung were hepatized. Pleuritic adhesions also existed on the left side. Moreover, there was a large fibrinous deposit in the spleen, the centre of which was broken down. The mesenteric glands were considerably enlarged.

History.—The preparation was removed by my friend, Mr. Day, of the Madras army, and late of St. George's Hospital, from the body of a private soldier, æt. 24, who was admitted into Barrack Hospital, with gonorrhœa, in January, 1858, for which he continued under treatment, until symptoms of scarlet fever, of a very low type, shewed themselves. Symptoms of pneumonia and pleurisy, of the same low character, then set in, and had those

of endocarditis, and pericarditis superadded. After refusing to take his medicines, he gradually got weaker and died. During the last nine days of his life he generally lay on the left side, complaining greatly of pain about the heart, and on percussion of the chest in front, dulness was found to extend from just below the clavicle to nearly the seventh rib. On auscultation, a peculiar sharp click was heard at the termination of the first sound, and continuous with that sound; this unusual clicking sound was separated clearly from the second natural sound by the interval which ordinarily exists between the two sounds.

Five days before death the pulse was 96 and weak. It then became irregular and intermitting at every second or third beat, and on the day before death it was 148 per minute. It was not ascertained that he had ever suffered from any heart disease, or rheumatic fever, etc.

Remarks.—The above forms the most marked instance of ulceration of the mitral valve flap and neighbouring parts that I can call to mind. The pouch-like appearance obtained by the adhesion of precipitated fibrin, which eventually had become consolidated and excavated by the blood in motion, to the auricular aspect of the margin of the ulcerated perforation, and, at first sight, so much resembling a large true aneurysmal pouch of the mitral valve flap, is exactly the same as that shewn in a specimen which I exhibited to this Society on the 2nd of February (see page 117). The present case is, however, one shewing the process to a greater extent, and one also, from its look, of much more recent date. It is most likely, looking at the gravity of the disease in other organs, which was contemporary, and also, considering the appearances of activity which the disease had left in the valve flaps, that the whole of the destructive process alluded to may have occurred during the immediate illness which terminated the life of the patient, and this the more likely, inasmuch as no history of previous serious indisposition, as rheumatic fever, could be elicited with which the heart affection might have been connected. Most probably, the disorganization of the valve segments was coeval with the scarlet fever, which so frequently, as we know, establishes and leaves behind it asthenic derangements of nutrition

in various parts: with this was connected, and as I am inclined to think as a result, the ulceration producing the cavity, before described in the heart's walls as being lined by recent broken-down fibrin: and as a further result, I believe that the contamination of the general circulating medium by the admixture of the disintegrated contents of this redness was the cause of death, leading to the low inflammatory condition and deposits of fibrin found in so many of the viscera on *post-mortem examination.* The only fact which I think would be adduced in disfavour of this hypothesis, would be the extreme quickness, with which under this supposition, the whole series of changes, bringing about the fatal result, was wrought; but most are well acquainted with destructive ulceration and sloughing in debilitated subjects, and under peculiar circumstances, sufficiently rapid to render the above suggestion not only plausible, but probable.*

It occurred to me, that in connection with this specimen of ulceration of the mitral valve flap, it might be interesting and serviceable to examine and give some notice of the various instances of ulceration of the different valves of the heart, of which our records, at St. George's Hospital, furnish us with experience. I have accordingly scrutinized our records for that purpose, and shall now proceed briefly to arrange the results, with a view to statistical inquiry.

In the Table A, which immediately follows, will be seen an analysis of twenty-one cases, in which some ulceration of the cardiac valves, recent, or of old standing, existed. The age, sex, exact state of the affected valve, general condition of the heart, and other organs associated, as well as the salient points in the life, history, and condition of the pulse, when noted, will be seen at a glance.

In Table B, at a later page, will be seen a similar examination of cases of mere perforation of the valve flaps, not apparently caused by ulceration.

* The above specimen is shewn in St. George's Hospital Museum, as No. 7*f*, sub-series iii., series x.

TABLE A.—*Analysis of Cases of Ulceration of the Valves of the Heart.*

No.	Sex.	Age.	Reference to the Post-mortem Book in St. George's Hospital.	State of the particular valve or valves affected.	General Condition of the Heart.	Noticeable Condition of other Organs or parts of the Body.	State of the Pulse observed during Life.	Leading symptoms whilst in the Hospital, and presence or absence of previous serious disease likely to have affected the heart, and to have caused the valvular lesion.
1	F	20	1841. Fol. 232.	Lining of the auricular surface of the mitral valve flap very uneven and rough, with absorption of the membrane in some places; small deficiency in one of the aortic valve flaps.*	Heart's cavities dilated, with thickened walls. Lining of the left auricle uneven and roughened. The valves throughout very thickened.	Other organs were healthy.	No history exists of the state of the pulse.	No history of the case exists.
2	M	35	1842. Fol. 62.	The aortic valves were partially destroyed and very much thickened by atheromatous deposit.	The heart was very large, owing to dilatation of both ventricles. There was no hypertrophy of the left ventricle, but the walls of this cavity at its apex, were so thinned as not to exceed in thickness that of a sixpenny-piece. The various other car-	The lungs were gorged with blood and emphysematous. All the other organs were healthy.	No history of the pulse exists.	No history exists.

* This case is mentioned again in table B. No. 4.

No.	Sex.	Age.	Reference to the Post-mortem Book in St. George's Hospital.	State of the particular valve or valves affected.	General Condition of the Heart.	Noticeable Condition of other Organs or parts of the Body.	State of the Pulse observed during Life.	Leading symptoms whilst in the Hospital, and presence or absence of previous serious disease likely to have affected the heart, and to have caused the valvular lesion.
3	M	29	1844. Fol. 124.	Two of the aortic valve flaps had been partially detached from their connection with the aorta, and having been united to each other, formed one large valve flap.	disc valves were heathy. The heart was enlarged, owing to dilatation of its cavities, but no hypertrophy existed. There was an aneurysm of the size of a small apple in the walls of the aorta, just above the semilunar valve. The pouch was very hard internally, but lined by a transparent membrane and contained no coagulum.	The pleural cavities contained much stained blood-fluid, and the pleural membranes were thickened and opaque. The lungs were bloodless, and in places compressed by the pleuræ. The spleen had several large and thick deposits in its investing capsule of almost a cartilaginous consistency.	No history of pulse exists.	The patient had drank very freely. There was no history of rheumatic fever, etc. He had been ill eight months, with pain in the region of the heart; palpitation and dyspnœa. The heart's action was greatly increased and extended, and he spat blood at times in coughing. Convulsions preceded death.
4	M		1846. Fol. 131.	Aortic valve only consisting of two flaps. Both flaps thick	Heart's cavities dilated, with thick-	Blood extravasated in-	No history exists of the	Never had rheumatic fever, but had syphilis, though never

No.	Sex.	Age.	Reference to the Post-mortem Book in St. George's Hospital.	State of the particular valve or valves affected.	General Condition of the Heart.	Noticeable Condition of other Organs or parts of the Body.	State of the Pulse observed during Life.	Leading symptoms whilst in the Hospital, and presence or absence of previous serious disease likely to have affected the heart, and to have caused the valvular lesion.
				and rigid. One flap almost completely destroyed, and having a large ulceration in its centre, divided by a thin band of the valve still left, with rugged and thickened margins, but without any fringes.* Other valves healthy.	ened walls. Aneurysmal dilatation of the root of the aorta.	to the texture of the lungs.	state of the pulse.	secondary symptoms. Dyspnœa, cough. Increased impulse of heart, and cardiac dulness. Hæmoptysis. Both sounds of heart almost obscured by a very loud bruit, that with first sound, being loudest over artic valve, and that with second sound, loudest over apex.
5	M	19	1846. Fol. 271.	One of the flaps of the aortic valve much ulcerated at its free margin, and much thickened and diseased generally. Mitral valve flaps with recent fibrin attached.	Cavities of the heart dilated, with hypertrophied walls	Hepatized lung, and much fluid in pleural sac.	Pulse small and weak, and rather irregular, but not intermittent.	Never had rheumatic fever or chronic rheumatism. Cough, dyspnœa, anasarca, palpitation. Pain in the cardiac region, Hæmoptysis. Extension of the natural cardiac dulness, sounds of the heart confused and imperfect, and indeed replaced by a low, continuous murmur, which might, at times, be almost mistaken for a friction sound.
6	M	60	1847. Fol. 22.	One of the aortic valve flaps greatly ulcerated with shreddy and irregular edges, and in parts almost entirely destroyed. The flap was generally roughened and thickened. Some of	Left ventricle with very hypertrophied walls.	Lung congested. Kidneys diseased. Fibrinous blocks in the spleen.	No history exists of the state of pulse.	No history of previous rheumatic fever, etc. Continued fever with very slight anasarca. Palpitation, dyspnœa, cough, hæmoptysis, pain at the cardiac region. Action of the heart irregular, and

* The preparation is in the Hospital Museum, as No. 27. sub-series 3. series x.

No.	Sex.	Age.	Reference to the Post-mortem Book in St. George's Hospital.	State of the particular valve or valves affected.	General Condition of the Heart.	Noticeable Condition of other Organs or parts of the Body.	State of the Pulse observed during Life.	Leading symptoms whilst in the Hospital, and presence or absence of previous serious disease likely to have affected the heart, and to have caused the valvular lesion.
				the tendinous cords of left ventricle ulcerated through. Mitral valve flaps very thickened.				both cardiac sounds replaced by bruits which are loudest at the base of the heart and up the aorta. The patient died suddenly.
7	F	37	1847. Fol. 26.	One of the aortic valve flaps slightly ulcerated, and all much thickened and contracted. Mitral valve flap also thickened and contracted as well as the tricuspid valve flaps. The left auricle was dilated and the right ventricle also.	Cavity of left ventricle dilated with hypertrophied walls.	Kidneys diseased. Hepatization of lung with extravasation of blood into its texture.	Pulse 100, regular but weak.	No history of previous rheumatic fever, etc. Cough, dyspnœa, anasarca and palpitation. Sounds of the heart generally rather faint and confused, at times, a slight aortic murmur could be traced up the aorta from the heart.
8	F	60	1847. Fol. 50.	Superficial ulceration of the mitral valve flap. The flap generally greatly thickened and stiffened. Mitral orifice very contracted.	Heart large. Left ventricle dilated with thickened walls. Walls of right ventricle also thickened.	Much fluid in pleural cavities compressing the lungs. Kidneys and liver diseased.	Pulse intermitting, weak and irregular.	No history of previous rheumatic fever, etc. Dyspnœa and orthopnœa. Action of the heart tumultuous and intermitting. Heart's impulse increased, and dulness of cardiac region extended. No perceptible bruit existed with either of the heart's sounds, but they were rather confused and the first one was often doubled.
9	F		1847. Fol. 58.	Edge of mitral valve flap ulcerated. Thickening of the flap by calcareous deposit, etc. Mitral orifice very small.	Left ventricle of the heart dilated with thickened walls.	Hepatization of the lung. Kidneys diseased.		A great drinker; admitted in a dying state, with extensive anasarca.

No.	Sex.	Age.	Reference to the Post-mortem Book in St. George's Hospital.	State of the particular valve or valves affected.	General Condition of the Heart.	Noticeable Condition of other Organs or parts of the Body.	State of the Pulse observed during Life.	Leading symptoms whilst in the Hospital, and presence or absence of previous serious disease likely to have affected the heart, and to have caused the valvular lesion.
10	M	30	1847. Fol. 184.	The mitral valve flap presented a large patch of ulceration, in which existed some calcareous deposit, also one or two smaller spots of ulceration. Mitral valve flap generally thickened and having fibrinous fringes attached. Similar fringes attached to aortic valve flaps.	Left ventricle dilated with thickened walls. Ulceration of three or four tendinous cords in left ventricle.	Most of the organs were congested.	Pulse 120, jerking, large, and easily compressible.	No history of previous rheumatic fever, etc. Dyspnœa, palpitation, uneasiness in cardiac region, ascites, anasarca, cardiac impulse, region of dulness increased, loud bruit with both sounds of the heart, as well at its base as the apex, but loudest at the apex.
11	F	26	1848. Fol. 245.	Aortic and mitral valve flaps thickened and stiffened. Recent fibrin on aortic and mitral valve flaps. The attachment of two contiguous aortic valve flaps destroyed by ulceration. Superficial ulceration of auricular surface of mitral valve flap covered by fibrin. Mitral orifice contracted.	Heart's walls hypertrophied. Pericardium everywhere adherent.	Much pleural fluid and lungs compressed. Kidneys diseased. Fibrinous block in the spleen.	No history exists of the state of the pulse.	No history of previous rheumatic fever, etc. Died of continued Fever. Disease of heart not noticed during life, and for two years previously there was certainly no history accounting for any such disease.
12	M	40	1849. Fol. 72.	A few ulcerated apertures at the free, and one near the attached, margin of the semilunar valves of the aorta. Slight atheromatous deposit in the flaps of the mitral valve.	Root of the aorta rather atheromatous. Heart large, with thickening of the walls of the ventricles, espe-	Unusually large ulcerated piles. Vomica and much tubercular matter in both	Pulse the same as usually found in cases of phthysis.	No history of rheumatic fever or other disease. Symptoms, those of phthysis associated with those of sloughing hæmorrhöids.

No.	Sex.	Age.	Reference to the Post-mortem Book in St. George's Hospital.	State of the particular valve or valves affected.	General Condition of the Heart.	Noticeable Condition of other Organs or parts of the Body.	State of the Pulse observed during Life.	Leading symptoms whilst in the Hospital, and presence or absence of previous serious disease likely to have affected the heart, and to have caused the valvular lesion.
					cially of the left ventricle.	lungs. Nothing more worthy of note.		
13	M	33	1852. Fol. 15.	All the aortic valve flaps thickened, and the posterior or middle one had had both of its extremities ulcerated or torn away, and re-united at a much lower level than that of adjoining flaps. This flap was also slightly ulcerated on its arterial surface, and at the left part of it, its structure was greatly thinned, presenting a slightly sacculated condition.*	Much atheromatous deposit at the root of the aorta, and this was so specially in the sinus behind the diseased valve flap. Heart weighed 27 ounces. Left ventricle with hypertrophied walls. Right ventricle dilated.	Lung hepatized in parts, and recent soft fibrin on surface of the lungs. The kidneys and spleen enlarged	Pulse full and very jerking throughout, but no notice of irregularity, etc.	The patient never had rheumatic fever or any serious illness. Two years ago, dyspnœa, with palpitation of the heart, came on. The heart's action was increased and extended over greater extent than usual, and there was a loud bruit, with the diastolic which became double towards the base. Great orthopnœa and hæmoptysis preceded death.
14	M	29	1852. Fol. 40.	One of the flaps of the aortic valve was much thickened, having one of its extremities torn down as if from previous ulceration.	The heart weighed fourteen ounces, and the walls of its left ventricle were much thickened. One or two milk-white patches existed on the heart's surface, and much fluid in the pericardiac cavity.	The pleural cavity on the right side was full of fluid, and the lungs were very congested. The liver and kidneys were very congested.	The pulse was very jerking and thrilling.	There was no evidence of the patient's having ever experienced rheumatic fever. He suffered from anasarca, dyspnœa, and cough. The action of the heart was excited and extended over too large a space. There was a loud bruit which was difficult to locate, but was thought to be diastolic. There was also a slight systolic bruit at the base.

* Diseased aortic valves exist in Hospital Museum, as No. 4*b*, sub-series 8, series x.

No.	Sex.	Age.	Reference to the Post-mortem Book in St. George's Hospital.	State of the particular valve or valves affected.	General Condition of the Heart.	Noticeable Condition of other Organs or parts of the Body.	State of the Pulse observed during Life.	Leading symptoms whilst in the Hospital, and presence or absence of previous serious disease likely to have affected the heart, and to have caused the valvular lesion.
15	M	23	1852. Fol. 157.	The aortic valve flaps were very thickened as to their edges, and one which was especially so, was ulcerated also, and contained a quantity of calcareous and atheromatous material.	The heart was large, weighing 28 ounces, and its cavities dilated. In the substance of the walls of the left ventricle, was a quantity of fibrous material infiltrated. On the anterior curtain of the mitral valve, which was thickened, was adherent a large mass of coagulated fibrin half an inch long, and floating into the cavity of the ventricle. Several small fibrinous de-	Lungs congested; pleural cavity containing reddish fluid. Much fluid also in pericardial sac. Liver congested. Kidneys, large.	The pulse was 130, and jerking.	No bruit existed along the aorta or in the corner of the large vessels proceeding from the aorta. Before death, great dulness and want of breathing existed on the right side with ægophony. There was no history of previous rheumatic fever, etc. He had been ill one year with dyspnœa, cough, and pains in the chest. A loud bruit was heard with the systole of the heart, and diffuse bronchial râles, audible over the chest. The patient died suddenly.

No.	Sex.	Age	Reference to the Post-mortem Book in St. George's Hospital.	State of the particular valve or valves affected.	General Condition of the heart.	Noticeable Condition of other Organs or parts of the Body.	State of the Pulse observed during Life.	Leading symptoms whilst in the Hospital, and presence or absence of previous serious disease likely to have affected the heart, and to have caused the valvular lesion.
16	F	25	1853. Fol. 10.	The aortic valve was composed of four flaps. Two of these flaps were united to each other by their contiguous extremities with thickened margins blended together. They had the appearance of having been ulcerated and torn away from their attachments, where contiguous. and subsequently re-united.*	posits were adherent in various parts. On the surface also of the endocardium, half an inch below the mitral valve, was adherent a patch of old-standing fibrin, and also a small patch of ulceration penetrating deeply into the muscular wall of the ventricle. The heart weighed eleven ounces. The walls of its left ventricle were very thickened.	Ileum ulcerated. Old pleural adhesions and congestion of the lungs existed.	Pulse quick and weak, presenting nothing unusual.	No history existed of rheumatic fever, or other previous serious illness. The patient came into the Hospital with Fever, and diarrhœa, and died thereof. He had been in good health a week or two previously.

* The affected valve is shewn in the Hospital Museum, as preparation 6, sub-series 4, series x.

No.	Sex.	Age.	Reference to the Post-mortem Book in St. George's Hospital.	State of the particular valve or valves affected.	General Condition of the Heart.	Noticeable Condition of other Organs or parts of the Body.	State of the Pulse observed during Life.	Leading symptoms whilst in the Hospital, and presence or absence of previous serious disease likely to have affected the heart, and to have caused the valvular lesion.
15	M	23	1852. Fol. 157.	The aortic valve flaps were very thickened as to their edges, and one which was especially so, was ulcerated also, and contained a quantity of calcareous and atheromatous material.	The heart was large, weighing 28 ounces, and its cavities dilated. In the substance of the walls of the left ventricle, was a quantity of fibrous material infiltrated. On the anterior curtain of the mitral valve, which was thickened, was adherent a large mass of coagulated fibrin half an inch long, and floating into the cavity of the ventricle. Several small fibrinous de-	Lungs congested; pleural cavity containing reddish fluid. Much fluid also in pericardial sac. Liver congested. Kidneys, large.	The pulse was 130, and jerking.	No bruit existed along the aorta or in the corner of the large vessels proceeding from the aorta. Before death, great dulness and want of breathing existed on the right side with ægophony. There was no history of previous rheumatic fever, etc. He had been ill one year with dyspnœa, cough, and pains in the chest. A loud bruit was heard with the systole of the heart, and diffuse bronchial râles, audible over the chest. The patient died suddenly.

No.	Sex.	Age	Reference to the Post-mortem Book in St. George's Hospital.	State of the particular valve or valves affected.	General Condition of the heart.	Noticeable Condition of other Organs or parts of the Body.	State of the Pulse observed during Life.	Leading symptoms whilst in the Hospital, and presence or absence of previous serious disease likely to have affected the heart, and to have caused the valvular lesion.
16	F	25	1853. Fol. 10.	The aortic valve was composed of four flaps. Two of these flaps were united to each other by their contiguous extremities with thickened margins blended together. They had the appearance of having been ulcerated and torn away from their attachments, where contiguous. and subsequently re-united.*	posits were adherent in various parts. On the surface also of the endocardium, half an inch below the mitral valve, was adherent a patch of old-standing fibrin, and also a small patch of ulceration penetrating deeply into the muscular wall of the ventricle. The heart weighed eleven ounces. The walls of its left ventricle were very thickened.	Ileum ulcerated. Old pleural adhesions and congestion of the lungs existed.	Pulse quick and weak, presenting nothing unusual.	No history existed of rheumatic fever, or other previous serious illness. The patient came into the Hospital with Fever, and diarrhœa, and died thereof. He had been in good health a week or two previously.

* The affected valve is shewn in the Hospital Museum, as preparation 6, sub-series 4, series x.

No.	Sex	Age.	Reference to the Post-mortem Book in St. George's Hospital.	State of the particular valve or valves affected.	General Condition of the Heart.	Noticeable Condition of other Organs or parts of the Body.	State of the Pulse observed during Life.	Leading symptoms whilst in the Hospital, and presence or absence of previous serious disease likely to have affected the heart, and to have caused the valvular lesion.
17	M	40	1853. Fol. 217.	The aortic valve flaps were thickened and very hard. The contiguous extremities of two of them had been ulcerated and torn from their attachments and subsequently reunited.	The heart was enlarged, containing one or two white patches on its surface. The curtains of the mitral valve were so thickened, that the orifice would not admit the entrance of two fingers. The chordæ tendineæ were thickened, and the endocardium lining the left ventricle, was much thickened and had several small fibrinous granulations attached to its surface.	Pleural adhesions existed, and the lungs and kidneys were congested.	The pulse was sharp and hammering.	The patient had had rheumatic fever twenty years ago, and latterly had been digging for gold in California, and been subject to rheumatism there. A very loud, double murmur existed at the base of the heart, the second one being rather louder and rougher than the first one. The first sound of the heart at the apex was also roughened. He suffered from dyspnœa, sickness, and great restlessness, and died suddenly.
18	M	44	1854. Fol. 125.	The aortic valve flaps were thickened, containing calcareous deposit, and two of its contiguous flaps were very	The heart was large, and had two or three large, white patches on	The capsules of the liver and spleen were very	No history exists of the state of the pulse.	No assignable cause of illness. Cough, anasarca, for four or five weeks, and ascites. A distinctly double bruit existed at the base

No.	Sex.	Age.	Reference to the Post-mortem Book in St. George's Hospital.	State of the particular valve or valves affected.	General Condition of the Heart.	Noticeable Condition of other Organs or parts of the Body.	State of the Pulse observed during Life.	Leading symptoms whilst in the Hospital, and presence or absence of previous serious disease likely to have affected the heart, and to have caused the valvular lesion.
				adherent, and united to the parietes of the root of the aorta by a single bridle of fibrous tissue, as if they had been previously united to each other and then detached.	its surface. The walls of the left ventricle were very hypertrophied, and the right cavities dilated.	thickened, and those of the kidneys were very adherent.		of the heart, whose action was much increased. Patient gradually sank.
19	M	66	1854. Fol. 327.	Mitral valve flaps rigid and thickened, with contraction of the auricalo-ventricular orifice In the surface of the anterior curtain was a large, ragged opening with thick margins, and having much coagulated blood and fibrine adherent.	Old pericardial adhesions existed. The left ventricle had very hypertrophied walls. Two of the aortic valve flaps were very thickened, containing calcareous matter.	Pleural adhesions of old-standing existed. The lungs were emphysematous. The liver was congested, and the kidneys were diseased, containing numbers of cysts.	Pulse was very weak, but presented no unnatural characters.	No history of rheumatic fever, or assignable cause of illness. Anasarca of six weeks' duration. Large moist crepitation in the lungs, and a loud systolic bruit at the apex of the heart were heard. The action of the heart was great and extended over an unusually large space. Dyspnœa.
20	M	47	1858. Fol. 211.	The anterior flap of the aortic valve was perforated by a hole of the diameter of a pea. This aperture was divided into two, by a portion of the substance of the valve which remained entire. The margins	The heart was large and the walls of both ventricles were hypertrophied. The mitral valve was healthy, but the orifice of the	Pleural adhesions of old-standing existed, and the lungs were very congested. Other organs	No history exists of the state of pulse.	The patient had had rheumatic fever twenty-five years previously, and for the six weeks previous to admission, had been ill with cough, dyspnœa, and slight anasarca. The respiratory murmur was easy when normal,

No.	Sex.	Age.	Reference to the Post-mortem Book in St. George's Hospital.	State of the particular valve or valves affected.	General Condition. of the Heart.	Noticeable Condition of other Organs or parts of the Body.	State of the Pulse observed during Life.	Leading symptoms whilst in the Hospital, and presence or absence of previous serious disease likely to have affected the heart, and to have caused the valvular lesion.
				of the aperture were round, smooth and thickened.*	tricuspid valve was very unusually large. One or two parts of the aorta were thinned and dilated, and above the aortic valve flap which was so much diseased, were two aneurysmal pouches, as well as another pouch above an adjacent flap.	were also congested.		and no dulness on percussion existed in the chest, but a slight systolic bruit was heard at the apex of the heart, and a murmur, with the second sound, was audible at the base of the heart. The patient died quite sudnenly.
21	F	25	1858. Fol. 46.	All the heart's valves were healthy, excepting the *posterior* curtain of the mitral valve, which was perforated by an aperture so large as to admit of the tip of a finger, and surrounded by much fibrinous deposit.† The anterior flap was quite healthy.	The heart weighed twelve ounces and a half, and its cavities were dilated.	Lungs engorged with serous fluid. One of the kidneys contained a fibrinous block. The brain was healthy.	The pulse was always feeble and quickened.	The patient had had rheumatism four months previously, and for one month before admission into the Hospital, had had dyspnœa and cough. A very loud bruit was audible over the apex of the heart, which became fainter towards the base. Before death, the patient had faint paralysis on the right side, and lost the use of the right arm.

* The state of the valve is shown in preparation No. 5/. sub-series iii. series x., in St. George's Hospital Museum.
† This specimen, shewing the affected valve, has been preserved by Mr. Holmes in the Hospital Museum as No. 8/. sub-series iii. series x.

In a review of the details tabulated above, one or two points of interest, at once present themselves. In the first place, one is struck immediately with the fact that all these instances of ulceration exist in the valves on the *left* side of the heart: not in one case have we the tricuspid or the pulmonary valve-flaps been affected. This, no doubt, follows from the fact, that the ulceration was consequent upon such foregoing disease as, owing to circumstances, the left chambers of the heart are mainly obnoxious to. Again, the frequency with which the aortic valve-flaps are the subject of ulcerative processes, in comparison with the mitral curtains is conspicuous; thus, out of the twenty-one cases, there are no less than *fifteen* in which the aortic valves are affected by recent ulceration, or shew signs of having been so affected at some former time, whereas there are only *seven* in which the mitral valve curtains have been similarly affected. It should be, however, observed that in one case, No. 11, we have an instance of the aortic and mitral valve flaps being ulcerated simultaneously. In case six, it is worthy of notice, that along with ulceration of one of the aortic valve flaps, some of the tendinous cords distributed to the mitral segments were ulcerated, these segments themselves were, however, not ulcerated, but only thickened. Case twenty-one is singular in shewing ulceration, and this to a very great degree, of the *posterior* curtain of the mitral valve. In all the other cases in which the mitral valve was so affected, it was as regards the *anterior* curtain alone.

Of the twenty-one, there are only one or two cases, in which ulceration of the affected valve was uncomplicated by any other change. This might have been anticipated, because even when actually recent, it could hardly be that ulceration advancing mostly to perforation, could go on in a single part of the valve's surface, without, at any rate, some thickening from inflammatory exudation taking place around. Possibly, in certain cases, surrounding thickening, and induration or puckering, may have been caused, in good part at least, by the presence of fibrinous material deposited from the blood coursing over the affected valve, which had become adherent and undergone consolidation and contraction at the same time, being as

it were welded into the subjacent valvular surface, and rendering it more or less rough.

As regards the general state of the heart, and especially of the left ventricle, in which this valvular mischief was, I find, that out of the twenty-one cases, there are three, *viz.*, case 2, 3, and 21, in which we have general dilatation of its cavities, (of course the left ventricles are particularly alluded to); eight, *viz.*, cases 1, 4, 5, 7, 8, 9, 10, and 15, in which hypertrophy, along with dilatation of the same cavities, existed; and ten, *viz.*, cases, 6, 11, 12, 13, 14, 16, 17, 18, 19, 20, in which hypertrophy alone is mentioned; of these cases 1, 3, and 15 are remarkable in having dilatation of the *right* ventricle associated. It, however, would be clearly impossible to say what connection there was between the ulcerated valve and the state of the chambers of the heart, inasmuch as that would be in part affected by other conditions of the valves, by certain states of the aorta, and general arterial system, and by disease in other organs as in the kidneys, etc.

In the same way, any deductions concerning the supposed relationship between ulcerated condition of the valve and certain morbid states of important organs like the lungs, would be obviously inconclusive, owing to the existence of other affection of the valves, and to the pre-existence of such general diseased actions as were, doubtless, originally connected with the affection of the valves, leading to ulceration.

It may be remembered, however, that in *one* case only were the other organs of the body found to be free from disease. In nearly all, some disease of the kidneys, or pneumonia existed, and in several cases, crude fibrinous deposits, in the spleen or kidneys, were present, suggesting to one, along with the frequent pneumonia, the existence of some general tendency on the part of the blood to the deposition or precipitation of its fibrin.

As to the prevailing sex of those subjected to ulceration of the valves, it will be seen that seven were females and fourteen were males; a fact doubtless attributable to the more frequent exposure of men to such causes as are sure to induce inflammatory or other alterations in the heart's walls and valves, and thus possibly to lead to ulceration.

As to the matter of age, in two cases I could not obtain the age, but of the other nineteen, I find the average age to be somewhere about thirty-six, an age which probably would rather induce one to look upon some non-inflammatory cause as giving rise, for the most part, to the alterations in the valves, which terminated in ulceration.

As regards the symptoms, and firstly with regard to the pulse, there was nothing whatever at all uniform in its character which could lead to the supposition that ulceration existed in the valves. Of course, should regurgitation be permitted in consequence, the same indications only would exist as occur in the case of regurgitation from more ordinary causes. Just as little would the varied morbid sounds of the heart, owing to the presence of other disease, point to ulceration of the valves. The only way, I imagine, in which any more distinctive symptom could arise in the case of ulceration, would be, when sudden laceration or perforation, whether from extent of this process alone, or owing in addition to some mechanical stress upon the ulcerated flaps, should occur. In this case, the embarrassment and agony would be so sudden in most cases, that it might lead to a fitting diagnosis. On inspecting the table it will be seen, that there is a history of four cases, No. 6, 15, 17, and 20, in which death came on quite suddenly. Of these, two only, *viz.*, cases 6 and 20, shewed actual perforation of the flaps by ulceration, which might have been of quite recent date.

As regards the presence or absence of a rheumatic history, it will be seen that in only three cases was this distinctly traced. It is possible that in some others, it may have existed, and that an imperfect description exists in our records, but on such a subject in these days, the omission is unlikely, and must, at any rate, have been very rare. It is also possible, that, in some cases, rheumatic fever may have existed at a period so remote as to have escaped the patient's memory. The infrequency of a rheumatic history rather accords with the somewhat high average of age of the various patients, and favours the supposition that other causes operated in inducing ulceration. Syphilis, the use of spirits, exhausting diseases, the exanthemata, gout, fever, etc., all would seem capable of predisposing the valves of the heart,

as well as other parts of the frame, to a low, unhealthy process of nutrition, and consequent deposition or softening, etc., as a result of which, ulcerative processes might arise.

Thus, in the above table, whilst enumerating the various cases of ulceration of the cardiac valves, I have not sought in any way to draw a line between ulceration, such as it exists in a veritable form, so to say—the result of genuine endocarditis—from that ulcerous process or erosion which appears to be referable to the softening and ultimate changes brought about in previously deposited atheromatous material, or to the liberation and removal of calcareous substance.

The above arranged twenty-one cases are, in reality, but few in number, compared with the very large number of cases examined after death, in a period of above sixteen years, in which some disease of the valves of the heart existed. In fact, ulceration of the valves, or of any part of the endocardium, is comparatively rare, but in respect of their own experience in the matter, I find by their works, that pathologists differ. I will here briefly quote from a few authors, as a slight review of various statements on the subject may be interesting to this Society. Bouillaud, for instance,* speaks of ulceration as happening sometimes in the acute period of endocarditis, and becoming the origin of perforation of the heart's walls or valves. In one case† which he gives, there was softening and consequent perforation, in two places, of one of the aortic valve flaps; and in another case,‡ one of the mitral valve curtains was perforated by ulceration or erosion. In a third case,‖ there was irregular ulceration, closely allied to gangrene; and in a fourth case, the aortic flaps were covered by superficial ulceration.

Rokitansky speaks of a separation of continuity, happening in intense endocarditis, occasioning a fissure generally jagged, owing to great loosening of the tissue, on which fibrinous material may be deposited, and which may lead to aneurysm of the valves; but the nearest approach which he makes to the actual mention of ulceration is his allusion to the establishment of suppuration

* Vol. ii., page 305.
† Vol. ii., p. 29.
‡ Page 86, *loc. cit.*
‖ Page 87, *loc. cit.*

on some part of an inflamed endocardium,* which may be followed by an ulcerous separation of continuity; or when he speaks of suppuration of the tissue of the valves.† Rokitansky, however does not speak of ulceration of the lining of the heart's cavities or valves with the same freedom as he does of its counterpart, the lining membrane of the blood-vessels, when speaking of them.

Hasse, speaking of ulcers from atheromatous deposit, says,‡ that however frequent in the arteries, there is no good evidence of their development within the cavities of the heart, but remarks, that they have been observed in the valves, quoting from page 99 of Otto's "Rare Cases," and from Bouillaud; Hasse observes, that more than once he had found ulcers of the mitral valve closely resembling those seen in the inside of arteries. He proceeds to say, that ulcers on the inner surface of the heart's walls, are described by others, as existing almost exclusively on the left side of the heart, and in connection with thickening and induration of the valves and atheromatous degeneration of arteries; and that when they take a chronic course, they originate rather in a general morbid predisposition, than in chronic inflammation, and that they are chiefly found in the aged, being more frequent in men than in women. Hasse, quoting from Cloquet, also speaks of ulceration occurring in the left auricle, although it is almost invariably in the left ventricle. I may here say, that I have details of a case, which occurred in St. George's Hospital, of ulceration of the lining membrane of the septum of the auricles, which terminated in perforation of the septum. The observations, a little above, regarding the existence of ulceration of the endocardium chiefly in the aged, are opposed to the results of my cases, as arranged in a tabular form, (see page 135); they accord with those results, however, regarding the relative frequency of males being the subjects of ulceration, rather than females, and, in the fact of the left ventricle being the main seat of the affection.

Hope§ speaks of ulceration of the heart as occurring sometimes

* See Vol. ii., p. 182, pub. by the Old Sydenham Society.
† See page 234, *loc. cit.*
‡ See page 138-9 of his Pathological Anatomy—Old Sydenham Society.
§ Page 210, 3rd edition of his work on "Diseases of the Heart."

from acute inflammation; and says, that it may exist without occasioning any lesion of subjacent tissues. He thinks, however, that acute ulceration is rare, and accounts for it on the supposition, that these ulcers are generally due to calcareous or atheromatous deposit, which is rarely found in the endocardium lining the cavities.

Williams* speaks of the cardiac valves as being subject to ulceration, as also softening and even rupture, along with thickening; but he observes, that it is fortunately *not* common, and that it affects chiefly the aortic valves (see the agreement in this respect between this assertion and the results of my tabulated cases). He alludes to its occasionally supervening in older-standing disease, originating in rheumatism, but states, that he has known it to arise independently of rheumatism (see again the results of my tabulated cases), as after a severe cold or severe strain, especially in spirit-drinkers.

Senac also,† quoting from one or two authorities, as from the famous "Sepulchretum," of Bonetus, mentions cases in which the inner surface of the heart had been ulcerated, owing, as he supposes, to the delicate texture of the lining membrane. And quite recently, Wood, in his Treatise on the Practice of Medicine,‡ speaks of ulceration of the cardiac valves owing to steatomatous and calcareous deposit, and alludes to ulceration caused by inflammation, forming openings through the valvular laminæ, or separating them from their attachments. As regards ulceration from endocarditis, this author speaks of it as being exceedingly rare.

Other writers on the history and pathology of diseases of the heart, there are, who make no mention at all of ulceration of the cardiac valves or endocardium; and I will conclude these notices of the statements of others on this interesting subject, by bringing to mind the observations of Bamberger, of Vienna,§ who describes a loosening and destruction of the texture of the lining membrane in endocarditis, leading to ulceration of the membrane, or even de-

* Page 264, fourth edition of his work on "Diseases of the Chest," etc.

† Page 378, Vol. ii., Traité de la Structure du Cœur.

‡ Philadelphia, Vol. ii., page 166, 3rd edition.

§ Lehrbuch der Krankheiten des Herzens, page 156, also p. 181-5.

struction of the valves; and also, in speaking of valve lesions, holds endocarditis, and a chronic form of exudation, a process identical and generally combined with the atheromatous process of arteries, to be the two causes of such lesions. He looks upon the atheromatous process, as one mainly of old age, and affecting chiefly the *aortic* flaps in contra-distinction to endocarditis which, affecting mostly the young, attacks the *mitral* flaps by choice.

By the above quotations it will be seen, that ulceration of the endocardium, whether that forming the valves of the heart, or that lining the cavities, may be looked upon, as on the whole, of rare occurrence, and this fact, along with the infrequency of its existence in our own Hospital, may, I think, be looked on as a sufficient reason for my dwelling so much at length on the subject in connection with the case forming the heading of this communication. It will be noticed, that whilst quoting the opinions of authors regarding ulceration of the valves, I have included those also upon ulceration of the endocardium in general; indeed, so rarely is the latter met with alone, that, I believe, in our Hospital records, we have only one single case of the kind. For this reason, I have not hesitated, for practical purposes, to look upon ulceration of the endocardium and cardiac valves as synonymous. In what has been above said, I have, of course, not comprehended ulceration caused by abscess, or other such disease of the heart's walls.

The observations above made, in many ways also coincide with the descriptions relative to certain cases of ulceration of the cardiac valves in the Pathological Catalogue of the College of Surgeons. I find that they possess six cases of this form of lesion, but I don't see that the Museum contains any illustrations of ulceration of the general endocardium apart from the valves. Of the above-mentioned six cases, every one proves to be an instance of ulceration of the *aortic* valve flaps, and not one of the *mitral*; of these cases, excepting Nos. 1560 and 1563, all the valves affected by ulceration are thickened and rigid, but in their case, the flaps are described as being thin and unaffected generally. Of these, in one, No. 1563, the affected valve is almost entirely removed by ulceration. It is very remarkable that in No. 1561, a case in which one of the angles of the affected valve was found separated, as if by tearing, from its attachments, the patient appeared to be in

good health, till the day before death, when only the breathing was found to be rather quicker than usual.

But besides perforation of the cardiac valves, to which allusion has been made so abundantly as arising from ulcerative processes, another species of perforation of the cardiac valves is found, not very frequently, however, although more so than those from ulcerations. I allude to those small apertures or deficiencies, described at times, as "cribriform," "fenestrated," "reticular," etc. I incline to suppose them to be, in many cases, congenital. I have examined our Hospital Records for instances of these non-ulcerative perforations, and the results I give at page 153 in Table B. In many of these cases, the perforated flap is quite natural otherwise, but in several, it is noticed as thickened and rigid, etc. In the latter case, possibly, it may be that the small apertures have had fibrin from the blood deposited about their margins, which has consolidated and thickened, and perhaps undergone other changes. In no instances was there reason to suppose that atrophy was the cause of the deficiency. In many cases we might have expected that some cardiac murmur would have been caused by their presence; into this I have not sought, owing to want of time, but it must be noticed that when these apertures, even if of rather large dimensions, exist close upon the edge of the valve flaps, owing to their arrangement when mutually opposed, no blood would be allowed to pass through them, so as to cause any murmur. Dr. Williams* speaks of this, what he calls, atrophous form of disease, as existing commonly in either compartment of the heart, and has seen it "attain its greatest degree" on the right side. It is curious that in the ten cases which I have arranged in Table B, not one occurs on the *right* side of the heart.

In the following table we have a list of cases, as before said, which have occurred in St. George's Hospital, since the year 1841, in which one or more of the flaps of the heart's valves were found to be perforated by foramina or apertures, which were evidently, in most cases, the result of a congenital malformation, and not the effect of disease, such as ulceration. I have, therefore, scarcely given any more particulars than what were immediately connected with the affected valve.

* Page 257, *loc. cit.*

TABLE B.

No.	Sex	Age.	Post-mortem Book.	
1	M.	52	1841. Fol. 140.	The aortic valve flaps were perforated by one or two foramina towards their apices, which were evidently not the results of ulceration, etc. The patient died of scrofulous deposit in the lungs and other parts.
2	M.	40	1841. Fol. 141.	The aortic valve flaps are described as having small foramina at their apices. They were also slightly thickened, but nothing more.
3	M.	41	1841. Fol. 163.	The aortic valve flaps presented some little foramina in their apices, evidently from malformation, but no other changes indicative of disease existed in them, either of recent or old date.
4	F.	20	1841. Fol. 232.	One of the aortic valve flaps was perforated by apertures, described as small deficiencies, obviously congenital. The patient died of rheumatic pericarditis.*
5	M.	53	1844. Fol. 143.	The aortic valve flaps were perforated, and described as being reticular at their apices, and they were also slightly thickened, but nothing like ulceration existed.
6	F.	†	1849. Fol. 120.	The aortic valve flaps were perforated in a cribriform manner, but no thickening or other change existed in them.
7	F.	†	1851. Fol. 109.	The aortic valve flaps are described as having their outer edges thin, shreddy, and perforated in one or two places, and also having calcareous and atheromatous material deposited in them at their bases.
8	M.	46	1851. Fol. 111.	The aortic valve flaps are rendered shreddy by one or two perforations, which were evidently not the result of ulceration. No other change existed in the valves. The patient died of phthysis and pneumonia.
9	M.	34	1856. Fol. 43.	One or two of the aortic valve flaps were cribriform, but they presented no other appearance worthy of note.
10	M.	22	1856. Fol. 175.	One of the aortic valve flaps was cribriform, and all of them were rounded and thickened.

* This case has before been noticed in Table A. *vide* No. I. † Ages not ascertained.

Dr. JOHN W. OGLE, 18*th of March*, 1858.

33. *Heart in which Frothy Blood was found.*

H. B., æt. 44, had lived freely, and enjoyed good health. For the last few months, however, there had been an unhealthy pallor of the face, but he did not complain of indisposition until Wednesday, the 10th of March. There was then some swelling and pain in the fingers. For this he used a warm bath, and whilst walking home, was caught in a snow storm.

The following morning, when I saw him, he was shivering over the fire, the fingers were not better, and there was some stiffness of the left knee. He had already taken an aperient, and was ordered alkalies with colchicum, and a small quantity of opium.

On the 12th of March, he had passed a restless night, the ball of the great toe was red and tender, and he complained of numbness in the hypogastric region. To continue his medicine, and use a blanket-bath at night.

On the 13th, found him in bed, having much difficulty in moving both his legs, with numbness of the thighs, but no loss of sensation. Ankles swollen and red, but not very tender. He had passed urine without difficulty, but it was high-coloured and scanty. There was no shooting pain in the legs, and no tenderness over the spine. Hands much the same; tongue white, and furred, pulse 108, full. The blanket-bath had failed to produce perspiration.

The case, then for the first time, assumed a serious aspect, the inability to move the legs being attributed to a rheumatic affection of the membranes of the spine. Ordered an aperient, followed by calomel guarded with opium every four hours, dry cupping over the loins, and the hot-air bath.

On the 14th, the bath produced profuse perspiration, and the feeling of numbness had disappeared, but he could not move the legs any better. He complained of stiffness of the arms, and had slept badly. The urine had increased in quantity, with a thick lateritious sediment.

On the 15th, calomel beginning to affect the bowels, still sweating profusely, he could with difficulty move his arms. The wrists and elbows were swollen, but not very painful. Last evening felt very nervous, and was slightly delirious, fancying he

saw strange things moving about the room. Slept but little, being roused by violent startings, which did not occur when awake. The startings were so violent that they shook the bed, and he said he felt as if he was being blown into atoms; could move his legs a little. He was always rational when I saw him, and the transient delirium was not accompanied by heat of scalp, intolerance of light, headach, or vomiting. It was usually preceded by a wild appearance of the eyes. The symptoms were attributed to irritation of the cerebro-spinal centres, consequent on profuse perspiration and diarrhœa, with abstinence from stimulants, and loss of rest, in a man who had lived freely. He was ordered to omit the calomel and diuretics, and to take morphia with chloric æther and ammonia. He was also allowed gin and wine.

On the 16th, little sleep, but less starting than last night. Slight delirium this morning, bowels still irritable; could move his legs better.

On the 17th, no sleep, looked better, and there was less sweating; one grain of morphia to be taken at bedtime.

On the 18th, slept little, still some starting, with slight delirium, could move the legs and sit up, but the arms not better. To take opium, and increase the stimulants. In the afternoon, was seized suddenly with twitching of the mouth, convulsive movements of the arms, difficult respiration, and partial unconsciousness, but the attack subsided very quickly, and before I could reach his house. There was no headach, no heat of skin, or injection of the eyes. Sounds of the heart normal, respiration natural.

On the 19th, had taken six grains of opium in fourteen hours, there was less tremor, and he had slept a little at intervals, but not more than two hours during the night. Bowels had been moved four times, the arms better, but the legs becoming stiff, but not so much so as at first. Does not appear affected by the opium; ordered, therefore, to take two grains at bedtime, and one grain every four hours.

On the 20th, was very delirious during the night; but at 6 A.M. fell into a quiet sleep, having taken four grains of opium, he slept till 11 A.M., took another grain of opium and some nourishment, and

slept till 2 P.M. He then awoke, and rapidly became unconscious, respiration stertorous, convulsive movements of muscles of face, pupils dilated, pulse 140.

By speaking loudly to him, he was partially roused, replied to questions, but not correctly; the breathing became more natural, but still hurried, and he was able to take a cup in his hand and swallow. He gradually became insensible; the breathing stertorous, with mucus râles over the chest, and he died comatose, four hours after the commencement of the attack.

Post-mortem examination thirty-six hours after death, in cold weather. Much frothy mucus tinged with blood had escaped from the mouth and nose. Body well-nourished, and no sign of decomposition, except in the neck and upper portion of chest, which were green, swollen, and distinctly emphysematous. On incising this discoloured part, air was found in the cellular tissue. Body when opened extremely offensive, the cavity of the abdomen being distended with air.

Lungs much congested, of a dark-purple colour, breaking down under pressure, and containing frothy serum. They were not adherent, and there was no fluid in the pleura, or any sign of pleurisy.

Heart flaccid, soft, stained dark-red, its cavities held blood mixed with air. The coronary veins were filled with air. Valves healthy, and no sign of pericardial or endocardial inflammation.

Liver slightly granular, and frothy blood spirted from it, when cut.

Kidneys large, of a dark-purple, soft, their capsules readily separating.

Veins on surface of brain, congested, and frothy blood escaped in large quantities from the veins at the base of the brain. Substance of brain pale, and no effusion of serum into lateral ventricles, or beneath the arachnöid. No serum within the spinal canal.

Remarks.—This case is an interesting example of delirium occurring in rheumatic fever, without indication of inflammation of any internal organ, detected either during life or after death, the heart and lungs being examined daily.

Was the air in the blood-vessels, the result of putrefaction, or

did it in any way contribute to the fatal result? It must be admitted, that we cannot distinguish between air, the result of putrefaction and that entering the veins during life, for although Amussat at one time asserted, that when the blood was frothy, air must have formed or entered the vessels during life, yet this was subsequently found to be inaccurate.

My reasons for attributing death to the presence of air, are the following. It is well known that air is sometimes found on opening a vein during life. Durand Fardel mentions a case of sudden illness, in which he opened the median vein, and much frothy blood escaped, the patient died very quickly, and air was found in the heart, etc.

I owe to Mr. Marshall, of Horwick, near Bolton, the particulars of the following case, bearing on the subject:—

"The patient, a strong man, æt. 34, was knocked down by a fall of stone, and received a wound over the right eye, and a contusion at the back of the head. He lay about a quarter of an hour insensible, and then walked home, about seventeen miles and a half, like a drunken man.

"When seen, there was lividity of the lips, coldness of the extremities, and some incoherence of speech. A vein in the arm was opened, and the blood flowed sluggishly, but on passing the hand upwards over the vein, a quantity of bubbles of gas escaped, with a noise that was noticed by the woman who held the basin; after this the blood flowed more freely, and the man felt much better. He had no further bad symptoms, and returned to work in about a week. Could the presence of air account for the symptoms?"

The sudden entrance of air into the veins causes death, in proportion to the amount of air entering, and the rapidity of its entrance, being quickly fatal by distending the right side of the heart, or if death does not immediately ensue, the frothy blood is arrested in the capillaries of the lung, and the patient dies asphyxiated; or if the quantity be small, the patient may recover. In the *British Medical Journal* for last year, I briefly alluded to nine cases of sudden death occurring during, or soon after delivery; and gave the particulars of two cases, which occurred in

my own neighbourhood. In these instances, the presence of air was the only cause to which death could be attributed, and putrefaction could not account for the formation of gas, one of the bodies being examined within six hours after death.

Dr. Cless, of Stuttgart, has published a detailed account of thirteen cases of sudden death, in which air was found in the blood-vessels, and no sign of decomposition present, and no other cause to which death could be attributed.

If we admit that sudden death, may follow the spontaneous generation of air; is there any reason, why it should not prove fatal after a few hours' illness? Last year I published four such cases, one occurring eight days after confinement. In the second there was ulceration of the cæcum, with enlarged kidney, the urine being albuminous. Air was traced from the ulcer to the heart. The third patient was pale, nervous, and feeble, but in her usual health; and was seized suddenly during a catamenial period. Air was traced from the left lateral ligament of the uterus to the heart. There was no air in the left femoral vein, or in the right common iliac.

The fourth suffered from gangrene of the great toe, and air was traced from it to the heart.

In the fifth case, C. S., æt 48, of feeble power, and subject to attacks of bronchitis, was seized on the 24th of October, 1857, suddenly with cough, and quickly became unconscious; I found him livid, with the hands and feet cold, pulse very frequent, respiration hurried, with mucus râles all over the chest; he was quite insensible, and appeared to be dying.

After a short time, he was able to swallow some stimulants, and gradually became sensible. He then expectorated a large quantity of frothy mucus tinged with blood; and in two days was convalescent. He continued well until the middle of December, when he had a similar attack, and on the 30th, a third attack was fatal, before I could reach him.

Post-mortem examination thirty hours after death.—No sign of decomposition; much frothy mucus had escaped from the nose.

Lungs congested, filled with frothy mucus, and the pulmonary blood-vessels contained air. Heart hypertrophied and dilated, containing frothy blood, both in its cavities and its blood vessels.

Endocardium of a vermilion colour. Emphysema of cellular tissue beneath the pleura costalis.

Liver enlarged, slightly cirrhose; kidneys dark coloured, and their capsules separating easily.

The urine was not albuminous.

In the above cases all the *post-mortem examinations* were made within thirty hours after death, there being no sign of putrefaction, and no cause of death could be discovered except the presence of air.

If the spontaneous generation of gas is the cause of death, can we point to any probable reason for its development? In three of these cases, there existed a local lesion, in the fourth, air was traced to the uterus during menstruation. In the other two, there was disease of the kidney. In most of the cases recorded by Dr. Cless, the patients were suffering from blood poisons.

Air has also been found in the blood-vessels in hydrophobia, in poisonings by strychnine, and in several cases of death from chloroform.

Can gas be generated in the blood-vessels, and not prove fatal?

In Mr. Marshall's case, air escaped during venesection, and the man recovered. It was the third attack that proved fatal to C. S., and in one of Dr. Cless's cases, convulsions and stertorous breathing occurred two days before death.

Mr. G. May, Jun., *6th of April*, 1858.

---

34. *Spontaneous Laceration of the Femoral Artery.*

The preparation was taken from a gentleman, æt. 73, of middle stature, and inclined to corpulency, whose habits had been active and temperate, and who had passed the greater part of his life in the offices of a large London Army Agent, and for forty years had been subject to occasional attacks of gout.

Ten years ago, he had albuminuria and slight anasarca. He entirely recovered under treatment, and all trace of albumen disappeared from the urine, nor could its presence be detected from that time till his last illness, though it was occasionally carefully looked for.

For the last four or five years he had been subject to attacks of

giddiness, was a good deal annoyed by numbness and unpleasant sensations in the lower extremities, had grown less inclined for exercise, and was weaker on his legs.

For the last year or two of his life, the attacks of gout were less frequent. During the last few months, he suffered occasionally from attacks of shortness of breathing, with pain in the region of the heart, resembling angina pectoris, and slight bronchial catarrh.

On the 13th of March, I was asked to pay him a visit. On my arrival, about five o'clock, he had just recovered from a fainting fit. This had come on while standing at the fire, and was an entirely new symptom.

He told me that he had felt weak and poorly, without appetite, for three or four days. He mentioned also a pain at the upper part of the left thigh, but did not make much of it—had felt it two or three days. There was no swelling or tenderness.

The sounds of the heart were natural. The pulse a little quickened. The tongue white, as usual. He never had a clean tongue.

The urine was loaded with albumen, but there was no anasarca.

On the 14th of March, he told me that, on going to bed the previous night, he found a slight swelling at the top of the left thigh, near the groin, and that the pain had then left him.

At half-past 4 P.M., he had fainted twice within an hour, and was looking pale. A hard, brawny œdematous swelling occupied the anterior half of the upper third of the left thigh, and there was a decidedly prominent point over the rectus femoris muscle, about five or six inches below the bend of the groin. He was otherwise much the same as the day before.

On the 15th, he had kept to the sofa, in his bedroom, and had not fainted, but appeared a little stronger. The swelling, however, had increased and extended under Poupart's ligament for about two inches. It was hardest at its upper part. Pulsation was perceptible to the eye and touch in the prominent part of the swelling, and ecchymosis to a considerable extent had made its appearance. There was no pulsation in the tibial or popliteal arteries.

It was now very evident, that an artery of considerable size had given way, and I begged Mr. Cæsar Hawkins to see the patient with me. He agreed with me that a large artery, probably the trunk of the femoral had burst. In the uncertainty as to the exact seat of the rupture, the only question of treatment was, whether ligature of the external iliac artery should be attempted, or not. The patient, however, was very fat, the effusion of blood extended higher than Poupart's ligament, the state of the heart and kidneys rendered his condition very unfavourable, and these circumstances, combined with the immediate danger of the operation, and the chance of mortification of the limb, appeared at his advanced period of life, to make such a proceeding quite inadmissible.

On the 16th, he was still much the same in general condition. The swelling had increased, and the prominent spot had become more marked. The ecchymosis had considerably increased. He was again seen by Mr. Hawkins.

On the 17th he was a little weaker. The ecchymosis had extended considerably below the knee, the ankle was slightly swollen, and the swelling in the upper part of the thigh had become softer. In the evening, he became delirious, the pulse was weaker, and beat 120 a minute. The albumen had entirely disappeared from the urine. He became unconscious during the night, and died at forty minutes past 7 A. M. on the 18th.

Post-mortem examination.—Surface of body very pale. No anasarca. The left thigh measured at its greatest circumference, five inches more than that of the opposite side. The swelling and ecchymosis extended downwards to the ankle, and upwards above Poupart's ligament in front, and over the glutei behind. There was considerable prominence in front of the thigh, in the spot above indicated. The fat on the surface of the abdomen, was fully three inches thick.

On cutting into the thigh, the skin and tissues beneath were gorged with extravasated blood, and large clots lay loose among the muscles. At the upper third of the thigh, the sartorius, rectus femoris, vastus internus, and the adductors were more or less broken up by the extravasated blood. The psoas and

iliacus muscles were more or less infiltrated, the anterior crural nerve was raised, and the femoral vessels pushed inwards out of their proper course. The sheath of the vessels contained no coagula above the origin of the profunda. The femoral artery was carefully traced, and removed by Mr. Hawkins, and just as it entered the aponeurotic sheath of the adductors, a large ragged opening was perceived, and in the cellular tissue, around the laceration, small fragments of the fibrous coat of the artery were visible. No traces of any aneurysmal sac could be found.

The internal surface of the artery was thickly covered with atheromatous deposit. The external iliac artery was healthy.

The pericardium was universally adherent to the heart, and in many places the adhesions were converted into bony plates. There was a large accumulation of fat at the base of the heart. The valves and the walls of the ventricles were healthy.

The left kidney was granular, and very much contracted. The capsule very adherent. The right kidney was granular, and somewhat contracted, but in a less advanced state of disease than the left.

The artery was taken to the Museum of the College of Surgeons, by Mr. Hawkins, and was there examined by Mr. Quekett, who kindly reported to me that "the opening had a rough and gnawed appearance, as if proceeding from ulceration. Under the microscope, atheromatous deposit was discernible, with ossific plates. The artery above and below exhibited the same state of disease." The preparation has been put up in the Museum of the College, and the annexed drawing (Plate VI.), gives a very faithful representation of the artery with the lacerated opening.

I have been unable hitherto, to meet with the record of any similar case, nor can I hear of any such from surgeons to whom I have spoken on the subject.

There had been here no symptoms of aneurysm; and so far as the patient knew, no external force had been applied which could have lacerated the coats of the artery. It therefore, appears that softening or ulceration must have existed, and have proceeded to such an extent through the wall of the vessel, as to allow of the breaking down of a very considerable portion before the natural force of the circulation, and to lead to the fatal extra-

DESCRIPTION OF PLATE VI.

This Figure illustrates Mr. A. Leggatt's case of Spontaneous Ulceration of the Femoral Artery, p. 162.

The artery is represented of the natural size. The ragged opening is well shewn at the lower part of the artery, which has been left entire. The origin of the profunda branch is visible at the upper part, which vessel, together with the main trunk of the femoral artery, has been laid open. The lining membrane of these arteries will be seen coated with atheromatous deposit.

An appearance of swelling about the laceration is only apparent, and is due to the loose areolar tissue which has been intentionally left about the vessel.

vasation of blood into the structures of the limb, without the formation of any aneurysmal sac. It is not uncommon to meet with lacerations of the aorta, but I am not aware of any instance in which the atheromatous deposit had led to so extensive a destruction of the entire coats of a large artery as was exhibited in the preparation brought before the Society.

Mr. ALFRED LEGGATT, *6th of April*, 1858.

---

35. *Affection of the Heart, with Enlargement of the Thyröid and Thymus Glands, and prominence of the Eyes.*

The subject of this disease was a female, æt. 26. Nine years before her admission into St. Mary's Hospital, in March, 1858, she had suffered from rheumatic fever; and had ever since been subject to rheumatism. The thyröid gland began to enlarge six years ago. For the last six months, she had been constantly under medical treatment for palpitations.

Her eyes were so prominent that she could not close her eyelids. Nevertheless, she had never been troubled with conjunctivitis. The least exertion, mental or bodily, brought on violent palpitations which were always attended with "dull, wearing pains." The beat was like that of the heart of an hysterical person. A slight systolic bruit was audible over the whole præcordial region. In the second left intercostal space, close to the sternum, a loud, rough, prolonged systolic bruit was heard, and a thrill felt by the finger; the murmur though loud, was very limited; it was constantly present. The patient was highly nervous and excitable. The pupils were of equal size.

Treatment gave only temporary relief. Latterly, her breathing became affected, and she died somewhat suddenly, about two months after her admission into the Hospital.

Post-mortem examination.—The body was very anæmic; the gums were quite blanched. The thyröid gland large and firm, embraced but did not compress the trachea and larynx; the carotid arteries and internal jugular veins were much compressed by it. The thymus gland was remarkably enlarged, weighing two ounces and a half; it passed down along the anterior mediastinum, ending in two lappets, one of which, larger and broader

than the other, lay across the pulmonary artery, and apparently pressed upon it. The structure of the gland was perfectly normal. The heart's valves were slightly thickened, but competent. Its muscular structure was much altered; numerous little patches of firm, white fibrinous matter were scattered through the walls of the left ventricle; the papillary muscles were particularly affected, being partially converted into a dense fibrinous structure. A few atheromatous spots were observed in the coronary arteries, and in the first part of the aortic arch. The lungs were, posteriorly, hepatized. The brain and its vessels were healthy. The other organs of the body of normal appearance.

The bruit evidently arose in the pulmonary artery; it must have been anæmic, or was caused by the pressure of the thymus gland upon it. The opinion of Dr. Stokes, that, in this affection, the heart is not necessarily diseased, is not corroborated by this case, nor by the cases, of which he himself relates the *post-mortem* examinations. Dr. MARKHAM, *6th of April*, 1858.

---

36. *Secondary Abscess from Pyæmia within the Walls of the Heart.*

A male child, æt. 5, was admitted into St. George's Hospital, on March 24th, 1858, in a dying condition, and died next day. He was suffering from extensive caries of the right calcaneum. There were several superficial abscesses in various parts of the body. The lungs contained numerous secondary deposits in various stages; some of them not having softened, others having given rise to abscesses in the substance of the lungs, the walls of which appeared in a gangrenous condition.

The pericardium contained a good deal of sero-purulent fluid, and there was a copious deposit of lymph on the heart's surface. In the wall of the left ventricle was a sloughy cavity filled with decomposed blood, and opening into the pericardium below the auriculo-ventricular groove. The opposite wall of the cavity was just beneath the posterior flap of the mitral valve. No opening was found into the cavity of the heart in this situation, but corresponding to it, a large crop of fibrinous vegetations, stained with blood, was found on the posterior flap of the valve in the

auricle. The cavity was about the size of a large pea. There were several elongated vegetations on the tricuspid valve.

Considering the other morbid appearances in this case, and especially the sloughy condition of the abscesses in the lungs, which were evidently secondary, there seemed no doubt that this cavity, also in the wall of the heart, had originated in secondary deposit and suppuration, and that the bursting of the abscess into the pericardium had evacuated its contents into that sac, and so, probably, set up the inflammation of the serous membrane.

Mr. T. Holmes, *6th of April*, 1858.

---

37. *Large Cyst beneath the visceral layer of the Pericardium covering the posterior surface of the Right Vertricle, and filled with laminated blood-coagulum of old standing; owing, most probably, to the rupture of a Branch of a Coronary Artery.—Calcareous matter in pericardial adhesions.*

The cyst was flattened in shape, and about three inches in length, extending as high as the separation between the auricle and ventricle. To its outer surface at the lower part, the parietal layer of the pericardium was very adherent, as also was the diaphragm, excepting at one part where the connection had been severed, and on very slight traction being excited at one portion the outer wall of the cyst, readily gave way to a greater extent. The walls of the cyst were very firm, and in most parts of considerable thickness. There was no communication between this cyst and any of the cavities of the heart, and it appeared as if the blood had been extravasated at an indefinite period before death from some branch of a coronary artery, all traces of the lesion having been destroyed in the course of time by induration and thickening of surrounding tissues. Most of the blood-clot contained in the cyst, was in the form of a brownish-red granular material, crumbling on pressure; but some of it, though very little, and that entirely confined to the immediate neighbourhood of the walls of the cyst, was disposed in a laminated form. *On microscopical examination,* nothing was found in the contents of the cyst but blood globules in various conditions, mixed with colouring matter and such débris as is

commonly found in old broken-down blood-clot. The pericardial cavity was found to be universally obliterated, and among the adhesions several small masses of calcareous matter were seen. The cavities of the heart were rather large, and the texture of their walls softened—and a portion of the membrane lining the right auricle was very thickened and opaque. In addition, the coronary arteries in various parts were very rigid and atheromatous. The valves and orifices of the heart presented nothing unusual.

After removing the heart from the thorax, extensive and firm pleural adhesions were met with on both sides of the chest; on the right side the pleural membrane was opaque and thickened to a remarkable degree, this was so almost universally, though not equally, being in some places about seven eighths of an inch in thickness. In this, the right cavity of the chest; was a very large amount of clotted blood which was here and there slightly laminated, and chiefly lay in contact with the parietal layer of the pleura. The right lung had been pushed upwards and backwards to a great extent, and had evidently been compressed whilst in that position; the lower parts sinking when placed in water. The left lung was extensively congested, and at the lower parts much hepatized. The kidneys were very granular, and of a deep red hue, and the liver was much congested. The various other organs presented nothing unusual.

History.—The specimen was removed from the body of W. D., æt. 55, who was brought into St. George's Hospital, suffering from anasarca and orthopnœa. His face was very livid, and he was evidently in a very collapsed state. For two years he had been ill with anasarca. His pulse was very irregular and slow. The heart's sounds were rather muffled, and its action irregular and flagging. On the right side of the chest great dulness on percussion existed in several parts, no air finding entrance, and moist, crepitant sounds were heard on the back of the chest, especially on the left side. The urine was slightly albuminous. Wine, stimulants, and sedative expectorants were given, but in vain. He spat up much thin blood-stained fluid and became delirious before death, which took place three days after his admission into the Hospital.

Remarks.—At first sight, the cyst looked like a healed aneurysm

of one of the heart's cavities, but as no communication existed with any of the cavities of the heart, and as its position would have implied the existence of an aneurysm at a part rarely affected in that way, the supposition becomes untenable. Its contents preclude the idea of any formation from the presence of entozoa; and one is constrained by the consideration of its locality, and general appearance, and by the nature of the material within the cyst, to look upon it as being formed by the rupture of some branch of a coronary artery, the resulting extravasated blood making for itself a couch, around which the areolar and other tissues had increased and consolidated, forming thick and firm walls. In consequence of the pressure and growth of this cyst, so constituted, pericardical inflammation and adhesions would arise, and extension of inflammation would give rise to adhesion also of the diaphragm. Such I imagine to have been the progress of the formation of the cyst in question, and I suppose that at some unascertainable time before death, the adhesions and the cyst-wall had yielded, and allowed of the escape of blood into the right pleural sac, which, of course, set up pleurisy, as seen by the *post-mortem* appearances. Dr. JOHN W. OGLE, *6th of April*, 1858.

---

38. *A specimen shewing a large spontaneously healed Aneurysm of the Innominate Artery, along with a smaller one of the Arch of the Aorta.—Death by Phthysis Pulmonalis.*

The aneurysm of the innominate artery which was circular in form, but rather flattened in an antero-posterior direction, and of the size of a cricket-ball, was quite full of firm, laminated, light-brown coloured coagulum; the only softened part of the coagulum, being a small portion of about the size of a pea in the very centre. The aneurysm projected from the anterior part of the wall of the artery, which was in its entire calibre very much enlarged generally, also in a posterior direction actually dilated. The walls of the sac, which were firm, indurated and entire, did not appear to contain any calcareous matter. The aneurysm was very completely adherent to the upper part of the sternum, and the sternal portion of the right clavicle, which was very much thickened and expanded; and to a certain degree, pushed

forwards and upwards by the aneurysm. Slight necrosis also of the sternal extremity of the second rib had been produced by its pressure. The right common carotid artery was completely plugged up by the old standing fibrin, and reduced to the condition of a mere fibrous cord, as high up as the bifurcation into its two main subdivisions, its indurated contents being continuous with the coagulum within the large aneurysmal sac. The right sub-clavian artery was quite pervious, and apparently healthy. The left carotid and sub-clavian arteries were also natural. The root and arch of the aorta were, however, considerably affected by atheromatous deposit, and at a point a little to the left of the origin of the left sub-clavian artery, there was a second aneurysm full of laminated fibrinous coagulum, like to the contents of the larger one above described, but only of the size of a walnut. This was situated on the upper and back part of the wall of the aorta.

History.—The specimen was removed from the body of a man, G. C., æt. 43, who was two or three times admitted into St. George's Hospital, before he died there. He was a sailor, and seven years before death, whilst steering a vessel, during a storm, round the Cape of Good Hope, his right arm (the one on which, doubtless, main stress was laid during his work), became, as it was thought at the time, frozen, and afterwards was found to be nearly powerless. After the space of a few days, he experienced intense pain down the right side of the head, shoulders, and right arm, as far as the fingers' ends; and, during the remainder of his homeward-bound voyage, he was obliged to keep his bed. The pain was looked upon, and treated as if rheumatic on his arrival in England, at one or two of the London Hospitals. Subsequently, he came to St. George's Hospital, and after three weeks, time, a distinct pulsation was discovered, on deep pressure, at the junction of the right clavicle with the sternum. This pulsation increased, and the power of movement in the right arm became lost. He remained in St. George's Hospital for eight months, enduring nearly the whole time, most severe pain. Having at last got very great relief, he left the Hospital, but returned again not very long afterwards. On his admission on this occasion, it was observed that pulsation in the carotid arteries on the right side had entirely ceased, and this

phenomenon was followed by urgent head symptoms. He became perfectly unconscious, but on recovery, he found himself very greatly relieved from pain. Again he left the Hospital, only suffering from debility and some dyspnœa, and was enabled to learn, and subsequently to follow out the calling of a shoemaker, at which he worked for five years. The dyspnœa then increased, and in May, 1853, he again came to St. George's Hospital. It was then found that the sternal extremity of the right clavicle was thrust forward, and the fingers of the right hand hooked into the palm; decided pulsation was found to exist beneath the inner extremity of the second rib on the right side, at a point about one inch to the right of the margin of the sternum. There was found but very slight pulsation in the arteries of the right side of the neck, and this was at the upper part of that region. On the left side of the neck the arterial pulsation was natural. There was cough and dyspnœa; and the pulse was 92 per minute, and equal in force, etc., at both wrists. On auscultation the cardiac sounds were found to be natural in all respects. In the apex of the left lung, behind, the breathing was found to be bronchial, the broncophony existed, but otherwise the respiratory and voice sounds were natural. On the right side sonorous and musical râles and in certain parts, moist crepitations were heard all over the posterior region; anteriorly great dulness on percussion was found at the apex of the lung.

Very urgent dyspnœa with purulent and bloody expectoration set in, and great feebleness with rapidity of the pulse. Anasarca with bed-sores preceded death.

Post-mortem examination.—In addition to the two aneurysms above described, there was found a considerable amount of so-called tubercular matter in the upper parts of both lungs, with many pleural adhesions on both sides. The walls of the left ventricle of the heart were slightly increased in thickness, and the arch of the aorta was atheromatous, but otherwise, neither the heart's walls or valves presented anything worthy of note. The kidneys were somewhat granular and enlarged, and the capsules of the liver and spleen were thickened and opaque. The walls of the abdominal aorta were also somewhat occupied by atheromatous deposit.

Commentary.—Several points of interest in the above case present themselves, both as respects the life symptoms attendant upon the above described aneurysm, and in the morbid appearances presented after death.

It would almost seem clear that the actual cause of this aneurysm, associated or not with pre-existing disease, either of rheumatic or syphilitic origin, of the arterial walls, was some strain or wrench met with by the patient, whilst in the violent duty of guiding the helm of a large vessel during a storm. The effects, not at all accurately enumerated by the patient, of what was deemed cold, the frozen condition of the arm, was, most likely, the immediate results of pressure from some excessive muscular action upon certain branches of the axillary or brachial plexus of nerves. And the same bodily exertion most probably wrought injury, though in a different manner, to the walls of the innominate artery, leading the way to aneurysm thereof. It is, however, possible that these symptoms referred at this time to cold, were induced by direct pressure of the aneurysm upon neighbouring nerves, and that the coats of the vessel gave way at the time of the strain. But, however, one may seek to explain the symptoms following immediately upon the injury, whether by muscular pressure or by that of an enlarged vessel upon adjacent structures, I think the continuous gnawing pains which were attributed to rheumatism, are fairly referrable to the enlarging vessel.

How was the spontaneous obliteration of the aneurysm effected? Was it the result of some alteration in the constitution of the blood, by which its fibrin was rendered more prone to coagulation, effected by treatment and rest, or in some more obscure way. This is a question which is difficult of solution, and would require consideration too lengthy for this communication. I would call attention to the co-existence in this case of a tubercular condition of the lungs with aneurysm, a connection so rare, that Rokitansky found only eight cases out of one hundred and eight of aneurysm complicated with tubercle. He considers that the immunity of those affected by aneurysms from tuberculosis, is "based upon an exhaustion of the materials for tubercle, due to the deposition of a solidifying blastema out of arterial

blood," and that a more decided immunity is brought about "by aneurysms, or a single extensive aneurysm in the proximity of the heart, involving the endogenous coagulation of great fibrinous masses, and a conseqnent hydræmia through defibrination of the blood." I believe, however, that others, in scrutinizing and analyzing various cases of aneurysm, have not found so great freedom from tubercle. It is possible, however, that in the present case, during the time in which the aneurysms were being filled and obliterated, the tuberculosis may have been suspended, and that when the healing of the aneurysms had been perfected, its arrest was no longer carried on, but that the lungs became the seat of scrofulous deposit, which went on to a fatal termination.

It will be remembered that Mr. Wardrop suggested the ligation of the common carotid and sub-clavian, as a means of cure for innominate aneurysm, in accordance with his general proposal for tying the distal portion of a vessel affected by aneurysm. I believe that such a remedy would not find general favour with surgeons in the present day as regards such an aneurysm as the present. At the same time, in connection with this case, it is not altogether by the way to call to mind one communicated by Mr. Wardrop to the *Lancet*,* in which Mr. Evans, of Belper, tied the common carotid artery for aneurysm of the innominate artery and commencement of the carotid. In this case, the patient, a butcher, was restored to health and to his work three months after the operation. How far in my case was there any relation between the spontaneous occlusion of the carotid artery and the healing of the aneurysm like in manner to the healing of the aneurysm by the ligation of the carotid, as practised by Mr. Evans? Most probably, in the present case, the carotid was reduced to the state in which it was found, by virtue of the presence of particles of fibrin dislodged from within the sac, and borne by the blood-current up the artery, where they became arrested, affording a nucleus for deposit, which eventually, with the walls of the vessel, contracted into a cord-like mass. If, then,

* See vol. for 1829, Nov. 8th. This case is also most interesting in other respects, inasmuch as profuse salivation, and a sense of numbness and debility, followed the ligation of the carotid, and lasted until the disordered circulation was re-established.

the healing of an aneurysm of the innominate artery can be promoted by artificially arresting the blood's course through the carotid as by ligature, the same might be supposed to happen, as in my case, when its passage was prevented by spontaneous means.

The contracted state of the muscles of the arm and fingers during life was no doubt occasioned, like the loss of power of motion, by the pressure of the aneurysm upon surrounding nerves; but it is worthy of observation, that no anasarca and no deviation as to the pulse on the affected side was produced. This probably, was due to the sac taking a direction avoiding the sub-clavian vessel, which after death, was found to be patent and unaffected. The pulmonary symptoms might have been referred to the backward pressure of the sac upon the lungs and bronchi had not the tubercular condition found after death sufficed for the explanation of those symptoms.

The freedom from disease on the part of the heart, excepting very slightly increased thickness of the walls of the left ventricle, is note-worthy. One would have expected greater alteration in the left ventricle as secondary to the disease of the vessels.

Dr. John W. Ogle, 20*th of April*, 1858.

---

39. *Spontaneous cure of Aneurysm of the root of the Cœliac Axis.*

This preparation was removed from the body of a man, æt. 69, who died in St. George's Hospital, from dropsy, the result of disease of the heart and kidneys.

The heart was found much dilated and hypertrophied, weighing one pound seven ounces and a half. The valves were natural. The aorta was extremely dilated and extensively atheromatous. In the situation of the origin of the cœliac axis was a large aneurysm, about the size of the fist, opening into the abdominal aorta by a hole about the size of a half-crown, with rounded edges. The sac was nearly filled with laminated and partially decolourized coagula; in the centre the clot was soft, and it seemed as if circulation had gone on through this part. The three branches of the cœliac axis opened out of the part of the tumour opposite to its opening into the aorta and appeared

healthy. One of them (probably the hepatic) wound round the swelling, and was compressed but quite pervious.

The superior mesenteric artery also presented at its base a small aneurysmal pouch, which was empty.

No symptoms had been observed during the patient's stay in the house connected with the aneurysm, nor was he known to have complained of any previously.

Mr. T. HOLMES, *20th of April*, 1858.

---

40. *Specimens of Hypertrophy of the Heart, with remarks on seventy cases.*

Three of these specimens were the largest hearts that occurred in seventy cases of hypertrophy examined by me at the Middlesex Hospital. The *first specimen* weighed thirty ounces, and occurred in a large, muscular man, æt. 33; the history of whose case I am unable to obtain. The pericardium contained about an ounce of bloody serum; two white patches about the size of a penny-piece were situated on the anterior surface. The endocardium appeared thickened, opaque, white, and could be easily pealed off; the columnæ carneæ were atrophied. The aortic valves were covered with shaggy vegetations; and some slight vegetations were seated on the ventricular surface of the mitral valve. A small aneurysmal protrusion of the aorta was situated just above the free margin of one of the valves. The cavity of the left ventricle was four inches in length, and appeared about three times its usual size; the walls of this ventricle measured five lines at the base, seven lines near the middle, and three lines at the apex; the diameter of both the auriculo-ventricular orifices measured one inch and one-seventh of an inch. The aorta was tolerably healthy, and measured three inches and a half in circumference. Both lungs were much congested at the back, and small consolidated portions existed in the lower lobe of the right lung. The liver was healthy; the kidneys very pale and granular.

The *second specimen* also weighed thirty ounces, and occurred in a large man, with a full chest, æt. 62. He had suffered

from chronic bronchitis, and twelve months before death noticed occasional pain about the clavicular regions, accompanied by a frequent beating on the right front of the chest. There was œdema of the legs during the last nine months. The right pleural cavity contained sixteen ounces, the left, eight ounces of turbid serous fluid. Both lungs were adherent at the back, and emphysematous along the anterior margins; the bronchi were much congested. The pericardium contained four ounces of clear serum. The *heart* was much enlarged, felt firm, and weighed thirty ounces; there was a considerable amount of fat about the base, and several indistinct white patches on the surface. The left ventricle was much increased in size, and measured four inches in length inside; its walls were much thickened, and measured six lines at the base, nine lines near the middle, and three lines at the apex (the greatest thickness was twelve lines, opposite the papilla of the mitral valve). The right and left auriculo-ventricular orifices measured one inch and a half in diameter. The columnæ carneæ of the left ventricle appeared very small and atrophied. The valves were not much diseased; the aortic valves were thickened, but still sufficiently large and without any vegetations; the mitral valve presented some opaque white spots. The mitral orifice measured one inch and a half in diameter; the aortic orifice was exactly an inch in diameter. The apex of the heart appeared rounded, and both auricles seemed dilated. The arch of the aorta was dilated to about double its natural size, and was involved in advanced atheromatous disease, which extended upwards into the carotid and axillary vessels, and downwards along the abdominal aorta, into the iliac and femoral arteries. In some parts of the aorta, there were large calcified masses, and so-called osseous plates. The pulmonary artery contained distinct patches of atheromatous deposit, which could be seen even at the bifurcation of the artery in the root of the lung; but these patches were not calcified. Both kidneys were granular; the left contained a cyst about the size of a hazel-nut filled with serous fluid, in which floated a small flocculent mass, slightly adherent to the internal surface of the cyst.

The *third specimen* weighed thirty-six ounces, and occurred in

a man, æt. 28, who had had rheumatism five years before, and had been troubled with dyspnœa and palpitation ever since. He was well-developed, but the legs were œdematous. The lungs were congested and œdematous. The pericardium contained about four ounces of yellowish serum, with a few flakes of recent lymph; the surface of the entire heart was slightly reddened, and somewhat rough near the base. The cardiac substance was firm, moderately red on section, but became gradually paler inwards. The left ventricle was very much enlarged; its cavity measured five inches and a half in length; the other cavities were all more or less enlarged. The wall of the left ventricle measured nine lines near the middle (fifteen lines opposite the papilla of the mitral valve), eight lines at the base, and six at the apex; the columnæ carneæ were much atrophied and fibrous in appearance. The endocardium was opaque, and white near the base; the aortic valves were much shortened and thickened, and of a cartilaginous consistence; the corpora Arantii had quite disappeared; one valve contained a calcified mass the size of a small pea. The aortic orifice proved very incompetent; the left auriculo-ventricular orifice was one-sixth of an inch in diameter, and admitted three fingers easily. The mitral valve contained a few opaque specks of atheroma, and was slightly thickened throughout. The aorta was tolerably sound, and scarcely exhibited a speck of atheroma; the valves on the right side of the heart were tolerably healthy; the pulmonary artery measured three inches and a half in circumference; the right ventricle was two lines thick. In the right auricle there was a slender *fibrous band*, about an inch and a quarter long; one extremity of which was fixed at the tuberculum Loweri, and the other at the Eustachian valve. The liver weighed seventy-four ounces, and was slightly granular; the interlobular substance was somewhat hyphertrophied. The kidneys were partly granular, and contained a little yellowish (fibrinous) deposit.

The *fourth specimen* weighed fourteen ounces and a half, and occurred in a man, æt. 42. He was only three days in the Hospital, and it is noted that he had been subject to palpitation since childhood. On admission, his abdomen was much distended, and he was suffering from general dropsy; his countenance was sallow;

cardiac dulness was more extended than usual; the heart's sounds were very irregular, its action tumultuous; the first sound was accompanied by a soft murmur, the second was a flapping sound; the pulse at the wrist was indistinct; the urine did not contain albumen. On examination, a few white patches were seen on the anterior surface of the right ventricle. The mitral orifice was very much constricted, and presented only a crescentic slit, not quite three quarters of an inch in length; the mitral valves were much thickened and very firm, containing calcified masses which projected through the lining membrane. The aortic valves were shortened and thickened, the adjoining edges of the valves being adherent; on section, large calcareous nodules were exposed. Without entering into further particulars, I may add that this patient had red hepatization of the lungs, pleuritis, serous effusion into the pleura and peritoneum, cirrhosis, and granular kidneys, containing two or three rough calculi.

Remarks.—I regret that the medical history of these four cases should be so imperfect, but as they only came under my observation after death, and had not been in the Hospital for more than a few days, I was unable to obtain any fuller accounts. It is interesting to notice what great hypertrophy occurred with comparatively little valvular disease in the first three cases; in the heart which weighed thirty-six ounces there was scarcely any valvular disease; and, on the contrary, it is astonishing how little hyphertrophy may occur with extensive disease of the aortic and mitral valves, as in the fourth specimen, which weighed only fourteen ounces and a half.

With regard to the *fibrous band*, in the right auricle of the third specimen, it appears doubtful whether this was a relic of fœtal life, or the result of disease. In the Middlesex Hospital Museum there is a preparation (vi. 10, *g*.) which exhibits a similar band; it does not belong to this series of cases, but as it appears uncommon, it is worth notice. The band extends from the so-called tuberculum Loweri to the free margin of the posterior flap of the *tricuspid* valve; it is about an inch and a half long, and a fibrillated network is suspended from its middle third. It is noted that it occurred in a boy, æt. 16, and produced

a "tricuspid murmur." The tricuspid valves are thickened, and atheromatous patches are seen in the pulmonary artery. The left ventricle is hypertrophied and dilated, and the aortic valves are shortened and thickened. I met with a third specimen of a fibrous band in the right auricle a few days ago, the history of the case is altogether unknown to me. The band is about two inches long, and gives off numerous tendrils, which form a kind of floating network; the extremities are fixed at the tuberculum Loweri, and near the attached margin of the tricuspid valve; a part of the heart has been cut away, but there does not appear to be any disease of the other valves.

Hypertrophy of the heart occurred in seventy cases out of three hundred and eighty *post-mortem examinations* conducted by me; that is, in 18·4 per cent. of the patients dying from various diseases. Under the term hypertrophy I include all those cases in which the heart weighed upwards of fourteen ounces in the adult male, and upwards of twelve ounces in the female.* A portion of the great vessels arising from the heart, about an inch in length, is included in the weights; but the coagula were always removed, and the heart washed, before weighing. Of the seventy cases of hypertrophy of the heart, forty-six were males, and twenty-four females; that is, nearly twice as many males as females. The average age of the forty-six males was 43·3 years; one was æt. 16; one 18; the rest varied from 22 to 66. The average weight of their hearts was 19·3 ounces, the heaviest being thirty-six ounces. The average age of the twenty-four females was 41·6 years; one was æt. 16; one 17; one 20; the rest varied from 22 to 74. The average weight of their hearts was 15·6 ounces; the heaviest weighed twenty-six ounces, and occurred in a woman æt. 22.

The *principal morbid appearances, associated with hypertrophy of the heart,* in these seventy cases, were as follows:—

1. Disease of the aortic valves, in thirty-six cases; of the mitral, in thirty-two cases. This includes atheromatous disease of the valves, fibröid thickening, etc., producing insufficiency, constric-

* Allowing for slight variations in size without the existence of disease, I have in the meantime fixed upon these weights as being decidedly beyond the range of health.

tion of orifices, etc. The disease affected both the aortic and mitral valves in twenty-two cases, leaving fourteen cases of disease of aortic valves only, and ten cases of disease of the mitral valves only.*

2. Vegetations on the aortic valves, in nine cases, on the mitral valves in five cases.

3. Adherent coagula and globular vegetations in the heart, in three cases.

4. Carditis (fibröid patches in substance of heart), in four cases.

5. Serous effusion (above two ounces) in pericardium, in six cases.

6. Pericarditis (with recent lymph in pericardium), in six cases.

7. Adherent pericardium, in nine cases.

8. Fatty degeneration of heart (extreme), in one case.

9. Atheroma of aorta (well-marked), in thirteen cases.

10. Atheroma of pulmonary artery, in one case.

11. Atheroma of cerebral arteries, in two cases.

12. Atheroma of arteries of the extremities, in two cases.

13. Obstruction of axillary and femoral arteries, in one case.

14. Cerebral hæmorrhage, in four cases.

15. Softening of the brain, in five cases.

16. Serous effusion (above four ounces), into the pleuræ, in ten cases.

17. Pleuritis, with recent lymph in pleural cavities, in eight cases.

18. Carnification of the lungs, in seven cases.

19. Hepatization of the lungs, in sixteen cases.

20. Bronchitis, in ten cases; with extreme emphysema, in four cases.

21. Chronic pneumonia (induration of pulmonary substance), in five cases.

22. Tubercle of the lungs (in different stages), in seven cases.

23. Cicatrices and chalky concretions in the lungs, in eight cases.

24. Pulmonary apoplexy, in six cases.

25. Serous effusion into the peritoneum, in nine cases.

* The valves were healthy in eight cases, and nearly healthy in five cases.

26. Granular disease of liver (cirrhosis), in twenty-one cases.

27. Serous effusion (above eight ounces), into peritoneum, in nine cases.

28. Fatty degeneration of the liver, in three cases.

29. Granular degeneration of kidney* (including all forms of Bright's disease), in forty-six cases.

30. Fibrinous deposits in the kidney, in six cases.

31. Inflammation of the kidney, in one case.

32. Fibrinous deposits in the spleen, in three cases.

33. Cancer of the uterus and lungs, in one case.

34. Œdema of the legs, in two cases.

The eight volumes of our "Transactions" contain accounts of forty cases of hypertrophy of the heart, in which the weights are given, and about as many in which the weights are omitted. Of these forty cases, thirty-four were males, and only six females. The average age of thirty-one of the males was 44 years; three were aged 18; one 19; the rest varied from 21 to 91. The average weight of the heart of the thirty-four males was 22·1 ounces; the heaviest weighed 40 ounces.† The average age of the six females was 37·5 years; one was aged 16, the rest varied from 34 to 58. The average weight of their hearts was 17·5 ounces.

In these forty cases, disease of the aortic valves occurred in twenty-eight, and of the mitral valves in seventeen. In fourteen cases, aortic and mitral disease co-existed, leaving fourteen cases with disease of the aortic valves only, and three with disease of the mitral valves only.

From this analysis of my observations, and of our records, it appears:—

1. That hypertrophy of the heart occurs in nearly eighteen and a half per cent. of patients dying from various diseases.

2. That hypertrophy of the heart is about twice as frequent in males as in females; or, exactly as eight to three.

3. That the average age of males and females is nearly the same; that of the males being 43·6 years, and of the females 39·5.

* The kidneys were decidedly healthy in five cases.

† It is described by Dr. Peacock, in an admirable paper on the "Weight and Dimensions of the Heart in Health and Disease," in vol. vi., p. 119 of the "Transactions."

4. That in hypertrophy of the heart, disease of the aortic valves is more frequent than disease of the mitral, as eight to six.

5. That in hypertrophy, vegetations are more frequently situated on the aortic than on the mitral valves.

6. That adherent pericardium exists in about one-eighth of the cases of hypertrophy; and,

7. That granular disease of the kidneys occurs in about two-thirds of the cases.

The *relations* of hypertrophy of the heart to other diseases have been already stated.

Dr. Van der Byl, 20*th of April*, 1858.

---

41. *Aneurysmal Dilatation of the Arch of the Aorta; chiefly within the Pericardium.*

G. H. H., æt. 45, first came under my care on the 5th of January, 1858. For twenty-three years he had been a soldier in one of the regiments of the line, and had served in Canada, the East and West Indies, and St. Helena: he had been of remarkably steady and sober habits for a year or two past, and had been a gentleman's servant, where there was a good deal of running up and down stairs, but the place was not otherwise a hard one. He had enjoyed fair health, and, when first inquired of, stated that he never had rheumatism; on further inquiry, however, it appeared probable that an illness which confined him some days to bed, when at St. Helena (his last station), was rheumatic fever of moderate severity. His breath had been shorter than before for about two years past, and especially bad for ten days, about the commencement of which time he had much shivering; for five days a cough had been present with some expectoration, but he had never had hæmoptysis of any kind. It was in consequence of his breathing having become very short that I was requested to see him.

I found that he was suffering from an attack of pneumonia, chiefly affecting the left lung, which dated, doubtless, from the time when the shiverings occurred; his pulse was 108; his respirations were 40.

There was old-standing disease as well. The heart's impulse was felt over a very extensive surface, and it was, besides, exceedingly strong; the impulse was most marked over the lower part of the normal cardiac region, and, also considerably below and to the left of left nipple. The cardiac dulness on percussion was likewise much too extensive, but anteriorly there was no dulness beyond that caused by the heart itself, except a slight amount, a little to the right of the upper part of the sternum, where it was most marked (yet by no means considerable) at the junction of the second rib with its cartilage; at this point there was also a slight impulse perceptible. A very loud, double murmur was audible over the whole of the base of the heart, the systolic and diastolic murmur being of about equal intensity and very rough; the point at which the murmurs were most marked was about the second right costal cartilage, but they were nearly as loud down the right border of the sternum for about two-thirds of its length from the top. There was a double murmur likewise at the apex of the heart, but very much less loud than at the base, from whence the sounds were probably transmitted.

Some of the attacks of dyspnœa, which he described having had during a few months before I saw him, presented somewhat of an anginose character.

The diagnosis was, from the first, that the man had aneurysmal dilatation of the aorta, chiefly situated within the pericardium; and the further progress of the case, and subsequent examinations, tended to confirm the opinion. He was relieved as regards the pneumonia, and for awhile he felt much better; but the cardiac and aneurysmal symptoms subsequently increased, his dyspnœa was more severe, and distinct paroxysms of angina occurred; occasionally he expectorated a little blood, and anasarca was added to his sufferings. He died on the 17th of March.

There was much congestion of both lungs, with the remains of pneumonia at the bases; otherwise they were healthy. The heart was of enormous size, being both greatly dilated and hypertrophied; both auricles and both ventricles were much distended with coagula; from apex to base it measured (*in situ*) six inches and a quarter, and across the base fully six inches and a half. The

aorta presented a very great amount of dilatation, especially that part of it within the pericardium; at one inch from the ventricular opening it measured, unopened, two inches and three-quarters in diameter; at the origin of the innominata, one inch and three-quarters; and about that of the left sub-clavian, one inch and a quarter. The arch of the aorta was much thickened, and was much harder and less yielding than natural; its inner surface was very rough from atheromatous deposit, which occupied every part of its circumference, especially near the ventricular orifice; the orifices of the coronary were also completely surrounded by this deposit, but did not appear to be closed in consequence, or the diameter of their orifices to be materially diminished. The aortic valves were thickened, and two of them partially united, while the septum thus formed between them was contracted, so that their edges were drawn down; thus, at the same time, giving rise to a partial obstruction to the course of the blood, and likewise allowing of its regurgitation. A large clot extended through the aortic orifice at least four inches along the aorta, and, at its broadest part, it was one inch and a half in diameter; but it was soft, and evidently recent. No coagulum whatever, was adherent to the walls of the dilated aorta. The was no valvular disease of the right side of the heart, and the mitral valve, though large, was healthy; so that, as suspected during life, the murmurs heard towards, and at the apex, were due to conduction from the base. Dr. HARE, 18*th of May*, 1858.

---

42. *Aneurysm of the Aorta fatal, by bursting into the Œsophagus.*

I was sent for, on the 11th of April, to visit Mr. M., æt. 54, who was suffering from faintness and exhaustion, and had for some months been unable to sleep without opiates, owing to pain in the loins. For this I had attended him two years previously, when he was relieved by opiates at night, and iodide of potassium three times a day. He always felt great relief after a free evacuation of the bowels, but that was, of course, never more than temporary. He had consulted other gentlemen since I had seen him, without deriving any benefit. He was the subject of double fracture of both patella, which had, in every instance, been caused

by muscular contraction, called into play to save himself from falling.

At the period of my visit to him, he was complaining of slight moist cough, with expectoration, which was occasionally streaked with blood. He had also considerable nausea, but did not vomit. He was anæmic. His countenance was anxious, and strongly impressed me with the idea that he had some fatal disease about him. His pulse was feeble, but regular, and was equal at both wrists.

The action of the heart was feeble, but healthy, and without any unnatural sounds. No bruit could be detected in any portion of the chest. I usually found him lying on his back on a sofa, with his legs drawn up, which he described as the most easy position he could find. Bowels constipated from the opium he was taking; evacuations healthy in appearance; urine plentiful, and healthy.

For ten or twelve days he improved under treatment. His face had, in a great measure, lost its anxious and exsanguine appearance; the cough had abated, the expectoration was diminished, and he was able to take a little gentle exercise. A few days later, however, he began to loathe his food, and had nausea and sickness, with an increase of cough and bloody expectoration. His nights became more restless, and he awoke in the morning exhausted and unrefreshed. Otherwise he was not, apparently, worse.

On the 2nd of May, three weeks after my first visit to him, he expressed himself as better, and had allowed his attendants to go out to dinner; he got up alone between twelve and one o'clock, and dressed himself, without assistance. He appeared to have walked from his bedroom into his drawing-room adjoining. Here he had expectorated some blood into the fender. About one o'clock a noise was heard in his room, and on the servant going up to him, he was found on the floor surrounded by a pool of blood. He breathed two or three times, and then died.

Post-mortem examination twenty-four hours after death.—Rigor mortis imperfect; skin sallow, not unlike that of a person suffering from malignant disease. The body was muscular, with a fair amount of adipose tissue over the abdomen; on raising the sternum and costal cartilages, the heart was found to be slightly

pushed toward the right side; it was small and flaccid, but otherwise healthy. The pericardium contained a larger quantity of serum than usual. On raising the pericardium, a tumour, looking very much like another heart, was observed behind and somewhat to the left of the heart. It was as large as a full-grown fœtal head, and was attached firmly in front of the spinal column; it extended along the six lower dorsal vertebræ, behind and between the crura of the diaphragm, which appeared to support it on either side, and to retain it in front of the spinal column, and thereby prevent its deviating to either side; it came also in contact with the ribs. This proved to be an aneurysm of the aorta, as large as a full-grown fœtal head. On removing it from the body, it was found to have produced absorption of considerable portions of the bodies of the four lower dorsal vertebræ.

The sac of the aneurysm, which was thick, especially in front, contained the usual laminated coagula, together with recent coagula, and a quantity of fluid blood. The aorta was much thickened and dilated, and was atheromatous in the whole of its course above the aneurysm; but below was healthy.

An aperture four lines in diameter, communicating with the aneurysm, was found in the œsophagus, about two inches from its entrance into the stomach, through which about half a hand-basinful of blood had escaped into the stomach, besides what was found around him at the time of his death.

The lungs were healthy. The stomach, and other abdominal viscera, were healthy. The pressure of the tumour had, however, produced absorption of a considerable portion of the posterior part of the liver, as well as the left kidney. The right kidney was larger than usual. Mr. Part, 18*th of May*, 1858.

---

43. *Case of Aortic Valvular Disease, with Obstruction caused by a Band of Membrane extending across the outlet from the Ventricle.*

The specimen was removed from a waterman, æt. 57, admitted into St. Thomas's Hospital, under Dr. Peacock's care, in October, 1857. He had been subject to rheumatic attacks for many years, and had been seriously ill for twelve months, suffering under

cough, expectoration, occasionally bloody, palpitation, and dyspnœa. These symptoms were greatly increased on any slight exertion; he had been dropsical for some weeks. A loud, systolic murmur was audible over the whole præcordia, and was heard most intensely at the right side of the upper part of the sternum, and at the level of the third left cartilage. There was no distinct diastolic sound or murmur; the pulse was jarring and rapidly disappeared under the finger. The liver was considerably enlarged, extending some distance below the ribs; the abdomen was tumid and the lower extremities were very œdematous. While in the Hospital, he had repeated eruptions of purpura on the lower extremities, which after continuing for a day or two, disappeared and recurred in about the same length of time. He died on the 23rd of December.

The *post-mortem examination* was conducted and reported by Dr. Bristowe.

"Both pleuræ presented old adhesions, which were especially firm and abundant at the apices, and the cavities contained a little serum. The lungs were voluminous, the apices were puckered, somewhat indurated, and presented numerous emphysematous masses, from the size of a marble downwards. The anterior edges of the upper lobes were slightly irregular and inflated, and possibly, a little emphysematous. Both lungs were crepitant throughout, but the lower lobes were congested, œdematous to an extreme degree, and somewhat more lacerable than natural. In the apex of each organ were several indurated patches, and isolated miliary masses; and in that of the left, was a cavity, about the size of a horse-bean, the parietes of which were thick, fibrous, and reticulated, while the surface of the lung over it was drawn in, and the resulting depression was occupied by radiating, cellular tissue. The bronchial glands were enlarged and blackened. The bronchial tubes were congested, and contained much frothy serous fluid.

The pericardium was somewhat congested, and a few petechial spots were observed at the base of the heart. There were large white patches, chiefly on the surface of the right ventricle. The heart weighed nineteen ounces and a half avoirdupois. The walls of the left ventricle were thick and firm; the cavity was

small, and contained scarcely a trace of coagulum. The aortic valves were much diseased; they were thickened and altered in shape, and the right segment presented a small perforation near the centre, and its free margin was connected with that of the posterior valve by a thick, nodulated, elastic band, which extended along nearly the whole length of the edge of the posterior curtain in a fringe of vegetations, and formed in its course a kind of bridge over the angle between the two valves, which left an irregular opening. The lining membrane of the ventricle, for half an inch below the valves, was considerably thickened, and near the lower limit of this thickening, was a cicatrix-like constriction, which extended transversely all round, excepting at the part which corresponded to the base of the anterior curtain of the mitral valve. In this way the opening from the ventricle into the aorta was greatly contracted, so that it would only allow the passage of the point of the forefinger.

All the sinuses of Valsalva were dilated, but more especially that corresponding to the posterior valve, and from this a small triangular aperture opened into an aneurysmal cavity, about as large as a horse-bean; another, but smaller aneurysm, existed between and above the angles of the posterior and anterior valves. The mitral valve was healthy. The walls of the right ventricle were thick and firm, and the cavity was contracted and nearly empty; its valves were healthy. With the exception of the liver, spleen, and kidneys, which were large and congested, the organs of the abdomen were healthy.

Dr. Peacock, 18*th of May*, 1858.

---

44. *Extensive Nævus, involving the whole of the Right Leg, in Different Stages of Development.*

G. D., a boy, æt. 4, was brought to me, at Guy's Hospital, upon the 4th of February, 1858. He was excessively blanched from loss of blood, and anasarcous. His pulse was very feeble, and he appeared almost in a dying condition.

His right leg presented the appearances as represented in the drawing (Plate VII), and copious hæmorrhage had taken place from the warty growth upon the buttock.

DESCRIPTION OF PLATE VII.

The Figure illustrates Mr. Thomas Bryant's case of Nævus of the Leg, in various stages of development, p. 186.

A. The subcutaneous veins.

B. Earliest staining of the skin.

C. and D. Latent conditions.

E. The warty growth characteristic of cystic degeneration of the veins.

In parts marked A, the growth was purely of the sub-cutaneous character; in others, the skin was more or less involved. Letter B represents the earliest staining; C, a more advanced condition; and D, a still later stage. The last of all is well represented in letter E, where the disease has commenced its cystic degeneration, as represented by the warty growth, which is peculiar to such structures, and from which severe bleeding had taken place.

At birth, there was a small, red spot upon the buttock, and the veins of the leg were always enlarged. This spot has since gradually increased and degenerated to its present condition.

The other spots have made their appearance at different intervals. For the last month, bleeding had taken place, almost daily, and all efforts to suppress it had failed.

I gave the child tonics, and applied daily the perchloride of iron to the warty growth; under this treatment, the spongy character of this structure gradually contracted, and diminished nearly one half in size; no more bleeding took place, and the boy's health became re-established; in other parts, the disease appeared gradually to progress, the skin, whilst under treatment, in many spots, had become involved, and in spite of pressure by bandaging, etc., it continued its course.

The child is now well in health, and can walk about, but with the disease still in a progressive condition.

The drawing well shews the pathology of this disease, in all its different stages, from the purely sub-cutaneous form, to the earliest staining of the skin, on to its last or degenerating cystic condition.

The disease appears to be confined to the veins and capillaries, the arteries being apparently of the normal size. By the history, it would appear that the disease was in its origin generally sub-cutaneous, and that it involved the skin in one spot only, the other cutaneous nævi being evidently extensions of the original sub-cutaneous form.

The warty and cystic growth, well illustrated by the drawing, and still better by a model in Guy's Museum, is quite characteristic of these structures, the warts being soft and spongy, of a deep purple or red colour, and easily bleeding. The

cysts are at times developed in them, or rather appear as if they were formed from them, and are found in similar cases, distributed throughout the growth. In certain spots cysts are very evident, and this leads me almost to believe that by this degeneration, a cure may eventually take place.

Dr. THOMAS BRYANT, 18*th of May*, 1858.

IV. DISEASES, ETC., OF THE DIGESTIVE ORGANS.

I. PHARYNX, ŒSOPHAGUS, STOMACH AND INTESTINES.

1. *Tubular Exudation Casts of the Intestine.*

The lady, by whom these specimens were voided, is a patient of Dr. Dunhill, of Cranbrook in Kent. She has long suffered from this peculiar disease, and I have now by me, a series of bottles, which have been sent me at different periods, during the last two years, and which contain many yards of these curious casts. They are perfect cylinders, and many of them several feet in length, being sufficiently coherent to permit of their being handled, held up, etc. They have kept well in weak alcohol, and still preserve all their characters.

The following is the *history* sent me by Dr. Dunhill:—

Miss M. W., æt. 49, has not enjoyed good health for twenty years. Her first illness was an attack of influenza, followed by diarrhœa, and after this, she was an invalid for several years with a "spinal complaint." In 1849 and 1851, she had repeated attacks of diarrhœa, and in 1853, had one which continued for four months. During this last, she states, that she passed "quantities of blood, and of brown thick skins, four or five inches long." The bowels were afterwards, alternately, obstinately confined and much relaxed. In 1854, "the skins" which came away were longer than they had previously been, and she was never more than a few days at a time without voiding them. About this time, she suffered much from constant pain in the epigastrium, and almost daily vomiting of mucus and pus streaked with blood, occasionally vomiting pure blood. Subsequently, the pain left

the epigastrium, and settled in the left iliac region. For the last eighteen months, the pain has been in the right iliac region. The pain in this situation is always much aggravated for a few days prior to the voiding of larger or thicker casts, or of greater quantities of them. As they became fewer in number, and thinner in structure, the pain usually diminished, but she is never free from some degree of tenderness. When confined to bed the casts are apt to be retained in the rectum, and become packed. An enema will then bring them away as hard, round, white masses, about the size of nutmegs. Occasionally the casts contain masses of fæcal matter.

With regard to treatment, a great variety of measures have been tried, without as yet any material benefit. For the first twelve months she was restricted to a farinaceous diet, and took a long course of alteratives. Counter-irritants were also repeatedly used and a large blister on the abdomen was kept open for six months. A more mixed diet was subsequently allowed, but she still notices that she is always worse after having taken meat, for a few days. A long course of pitch pills was given at one time, but without advantage. The mildest aperient always increases the abdominal pain, and the number of casts expelled. The bowels being costive are usually relieved by a warm-water enema, every other day.

I have seen several other examples of this chronic exudative enteritis. One, which affords a very close parallel to the above, came under my notice about two years ago, in the York Hospital, its subject being a pale cachectic man, æt. 23. I then watched his case for nearly a year, when, in spite of all treatment, the voiding of the casts persisted. Two years later I saw him in London, and he then told me that he still suffered the same symptoms, and from aggravated dyspepsia.

Mr. Hutchinson, *20th of October*, 1857.

Report on the above specimen.—The matters submitted to us for examination consisted of membranous shreds and tubes, which were so soft, as to permit of manipulation only under water. As the membranous shreds were found after careful examination, to be nothing more than fragments of tubes, they need no separate

description. The tubes occurred in pieces, of from one to four inches in length, and of about an inch and a half in diameter. The wall of each tube varied in thickness, from one-eighth to one-fourth of an inch. The matter composing the walls of these tubes exhaled a strongly feculent odour, was of a light yellowish-brown colour, semi-transparent, of gelatinous consistence, slightly tenacious, and studded with light-brown coloured dots and opaque arborescent lines. The outer surface of each tube was moderately and uniformly smooth; the inner was at some parts broken and flaky, at others, ragged and flocculent, and in many places thrown into shallow folds, lying in some parts across, but chiefly along the axis of the tube. At most points the wall of the tube appeared to consist of a single lamina; at a few points it was composed of several laminæ, the inner ones of which were imperfect, and had inserted between them particles of various kinds of undigested food.

A portion of tube laid open in the direction of its long axis, transferred to a glass with its inner surface upwards, and examined with a linear magnifying power of forty diameters, exhibited the appearance of a gelatinous membraniform matrix (Plate VIII. Fig. 1), traversed by a coarse network of opaque yellow lines, and studded at their points of intersection by similarly coloured, rounded masses. From the larger network proceeded a smaller secondary network, and in the meshes of this were found at close and regular intervals, well-defined round or oval openings, with elevated margins resembling in size and appearance the mouths of the follicles of the greater gut. With a magnifying power of three hundred and fifty diameters, the nature and relations of the parts described were more minutely ascertained.

The matrix was transparent, structureless, elastic, and everywhere free from fibrillation. It was perforated at regular intervals, by the openings already described. Embedded in it were granules, free nuclei, cells, crystals, and particles of undigested food. Upon its free surface were the opaque yellow lines and dots, which were composed of various foreign matters, such as bile pigment, earthy and fat granules, portions of husks of seeds, gritty tissue of pear, a peculiar form of elastic tissue, stellate vegetable hairs, and a mucedinous fungus. The cells embedded

DESCRIPTION OF PLATE VIII.

Figures 1 and 2 illustrate Dr. A. Clark's Report on the Microscopical Structure of Mr. J. Hutchinson's Intestinal Casts, p. 190.

Fig. 1. Represents a portion of the cast, magnified 40 diameters.

a. Mouths of follicles.

b. Substance of cast, consisting of greatly elongated cylinder and other epithelial cells, matted together by altered mucus.

Fig. 2. Diagram. Cell-forms from the broken-up matter composing the casts.

a. Cells in various stages of growth, like epithelial cells.

b. Cells of an hour-glass form, as if multiplying by division.

c. Elongated cylinder-epithelium mostly matted together; a few contained fat-granules.

d. Granule-cell.

e. Cells like those found in ephithelial cancer.

f. Cells with vacuoles.

g. Organic crystals.

The preparations from which these drawings are taken are in the collection of Dr. Andrew Clark, and may be examined by anyone interested therein.

Figure 3 represents Cells from Dr. Sydney Jones's case of Epithelial Cancer of the Œsophagus, p. 203.

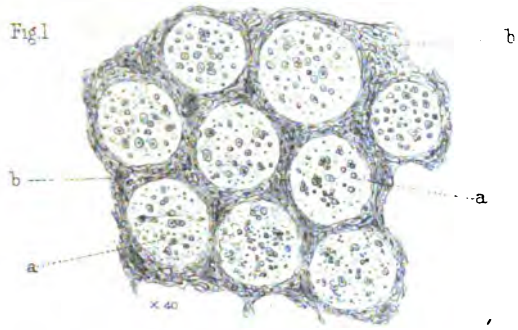

Dr A. Clark del

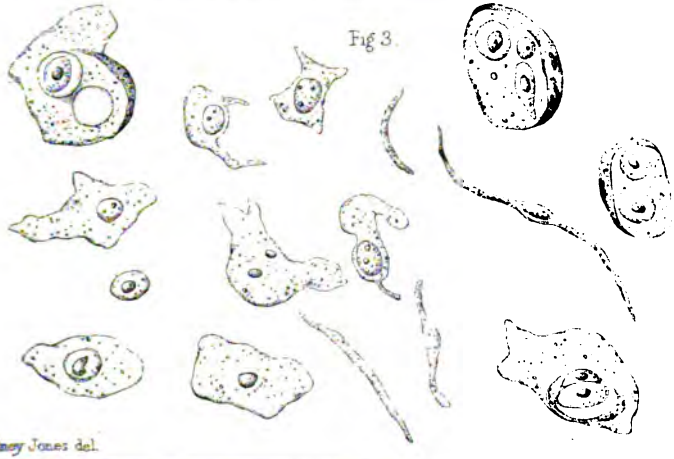

Dr Sydney Jones del.

Tuffen West sculp

W West imp

in the matrix were (Plate VIII. Fig. 2) of two kinds:—one more or less spherical, the other more or less cylindrical. In size, the spherical cells varied from $\frac{1}{2000}$ to $\frac{1}{800}$ of an inch in diameter. The smaller cells had no nuclei, and no distinct cell walls. Some of the larger cells were filled with fat granules, and represented granule cells; others had a single or double vesicular nucleus; a few were acuminated at two opposite points, and somewhat compressed. All the other cells possessed demonstrable cell walls. The cylindrical cells resembled in their general characters those which normally coat the mucous membrane of the larger gut, but they were much more elongated, compressed, and firmly matted together. Many of the more elongated cells were constricted in the middle, and exhibited a nucleus on each side of the constriction.

In some parts of the matrix, the cells lay without obvious order; in other parts, and always around the openings already noticed, they were arranged in layers,—the more or less spherical cells occupying the attached, and the cylindrical cells the free surface of the membranous tube. At several points the cylindrical cells were absent, and there the surface layer was formed by granule cells. Generally the membranous tube consisted of a single layer of matrix with cells; but at some parts it consisted of several layers of matrix with cells. In such cases, the superficial layers were more opaque, drier, less elastic, and friable, and between each layer were found the harder portions of undigested food, husks of seeds, gritty tissue, and masses of elastic fibres.

The elastic fibres deserve separate notice, from the fact that each fibre exhibited very distinct and regular transverse striation, approaching in character to that found in the ligamentum nuchæ of the giraffe. They shall be elsewhere fully described.

The perforations in the matrix were of uniform size and appearance, surrounded by elevated margins formed of closely grouped cylindrical cells, and led to two kinds of pits—one short and flask-shaped, the other long and uniformly cylindrical.

The flask-shaped pits were about one-sixth of an inch in diameter, and distinctly hollow. The wall of each pit was made up of one or two layers of sub-spheröidal cells, held together by

an amorphous stroma. A few of these follicles contained a deposit which was opaque *in situ*, and which, when broken up, was found to consist of large flattened nucleated cells, analogous to those met with in epithelial growths.

The cylindrical pits were also for the most part hollow, about one-sixteenth of a line in length, and one-thirty-fifth of a line in breadth. Their walls, devoid of membrane, were composed of small, more or less spherical cells in various stages of development, embedded in a gelatinous matrix.

We conclude from these details, that the specimens exhibited were true casts of the large intestine produced by chronic inflammatory action of the mucous membrane and subsequent exudation.

Dr. WILKS and Dr. ANDREW CLARK.

Supplementary Notes by Dr. ANDREW CLARK.—As I have chemically and microscopically examined and preserved numerous specimens similar to those reported upon above, and as the facts elicited appear to have an important bearing upon the prevailing pathological doctrines of the schools, I venture to subjoin a few additional notes. The orthodox interpretation of these casts would be as follows:—

1. The casts are perfect illustrations of croupous fibrin.
2. This croupous fibrin has been produced by inflammatory exudation.
3. The abnormal cells present in the casts, are the products of free cell development in the inflammatory exudati o

The facts elicited by a careful investigation of the above casts, and of similar products of morbid action, compel me to take exception to each point of this interpretation.

1. There is a structural and chemical objection to the allegation, that these casts are fibrinous, or that they even contain fibrin.

a. These casts when unaffected by re-agents, contain no molecular or homogeneous filaments; yet these are the structural modes in which fibrin is manifested in exudations. This is proveable partly by experiment, partly by the fact, that exudations on mucous membranes which chemically yield fibrin, structurally yield it in these modes at the same time,

and partly by the absence of the faintest proof that fibrin is amorphous under similar conditions.

b. The casts yielded no chemical evidence of the presence of fibrin at all. The matrix was fibrillated by acetic acid. Careful washing and compression, yielded a fluid abundantly coagulable by heat and nitric acid. Prolonged digestion of the casts at an elevated temperature in a solution of nitre produced no fluid abundantly coagulable or precipable by acetic acid.

2. By inflammation, I mean a capillary blood stasis, which has proceeded to exudation. It is the characteristic of this exudation that it contains fibrin.

The casts above described contain no fibrin.

3. It will be alleged, that the abnormal cell-forms present in these casts, are the products of free cell development in an exuded blastema.

I have observed in my studies, that this product of diseased action in mucous membranes occur in three varieties.

The first is clear, jelly-like, and imperfectly membranous. The second is yellowish, semi-opaque, flaky, and usually membranous. The third is yellowish-white, dense, opaque, distinctly membranous, tough, and rather firmly adherent to the subjacent surface. The first contains only the merest trace of albumen, and no fibrin. The second contains an abundance of albumen, and no fibrin. The third contains both albumen and fibrin in abundance, the latter in a fibrillated form.

Differing in most respects, these three varieties of morbid product agree in this, that they all contain similar cell-forms (as was observed in the microscopic specimens exhibited). Yet it is to be noticed that in the first variety there is no evidence of transudation or exudation; in the second, no evidence of a true exudation; and that in the third, in which the existence of a true inflammatory exudation is undeniable, the only additional structural element present is fibre.

I consider that I am justified by these facts, in saying, that the casts exhibited are not fibrinous; that they are not the products of inflammation in the sense defined, and that the abnormal cell-forms present have arisen in some other way (*i.e.* metamorphosis), than by free cell development out of an exuded blastema.

I further consider that these facts are sufficient to show that we have, as yet, received no true generalization of the origin of morbid products; that the prevailing doctrine upon this point is at variance with fact, and violates those physical and chemical conditions which concur in the evolution of morbid products; that much truth is constantly being missed, in the endeavour to reconcile all special illustrations of diseased products with the current dogmas of exudation and crases; and that a simultaneous chemical and microscopic examination of a few defined products upon a definite plan, would prove of greater value to science than numerous observations, made only with the microscope, conducted upon no fixed plan, and for no fixed purpose.

Dr. Andrew Clark, *3rd of November*, 1857.

---

2 *Epithelial Cancer of the Œsophagus, causing Death by Hæmorrhage from the Right Sub-clavian Artery.*

The patient was a well-formed muscular man, æt. 65, who had suffered from dysphagia for six months, and had been quite unable to swallow solid food for six weeks previous to his death. During the last month of his existence, he had great difficulty in swallowing even small quantities of liquid.

A careful examination of the neck and chest was made five weeks before death; no signs of any local affection could be detected externally in the neck, and the sounds of the heart and lungs were perfectly healthy in every point.

It may be observed, that no bougie was passed into the œsophagus, with a view of relieving the dysphagia, as after the examination before-mentioned, the general impression was, that it was a case of cancer of that organ.

When in a very emaciated state, the patient was seized with hæmorrhage, and threw up by the mouth, in the course of a quarter of an hour, about three pints of florid blood. After this, the hæmorrhage almost ceased for the space of twenty hours, when a second attack came on, and ended fatally in the course of a few minutes.

Post-mortem examination.—When the finger was passed into the œsophagus, a constriction was felt about one inch and a half

from its upper extremity. This was of just sufficient size to admit the tip of the little finger. Upon laying open the œsophagus, an ulcer was found one inch and a half in extent vertically, and extending all round the tube; the margins were very irregular, in some parts elevated and indurated; the base of the ulcer was, for the most part, covered with superficial sloughs, and, at or near its centre, on the right side of the tube, was an opening through the walls, large enough to admit the passage of the first joint of the little finger, which led to a cavity about the size of a walnut, which lay between the œsophagus and innominate artery. On opening the aorta, some scattered patches of atheroma was seen, but these were not more than are usually observed at this period of life. The branches of the aorta appeared healthy. In the sub-clavian, on the right side, about one inch and a half from its origin was an opening somewhat circular, about one-third of an inch in diameter, communicating with the cavity before-mentioned, and through it with the œsophagus. No secondary cancer was found.

Upon making a section of the indurated edge of the ulcer, the thickened portion was found of a dirty-white colour, the tissue being very tough and firm, and when scraped with a knife, juice could be collected in considerable quantity.

On examination with the microscope a large number of epithelial cancer cells, most of them having one, but some two or three nuclei of an oval form, and also nucleoli, were seen; there were besides these, numerous laminated capsules and brood-cells, some of large size, which contained a number of small cells.

Some portions of tissue, at a depth of from one-eighth of an inch to one-sixth of an inch beneath the surface were found on examination by the microscope, to be made up of the cells above-described.

The parts affected were subsequently examined by Mr. Queckett, Mr. De Morgan, Dr. Goodfellow, Mr. Sibley, and Mr. Flower, who all declared the ulcer to be of a cancerous nature.

Dr. B. Balding, *20th of October*, 1857.

Report on the above specimen.—The ulcerated surface is about two inches from the top of the œsophagus, and involves the

whole circumference of the tube, for about an inch of its length. In the midst of this superficial ulceration is an opening, about three-fourths of an inch long, and one-fourth broad, which communicates with a cavity occupying the right side of the trachea, and passing behind the innominate artery opens into the right sub-clavian artery, by a sloughy aperture, which engages half the circumference of this vessel.

The surface of the cavity is void of all adventitious deposit throughout nearly all its extent, being bounded by sloughy areolar tissue. Near the œsophagus, it is thickened and circumscribed by an infiltration of ordinary inflammatory exudation.

The base of a considerable portion of the ulcer is occupied by cell growth. The cells have the size and shape of the squames of healthy œsophageal epithelium; but they are of darker colour, and of more distinct contour, and some of them offer, besides the usual appearances of fission of nuclei, aggregations of their contained mass not very unlike a further process of this kind. Nowhere, however, do these cells extend to any considerable depth below the surface; and even where most distinct, they are often placed immediately upon healthy sub-mucous areolar tissue. We are aware that such a cell-growth is scarcely incompatible with the notion of an epithelial cancer, reduced by softening or sloughing to a flattened and perforated form, so as to give rise to a sloughy abscess, external to the œsophagus. But this view seems open to considerable doubt; if, indeed, the balance of probabilities is not on the other side. The cavity contains no trace of malignant growth; and, to the naked eye, both it and the ulcer have all the characters of ordinary ulcerative lesion. The ulcer is devoid of all marked swelling or thickening (much more of all fungation or outgrowth); its base shews no fusion with the subjacent tissues; its cell-growth merges into that of the neighbouring unaffected mucous membrane. These circumstances, and the absence of all secondary deposit of cancer in other organs, render it *probable* that the moderate overgrowth of epithelium, found on the floor of the ulcer, represents a mere hypertrophy of the œsophageal mucous membrane, in the neighbourhood of an ordinary ulcer: a process of which a variety of acute and chronic inflammatory

states—especially in the skin—afford numerous and equally marked examples. Drs. WILKS and BRINTON, *7th of January*, 1858.

Several members of the Society had also examined the specimen, and agreed with the above report, but as some dissented from it, it was determined that another report should be made and submitted to the Society, which was as follows:—

Second Report on the above specimen.—Independently of each other, and at different times, we examined the tissues forming the base and edges of the ulcer, as well superficial as deep-seated.

In several parts of the ulcer, the tissue presented no abnormal structures save the ordinary products of inflammation. In other portions, however, the tissue was largely intermingled with other more important structures. In fact, the tissue seemed to consist, almost entirely, of epithelial cells, presently to be described, infiltrated and scattered amongst the connective and other tissues of the part, and these cells were not only found on the surface of the ulcer, but penetrated more or less deeply the subjacent tissue, in some parts to a considerable depth.

The epithelial cells, which were found in these situations, were generally large, irregular, and flat, and contained a single distinct nucleus. Mingled with these in considerable numbers, were brood-cells and laminated capsules.

Having discovered these important pathological elements in the situations above-described, and from the general characters of the ulcer, we have no hesitation whatever in expressing our belief that the case was one of epithelial cancer. The fact that cancerous structures existed in some parts, while they were absent from other portions of the base of the ulcer, tends, in our opinion, in no way to invalidate our conclusion, and is only another illustration of what is frequently observed in the course of cancer in other organs, especially in that of the uterus.

Dr. GOODFELLOW and Mr. SIBLEY, *1st of December*, 1857.

---

3. *Perforating Ulcer of the Duodenum.*

A man, æt. 37, well-built, and rather stout, was brought to King's College Hospital, shortly after midnight, on the morning

of the 19th of August, 1857. The following history was given of him:—He had for many years been a potman in a public-house, and had always enjoyed excellent health. His appetite had always been good, and he had never been subject to sickness, nor suffered from pain after meals. He had been in the habit, however, of drinking a good deal of spirituous liquors. On the evening of the 17th of August, his bowels being confined, he took a dose of castor oil. This had no effect, and on the following morning after eating a little new bread, he was sick and vomited, and immediately after complained of pain at the pit of the stomach. During the day, his abdomen became blown up, with great prostration of the general strength; but there was no return of the vomiting, and but little complaint of pain. On admission, he was in a state of collapse, but perfectly conscious. Pulse very rapid, but almost imperceptible. Lower limbs drawn up. Abdomen much distended, tympanitic, and somewhat tender, but not excessively so. No pain complained of, and no vomiting. He gradually sank, and died about three hours after admission, remaining conscious till within two or three minutes of death.

Post-mortem examination twelve hours after death.—Considerable rigidity existed. A large quantity of sub-cutaneous fat, forming a layer more than an inch thick over the abdomen. On opening the abdomen, a quantity of fœtid air escaped from the peritoneal cavity. Peritoneum and intestines much congested, and coated with large, loosely-adherent flakes of recent lymph. Several pints of dirty brown fluid, of the consistence of gruel, with floating drops of (castor?) oil, in the peritoneal cavity, evidently the contents of some part of the bowel. This fluid was most abundant on the right side, and on careful examination, was found to flow out from an ulcerated opening in the anterior surface of the duodenum. In the neighbourhood of this ulcer, there were extensive, firm adhesions of the bowel to the liver and surrounding parts.

The stomach and duodenum were now carefully removed. Mucous membrane of stomach perfectly normal, with no trace of ulceration. The ulcer above alluded to was situated at the very commencement of the duodenum, immediately beyond the pylorus. Looking at it from the mucous surface, it presented a triangular

outline, with sides varying from one half to one third of an inch. This triangular ulcer completely perforated the mucous and muscular coats, and its floor was formed by peritoneum, in the centre of which there was a circular perforation three lines in diameter. There was slight thickening of the mucous membrane round the ulcer, with a few small, superficial ulcers in the first part of the duodenum. Below this, the gut was healthy.

Liver small, and in an advanced stage of cirrhosis. Some old adhesions in pleuræ. Other organs healthy.

Remarks.—The remarkable feature of this case was, the total want of symptoms to warn the patient of his danger previous to the occurrence of the fatal peritonitis. It may even be a question, if the perforation did not exist for some little time previous to the symptoms of peritonitis, the contents of the bowel being prevented from escaping into the peritoneum by the surrounding adhesions, some of which, however, were ruptured by the act of vomiting, after eating the new bread on the morning of the 18th. Several cases have already been recorded of fatal peritonitis, resulting from perforating ulcer of the duodenum, but preceded by no marked symptoms. Some of these have been alluded to by Dr. G. Budd, in his work on "Diseases of the Stomach," pp. 149, 150. In the Museum of St. Mary's Hospital, also (Prepn. C., c. 1), is a preparation illustrative of the same fact, which was obtained from the body of an Oxford Professor, who dropped down dead while walking in the streets of London. Perforating ulcer of the duodenum must, therefore, be regarded as one of the causes of "sudden death."

Dr. Murchison, 20*th of October*, 1857.

---

4. *Perforating Ulcer of the large Intestine in Typhöid Fever.*

A man, æt. 30, who was already convalescent from an attack of typhöid fever was gradually affected by extreme tympanitis, without either pain or tenderness in the belly. With no effect on the alvine evacuations, this tympanitis remained from about the end of the fourth week to the middle of the sixth week, attended for about the last three or four days with pain and

tenderness in the left iliac fossa, and failure of the circulation, ending in death.

The diagnosis arrived at during life—peritonitis produced by ulceration of the solitary follicles of the sigmöid flexure—was confirmed by the *post-mortem examination*, which shewed a little fluid, and a few shreds of lymph, in the peritoneal cavity, adjoining an ulceration which had almost penetrated the lower part of the sigmöid flexure. The Peyerian patches of the small intestine were enlarged and blackened; and some of the solitary follicles in this segment of the bowel were ulcerated. The large intestine was studded with similar ulcerations in much greater number.

Dr. W. Brinton, *17th of November*, 1857.

---

5. *Cancerous Infiltration of a Chronic Gastric Ulcer.*

A married woman, mother of several children, who was of spare frame and of temperate habits, but had frequently suffered from indigestion, pain, sickness, and headach for twenty years, began to suffer at the age of 41, from severe pain in the epigastric and inter-scapular regions, with rising of the food after meals. One year after, her menses ceased rather suddenly, without any influence on these symptoms.

In April, 1857, I found, on her consulting me, that the pain in the epigastrium was accompanied by excessive tenderness, and by a pricking or burning sensation of a peculiarly superficial character. There was no trace of hardness or tumour in the epigastrium, and no present or previous hæmatemesis.

Regarding the case as gastric ulcer, which had probably perforated the stomach, and was limited only by circumjacent lymph, I treated it in the usual way. The pain altogether ceased, as did in great extent the vomiting; and she thought herself gaining flesh and strength.

In August she returned to town, after a few weeks absence. Some errors of diet had, she thought, brought back the vomiting, with excessive frequency. She was emaciated, but not cachectic in appearance, and extremely feeble. The left half of the epigastrium was occupied (as her medical attendant, Mr. Merriman, of Knutsford, had discovered) by a tumour. On careful examina-

tion, this tumour evidently contained air, and therefore was probably the thickened stomach; whether it involved the cardiac sac it was impossible to state, but it evidently affected all the middle of the organ. The pain and soreness were still absent. The matters vomited consisted of thick glairy mucus.

Admitted an in-patient of the Royal Free Hospital, she was relieved, and even much improved, for a time, by the diet and remedies prescribed. The supposed gastric tumour, however, gradually disappeared, apparently from its receding into the epigastrium, and thus becoming covered by the (comparatively thinned and narrowed) small intestine. Without any appearance of jaundice or cancerous cachexia, or any symptom of cancerous deposit in any other organ, she gradually sank from exhaustion, and died, much emaciated, after a day or two's return of pain in the epigastrium.

The history of the case left little doubt, that the post-mortem examination would reveal ulceration, adhesion, and contraction, of at least the middle third of the stomach. But whether this ulceration was cancerous or no, it seemed impossible to decide during life. On the whole, as the external signs of thickening did not exceed those sometimes verifiable in chronic ulcer, I thought the absence of cachexia, of secondary deposit, of grumous vomiting, and of cancer in her family history, together rendered cancer the less likely explanation of the two. In short, the case seemed probably an adherent and contracted ulcer.

The *post-mortem examination* shewed precisely the amount and situation of ulceration, adhesion, and contraction, predicted during life. A large ulcer occupied the middle third of the sound organ, leaving the cardiac sac healthy, and a smaller portion of pylorus. This ulcer contracted the middle of the stomach, so as to reduce its cavity to a tube that would barely admit the thumb. Above, it adhered to (and eroded) the liver, as well as to a small extent of abdominal wall anterior to this organ.

But the floor and especially the margin, of this ulcer exhibited a deposit of about a quarter of an inch to half an inch in thickness, evidently cancerous; a view abundantly confirmed by the microscope, which shewed it to consist of vast numbers of cells, with

less numerous intervening fibres. No secondary deposit could be found in any other part of the body.

It seems to me that there can be little doubt this was one of these instances—one or two of which may be seen in the Pathological Museums of this metropolis—in which a gastric ulcer has undergone a cancerous infiltration or deposit. I base this opinion chiefly on the concurrent probability afforded by the following circumstances; the long duration of the malady; the absence of all trace of cachexia (as distinguished from mere emaciation), as well as of secondary deposit; the healthiness of the gastric tissues around, and, in some places even beneath, the diseased mass; the exact coincidence of extent in the deposit and the ulceration, etc. And I think the accuracy with which the appearance of the tumour, and subsequently its disappearance, are fixed by its clinical history, justify the conjecture, that the cancerous deposit occurred with comparative rapidity, at a date of about three months before death, and began to contract the affected segment of the organ, very soon after its being thus deposited. Dr. W. Brinton, 17*th of November*, 1857.

---

6. *Epithelial Cancer of the Œsophagus, causing Death by Opening an Intercostal Artery.*

Taken from a man, æt. 51, who had suffered from dysphagia for several months. The œsophagus had been completely destroyed to the extent of three or four inches, by epithelial cancer. In front, a communication existed with the trachea, readily admitting the passage of the forefinger, and situated just above the bifurcation of the bronchi; behind, the cancerous deposit extended backwards to the spine, involving the anterior common ligament, but not extending so deeply as to involve the bone.

On the left side, the deposit had reached the descending aorta, and had involved, more or less deeply, the external coat.

The first intercostal artery of the right side was opened close to its origin, and two more intercostals from the same side might be traced through the mass, blocked up, however, after a short course, with cancerous deposit. The stomach and intestines were filled with blood.

A point of interest connected with this case was, the small amount of cancerous deposit found on examination with the microscope (Plate VIII, Fig. 3), the rapidity of destruction keeping pace with the rapidity of growth.

Dr. Sydney Jones, *15th of December*, 1857.

---

7. *Gangrene and Perforation of the Ileum, with Peritonitis, caused by a large Biliary Calculus.*

Miss F., æt. 68, very fat and sedentary, during the last few years suffered occasionally from pain near the seat of the gall-bladder. On one or two occasions the eyes were jaundiced. Some six weeks ago she was seized with very severe pain in the region of the cæcum, and with vomiting; the abdomen was much distended with gas, and very little fæculent matter passed by the bowels. Enemata of warm water were administered daily, and gentle purgatives were exhibited. Leeches and fomentations were employed. The patient was relieved, but the abdomen continued somewhat distended and uneasy, and very little fæculent matter passed by stool. Similar attacks continued to recur, and latterly they were combined with considerable collapse, the pulse becoming weak and intermittent. The rejected contents of the stomach resembled beef-tea; a brownish deposit was composed of altered blood corpuscles. The last attack occurred on the last day of the year; she complained of intense pain in the right iliac region, and for the first time in the hypogastric region, and of being very cold; the face and hands were chilly, and the pulse rapid and very small. Death occurred next morning at six o'clock.

Post-mortem examination.—Under the abdominal integument, a layer of fat was found about one inch in thickness, and some offensive gas escaped from the cavity of the peritoneum. The omentum was very fat, and nearly one inch thick. Slight, recent attachments between the omentum and peritoneum, covering anterior wall of abdomen. Peritoneum much inflamed over cæcum, and red patches of arborescent veins existed. The same appearance at the hypogastrium. The omentum presented a reddish tint, from numerous minute injected vessels. A white oblong spot, one inch in length, was seen on the peritoneum, covering the anterior wall of

the abdomen at left hypochondrium, old, smooth, and resembling a coat of white oil paint. Some six ounces of dirty opaque serous fluid, containing small shreds of coagulated lymph, were found in the abdomen.

Stomach natural; duodenum darker than usual, attached by adhesions to commencement of transverse colon; ductus choledochus normal; jejunum and ileum greatly distended, with very offensive gas, of dark-reddish colour, from numerous injected vessels; slight attachments between coils of small intestines. One portion of ileum near termination of jejunum, in length about two inches, and in hypogastric region, was of a dark slate colour, a portion, about one inch square, was soft, and broke down under the fingers, and an aperture was found, through which a goose-quill might pass. The mucous membrane at this spot was black and gangrenous. Further on, and lying below the cæcum, another portion of the ileum was found, of a slate or dark colour, and completely filled with a hard globular body. This body was firmly impacted in the bowel. On cutting open the intestine, a large biliary calculus, the size of a chestnut, was found. The interior of the bowels was blackish, and presented several dark round spots. Superficial ulcerated patches were likewise seen. This portion of the ileum, between the calculus and the cæcum, now suddenly narrowed. The cæcum was rather small, the transverse colon, the descending colon, and rectum were very considerably contracted. The mucous membrane of the cæcum was softened, but not unduly vascular or ulcerated. The liver was below the average size, of soft, flabby consistence, and of a somewhat leaden colour, probably from exposure to gas in peritoneal cavity. The gall-bladder, slightly adherent to neighbouring parts, contained no fluid bile, but a calculus, the size of a horse-bean, was found embedded in the fundus. The cystic duct was pervious, the calculus found in ileum rudely globular, presenting some smooth polished faces, where it had come in contact with another calculus. The circumference was three inches, the weight two drachms three grains, it sinks in water, looks rather worn or dissolved in some parts. Sulphuric æther dissolved it, and exhibited crystals of cholestearine. At one part, the colour of the calculus was-coal black, but this colour was only superficial.

The calculus taken from the gall-bladder was light brown, smooth, weighed one drachm, and was soluble in sulphuric æther.

The other abdominal organs were healthy.

The patient was attended by Mr. Spurrel of Bexley Heath, Mr. Sweet of Stockwell, and latterly by Dr. Scott Alison. All these gentlemen were present at the post-mortem examination.

Dr. Scott Alison, *5th of January*, 1858.

---

8. *Malformation of the Rectum.*

A child was brought to me to-day, at the Hertford Infirmary, which the nurse informed me had not passed anything from its bowels since its birth. It was five days old, had had as much as nine drachms of castor oil, and a piece of tallow had been inserted into the rectum, but all of no avail. It was a male child, and its mother a poor woman in the town.

On examining it, I found an external opening at the natural situation of the anus, into which I could pass my little finger for about an inch, and then came to a firm obstruction, as if the sides of the bowel were glued together. By a little forced manipulation, this gave way, and I passed my finger through it, and it felt as if encircled by a ring stricture. I thought I had got into the continuation of the bowel, but my finger was not stained with meconium, and an injection of warm water returned as speedily as it was injected; a little blood followed the breaking down of the obstruction. The child died next morning.

Post-mortem examination six days after birth.—The body was well-formed and in a good state of nutrition. The colon was distended, and the extremity or rectum filled with meconium. It terminated in a closed extremity, in the hollow of the sacrum, and lay to the side of the passage communicating with the external opening. The duodenum was contracted to the size of a large quill. The mother states that she lost a child in the same way, and at the same age, at the Cape of Good Hope.

Dr. Beale for Dr. Elin, *19th of January*, 1858.

---

9. *A Fibrinous Cast of the Pharynx, ejected by a Patient suffering from Diphtherite.*

The patient, a girl, æt. 11, was attacked on the 22nd of December, 1857, with rigors, headach, and sore-throat. On the 13th, difficulty of swallowing ensued, and ordinary domestic remedies for sore-throat were employed. On the following day the child was much worse, and was placed under the care of Mr. Maclean, of Taunton Place, to whom I am indebted for the notes of the case. The skin was then excessively hot and dry, and covered with a rash resembling scarlatina; the countenance was very anxious, the dyspnœa excessive and aggravated by paroxysms of a suffocative nature. She could hardly articulate, and had great difficulty in swallowing the smallest quantity even of fluids. The pulse could not be counted, and palpitation was so violent that she pressed her chest with both her hands as if with the view of relieving it. The tongue was furred and white, the mouth apthous, and the tonsils, posterior fauces, and throat, were covered with a thick, cream-coloured exudation, which extended down the pharynx as far as could be seen. The local treatment employed consisted of sinapisms, followed by linseed poultices to the throat externally, and the application of solid nitrate of silver to the throat internally, followed by a strong alum gargle, the general treatment of calomel, and James's powder every four hours, with saline medicine containing tincture of digitalis. Nothing, however, afforded the slightest relief; she was delirious during the night and on the following day (the 15th), was absolutely struggling for breath. During a violent paroxysm of suffocative dyspnœa, which at every instant seemed as if it would prove fatal, she ejected the false membrane laid before the Society. The breathing instantly became tranquil, the fever subsided, the scarlet rash disappeared, and the heart's action became regular and quiet. This complete change took place within a few hours, so that by the evening of the same day (15th) she was comparatively comfortable. On the 16th, nothing remained of her former illness but some apthous ulceration of the mouth and fauces, and within four days, she was up and dressed and thoroughly convalescent, though requiring tonics. The false

membrane when ejected, was above four inches in length, exceedingly tough, of a cylindrical form, and presented a complete cast of the pharynx. The microscope shewed it to be a fibrinous exudation. Dr. FULLER, *2nd of February*, 1858.

---

10. *Collöid Cancer of the Peritoneum, involving the Great Omentum, the Ovaries and the surface of the Liver and Gall-bladder.*

These specimens of collöid growth of the peritoneum, occurred in a woman, æt. 64. Her general health was good until five months before death, when she first began to suffer pain in the abdomen, attended with slight swelling, both of which symptoms gradually increased. In the course of three months the abdomen became much enlarged in all its dimensions, but no fluctuation could be detected; hepatic dulness was increased in every direction, but there was no jaundice, and no œdema of the legs. Subsequently, the pains increased very much, and during the last three weeks before death it was constant, and so severe that she could not bear examination. She lost flesh and strength very rapidly, but had no head symptoms.

Post-mortem examination.—The body was thin, the abdomen was distended and dull on percussion. Before opening the abdomen, a tumour, about the size and shape of a liver, was felt occupying the umbilical region, and another tumour, about the size of a child's head, was felt in the hypogastric region. On opening the abdomen about a pint of brownish serous fluid escaped, and about three pints in all were contained in the abdominal cavity. The liver was hid beneath the right false ribs, the anterior extremity of the left lobe only was seen in the epigastric region, just below the xiphöid cartilage. The abdominal cavity appeared filled with a large growth, extending from side to side, and reaching from the false ribs to the hypogastric region. This growth was found to involve the *great omentum*, and was slightly adherent to some of the viscera, and to the abdominal parietes. On lifting it up, it was found to be quite liver-shaped, the inferior margin was thin and free, but somewhat irregular, the upper border was thick and adherent to the greater curvature of the stomach. The anterior surface was convex,

tolerably even, but uniformly nodulated; the posterior surface was irregular, presenting large and small nodules and projections. The transverse colon crossed the middle of the posterior surface, about the half of its circumference being firmly fixed in the substance of the growth; the pancreas adhered to the growth, but was not diseased, otherwise than being very soft, and was easily dissected away.

A tumour, *involving the left ovary*, was situated in the hypogastric region and partly in the cavity of the pelvis. It was about the size of a child's head, nodulated, elastic, moveable, covered with peritoneum, and connected with the uterus, by a fibrous pedicle about an inch long. On section, this tumour presented a yellowish, transparent, gum-like appearance, and fibrous bands were seen passing in different directions; some parts were uniformly firm, but there existed numerous alveoli, varying in size from a pin's head to a walnut, and these were filled with a glairy jelly, which could easily be squeezed out. No portion of the left ovary could be distinguished; the *right ovary* was adherent to the side of the uterus, and was involved in a growth, about the size of an orange, which, on section, exhibited several cavities filled with very soft glairy jelly. The uterus was not increased in size, but its surface was covered with several collöid nodules, which, however, did not extend into its substance.

The *surface of the liver and gall-bladder* was covered with small collöid growths, varying in size from a quarter to half an inch in diameter; the suspensory and coronary ligaments of the liver were much thickened by the collöid deposit; and in the longitudinal and transverse fissures the collöid substance was nearly an inch thick. The liver weighed forty ounces, its tissue seemed tolerably healthy; the growths only indented the surface without involving the tissue, but the subjacent capsule was generally thickened. The gall-bladder contained about half an ounce of thick viscid bile, and about forty calculi, of which four were about the size of beans, the remainder smaller than peas, very angular, but uniformly smooth, yellow, shining, and rather soft. The lining membrane of the gall-bladder was healthy; the collöid disease did not extend beyond its peritoneal coat. The spleen weighed three ounces and a half and its capsule was thickened and covered

with numerous collöid nodules. The mesentery was covered with masses varying in size from a pea to a walnut; the small intestines also were covered with the growth, especially along their attachment to the mesentery. The inferior surface of the diaphragm was covered with patches of collöid substance about three or four inches in diameter, and about half an inch thick.

Microscopic examination.—A thin section taken from a collöid mass, situated in the transverse fissure of the liver, exhibited a fibrous mesh-work, the loculi being filled with large granular-looking bodies, some of which presented indistinct concentric markings. A few granular nuclei, about the size of pus-corpuscles were seen at the margin of the section. Acetic acid developed elongated nuclei in the fibrous stroma. Sections taken from the tumour of the ovary, and from other parts, exhibited nearly the same appearance.

Dr. Van der Byl, *2nd of February*, 1858.

---

11. *Intestine, presenting old and recent disease, from a patient who died of Typhöid Fever during relapse.*

A female, æt. 19, a servant, residing in Camden-town, was admitted into St. Thomas's Hospital, under the care of Dr. Peacock, on the 30th of November, 1857. She presented characteristic symptoms of typhöid fever; there was tremor of the extremities, and delirium; the tongue was dry and brown; there were sordes on the teeth; the pulse was quick, and there were elevated, rose-coloured spots, which faded on pressure, on the abdomen and back. The bowels were relaxed and she was much prostrated. Her illness, she stated, had commenced three weeks before, with cough, pains in the limbs, and general febrile symptoms, but, from the impairment of her intelligence, this report could not be depended upon.

On the 9th of December, the bowels became very much relaxed and there was blood in the stools, and this continued for three days. On the 12th, she began to improve, and on the sixteenth or seventeenth day from admission, and the thirty-eighth from reported seizure, she was convalescent—the pulse had fallen to 92, she was quite intelligent, the bowels were acting regularly, she took her food

well, and had gained strength. She continued steadily to improve till the 23rd, when, without any assignable cause, she was taken worse. The torpor of mind, tremor of the extremities and delirium recurred. The tongue again became dry and brown, and sordes formed upon the teeth; the pulse was quick, 116, and weak, and she had vomiting and profuse diarrhœa. On the 29th, she had rallied in some degree, but, in the evening of that day, she again passed a large quantity of blood from the bowels, sank into collapse, and died the following morning. There was no fresh eruption on the skin during the relapse. Death took place on the thirty-first day from the admission of the patient, the fifty-second from the reported seizure, and the eighth from the period of relapse.

The *post-mortem examination* was performed by Dr. Bristowe, and the viscera of the head and chest were found healthy. The spleen was rather large, dark coloured, and somewhat pulpy; the liver pale; the pancreas, supra-renal capsules, kidneys, uterus and ovaries were all healthy. The stomach and upper part of the small intestines were also healthy.

Numerous ulcers, with partly detached yellow sloughs, were found in the last four-fifths of the ileum, and immediately above the ileo-cæcal valve were several large patches, from which the sloughs had entirely separated, and on which the ulcerated surface and the edges were smooth, unthickened and appeared partially cicatrized. Throughout the cæcum and ascending and transverse colon, there were also many ulcers. Some of these were oval or circular, slate-coloured, depressed patches, without distinct margins, though occasionally presenting, near the centre, small oval, shallow pits, and around the margins indistinct indurated puckerings. These were ulcers, manifestly more or less perfectly cicatrized. In addition, however, there were numerous ulcers with tumid edges, to which the yellow sloughs were still adherent, or from which they were only partially separated, and these are evidently of quite recent formation. The recent were intermixed with the other cicatrizing ulcers in the same portions of intestine. They were more numerous in the cæcum than elsewhere. Some of the mesenteric glands were large, soft and vascular.

In reference to this case, Dr. Peacock stated, that he believed it to be very rare, that typhöid fever proves fatal during

relapse, unless when the fresh accession of fever is connected with some internal inflammation. At least, while he had frequently known patients labouring under typhöid fever have relapses when convalescence was considerably advanced; he had never known such cases to prove fatal, unless from the occurrence of pneumonia, pleuritis, arachnitis, etc. In this instance, there was a distinct return of fever, and evidences were found after death that, while the intestinal disease connected with the first attack was advancing towards complete cure, more recent disease had again occurred in the same portions of intestine. On consulting the works of the chief authorities on the morbid anatomy of typhöid fever, Louis, Chomel, Andral, etc., he did not find any similar case recorded. Dr. PEACOCK, *2nd of February*, 1858.

---

12. *Cancer of the Stomach and Œsophagus.*

This specimen was removed from a subject of upwards of 80 years of age, in the dissecting room of the Westminster Hospital. The previous history of the case is necessarily very meagre, the only point ascertained, being that vomiting of very offensive matter, had existed for some weeks previous to death. On opening the abdomen, a tumour of about the size of a large chestnut was found attached to the lesser curvature of the stomach, near the œsophagus, but not involving it. On section, it presented the appearance of malignant disease, and this was confirmed by microscopic examination. The tumour appeared to have been developed in the walls of the the viscus, but did not involve its mucous coat. On the thorax being opened at a later period of the dissection there was found a malignant ulcer in the œsophagus, about an inch above the diaphragm, measuring three inches in the vertical, by two in the opposite direction. The tissues immediately surrounding it were considerably indurated, and it had produced such a narrowing of the canal, that a large quantity of food was found contained in the ulcer. Microscopic examination revealed the same characters of malignancy as in the tumour.

A careful dissection failed to discover any trace of disease in the other organs.

Mr. CHRISTOPHER HEATH, *16th of February*, 1858.

13. *Cancer of the Liver and Cardiac Extremity of the Stomach, with perforation.*

The patient from whom this specimen was removed, was a man æt. 63, under Dr. Radcliffe's care, in the Westminster Hospital, but as he was in a very feeble condition and died three days after admission the notes of his case are necessarily scanty. He was admitted on the 9th of February, 1858, suffering from great debility, which was his chief complaint; he had also a slight cough, and some pain in the epigastrium, the abdomen was distended, and the bowels flatulent. He was a gardener by trade, and had been ailing for six months with apparently dyspeptic symptoms, and gradually became so emaciated and weak as to cease work. He had never had any vomiting, nor did that symptom occur during his stay in the Hospital. He never rallied at all after admission, but gradually sank and died on the 12th of February.

Post-mortem examination.—The abdomen was found filled with fluid containing flakes of lymph in great abundance. On the lesser curvature of the stomach, close to the œsophagus, was a mass of encephalöid cancer as large as the fist, in the centre of which was a sloughy spot, through which perforation of the viscus had taken place. On opening the stomach, a large malignant ulcer, was found in a corresponding part of the interior. There was no disease of the œsophagus nor in the other intestines. The liver was most extensively diseased, the left lobe being almost entirely converted into encephalöid cancer, and a large mass of the same disease being present in the right lobe.

It is remarkable, that there were no symptoms referable to cancer of the stomach during the patient's short stay in the Hospital, and the evidences of peritonitis were so slight that there was no suspicion of perforation during life.

Mr. Christopher Heath, 16*th of February*, 1858.

---

14. *Pedunculated Polypus from the Rectum.*

A male child, æt. 3, who had never suffered from prolapsus ani, or other symptoms connected with the bowel, was observed, two months ago, to be affected with a bleeding from the anus to a

slight extent. On examination, a tumour was seen projecting from the anus attached by a long pedicle to the gut. A surgeon was sent for, and examined the child, but the tumour had passed entirely out of reach, and could not be felt.

The child continued to pass a little blood at intervals, but the tumour did not again make its appearance. An aloetic purge was therefore given, and this caused the descent of the tumour, which again projected at the anus, attached to a long pedicle. An attempt was made to pass a ligature around it, in case of hæmorrhage, but in doing this the pedicle broke, and the tumour separated without any hæmorrhage. The symptoms immediately disappeared. The tumour was rather larger than a nut, covered with mucous membrane, which, in a few places, shewed traces of abrasion, as though bleeding had taken place from this part: the interior was soft, cellular in texture, and not very vascular. On microscopic examination, it seemed to consist of an aggregation of cellular bodies, like nuclei, presenting, in some parts, an arrangement of cæcal pouches, somewhat resembling imperfectly formed glandular tissue.

Mr. Holmes, *2nd of March*, 1858.

---

15. *Rupture of the Colon produced by distention of the Gases within it. Malignant Disease of the Sigmoïd Flexure of the Colon.*

E. C., æt. 63, a hard-working woman, had always enjoyed good health, up to about six months ago. She then began to suffer from distension of the abdomen, from flatulence and constipation, and pain, which she referred chiefly to the region of the uterus. When the pain was bad, it was accompanied by numbness, and weakness, and twitchings of the legs. These symptoms increased up to the time of her death, which took place somewhat suddenly about seven months from the beginning of her illness. Charcoal, and pressure carefully applied to the abdomen, seemed to give her much temporary relief.

Post-mortem examination.—The abdominal walls were most tensely dilated with air, and when the cavity was punctured, air rushed out with extraordinary violence, the walls immediately falling down collapsed and flaccid. About six quarts of thick dark-

greenish-looking matter was found in the cavity of the abdomen, and two or three more quarts in the lower part of the intestines. In the upper part of the sigmöid flexure of the colon, there was a cancerous thickening in, and contraction of the walls of, the gut. The part diseased had been forced down into the pelvis (no doubt by the distended bowels), and had there formed an adhesion with the upper part of the rectum, giving to the intestine a curve, which must have materially assisted in impeding the passage of the fæces. The opening through the cancerous stricture, would scarcely admit the little finger. At the upper part of the descending colon, an opening, about an inch long, passing transversely across the gut, was discovered; there was no trace of ulceration about it, and merely a blush of redness around the border of the rent, which was clear and well-defined; the transverse muscular fibres were not torn, but separated at the rent. The fæces were inodorous, a fact explicable by the quantity of charcoal which the patient had taken, and which had accumulated in the bowels. The hypertrophy of the muscular coat of the intestine was, of course, caused by the obstruction at its sigmöid flexure.

The rupture of the gut evidently resulted from its distension by the air within it. The hypertrophy of the muscular coat would excite unusual pressure upon its contents; and it is possible, that the strychnia which the patient had taken for some time, might have aided in the pressure, by producing an inordinate, spasmodic contraction of the muscular coat.

Dr. MARKHAM, *6th of April*, 1858.

---

16. *Scirrhus Cancer of the Omentum, involving the Coats of the Colon at the Junction of the Ascending and Transverse Portions; Intestinal Obstruction relieved by Amussat's Operation.*

This specimen is of pathological interest, as shewing what I believe to be an infrequent seat of scirrhus, and of practical value, as proving that it is not impossible, in all cases, to diagnose the seat of intestinal obstruction. The disease in this case has developed itself in the upper portion of the omentum, adjacent to the hepatic flexure of the colon; it measures four inches in

length, about two inches in breadth, and about half an inch in thickness. On section, it was seen to have a yellowish, straw-colour tint, in all respects much resembling mammary scirrhus, except in its centre, where there are several cells filled with semi-transparent fluid. The coats of the colon were infiltrated (the sub-mucous especially) with cancerous matter, so as to give rise to an annular constriction of the gut, which will barely allow the passage of the little finger.

The mucous membrane on the surface of the constricted portion was not entirely destroyed; and this appearance, taken in connection with the fact, that there were other smaller cancerous masses in the omentum, led to the opinion that the omentum was the original seat of the disease. The coats of the stomach and small intestines were free from disease.

The patient, a lady, æt. 67, consulted me on the 10th of May, 1858, for an abdominal tumour, accompanied with vomiting and constipation. The tumour, as large as a cricket-ball, occupied the mid-region of the abdomen, immediately to the right of the umbilicus; it was flattened, and apparently adherent to the parietes; it was moveable in every direction, except upwards. There was some dulness on percussion over the tumour, the rest of the belly being remarkably tympanitic. She was of spare habit and cachectic appearance. The history she gave of her symptoms was, that six months previously she had discovered the swelling, but for eighteen months, she had been liable to occasional attacks of constipation, attended with severe pain at the stomach and vomiting; these symptoms were always relieved by purgatives. She had otherwise throughout life enjoyed robust health. One of her sisters died of cancer of the stomach. The present attack came on four days since, the only treatment she had received were globules from a homœopathic practitioner. The character of the alvine discharge had never been observed. She was ordered a mixture containing bismuth, hydrocyanic acid and liq. opii sedativus, with a view to allay the urgent vomiting; an injection to be administered immediately, and two drachms of castor oil and compound tincture of senna to be taken thrice a day.

On the 11th of May the vomiting was checked, the enema

brought away some fæcal matter, although it was not efficiently administered. I had about three pints of fluid thrown into the rectum by means of a stomach-pump, which brought away a considerable quantity of fæcal. She felt considerable relief afterwards.

On the 13th — As the vomiting continued, and as no further relief of the bowels had been obtained, she was ordered to discontinue all medicine, to suck small pieces of ice, and continue to drink milk and soda-water.

Satisfied now that there was a mechanical obstruction in the ascending colon, I advised the patient to inhale chloroform, and to have the abdomen well kneaded; and in case the obstruction was not overcome by this manipulation (which I have applied successfully in a similar case), to have an artificial anus made in the ascending colon. She consented to the manipulation, but declined interference with the knife. Accordingly, on the following day, with the assistance of Mr. Borlase Childs, I administered chloroform, and had the abdomen well kneaded, in the hope that if the obstruction arose from a twist of the intestines, internal hernia, intussusception, or a foreign body impacted in a constricted part of the gut, it might be overcome. After this proceeding, between three or four pints of warm water were forcibly driven up the rectum. No relief ensued, and she was informed that the only other means of relief was Amussat's operation, but inasmuch as her cousin, a medical practitioner, dissuaded her from submitting to it, she declined the suggestion.

On the 15th — As the symptoms had now become very distressing, and the vomiting stercoraceous, she consented to the operation. She was now in a very low state, verging on collapse, so that the chances of a successful result had been greatly diminished. Chloroform was administered, and Mr. Childs quickly and skilfully made an opening into the ascending colon, just above the crest of the ileum. The incision was made horizontally through the abdominal wall, and perpendicularly through the coats of the intestine. A bowlful of fæcal fluid was evacuated; when the effects of the chloroform had passed off, the patient was pulseless at the wrist, and had several attacks of syncope. Brandy was freely given; she, however, never fully rallied, but

died quietly five hours after the operation. On examination, it was found that the peritoneum had not been perforated in the operation; there was no congestion, effusion, or other signs of peritonitis. Dr. SEPTIMUS GIBBON, 18*th of May*, 1858.

---

17. *Cases of Diphtherite.*

These cases were six in number, of which two were fatal, and all occurred in the same house, which is large, roomy, well drained, and has a south aspect. The two first patients were sisters, as were also the four latter, and all were delicate children. There was no eruption in any case, nor any other symptoms indicative of scarlatina, croup, or of any peculiar exciting cause. The ages were from six to twelve years. In each attack there were other children in the house who remained unaffected, though no very rigid separation was enforced at first.

The symptoms were fever of a remittent type in the mildest cases, more violent and continued in the two fatal cases, but in all there was great depression of spirits. In the second and most rapidly fatal case of diphtherite, an eruption of purpura made its appearance over the neck, chest, and arms, eighteen hours before death. This is a singular complication of a disease in which the fibrin appears to be in excess; but the fact that diphtherite prevails most in low, marshy districts, and among feeble, ill-nourished children, seems equally inconsistent with its most striking morbid phenomenon, the deposition of fibrin upon the surface of mucous membranes. The local affection in the mild cases was pain and swelling of the fauces and tonsils, without very deep redness, followed, in a day or two, by elevated buff-coloured spots on the tonsils, which, coalescing, spread over them, and extended thence over the soft palate, like a thick patch of fibrinous deposit, which, after a few days, either peeled off in a mass, or seemed to dissolve, leaving a clean surface beneath. The posterior nares seemed also to be similarly affected, as the voice was changed, and there was a discharge, more or less sanious, in every case from the nostrils. In no case was there any reason to suppose that the disease had extended into the trachea or œsophagus, there being no difficulty of breathing

through the mouth, or of swallowing, except in one of the fatal cases, and then it was evidently spasmodic and only occasional. In the fatal cases the throat, thyröid and maxillary glands were greatly swollen, and though the membranes seemed to dissolve away before death, a bloody ulcerated surface was left, from which the sanies continued to flow to the last; and in one assumed a gangrenous odour thirty-six hours before death. This was a case in which the affected parts shewed an ulcerated, swollen, and gangrenous condition of the tonsils, and soft palate on both surfaces. The epiglottis was also discoloured, but the larynx and trachea were otherwise unaffected. The intellect in both remained perfect to the last, but the patient in whom the gangrene occurred, suddenly cried out, "Oh, my teeth," set her jaws, and fell back with opisthotonos, a few moments before death, which, in both, was preceded by throwing off the bed-clothes. Death took place on the fifth day in one, and on the twelfth in the other case. The rest recovered in about a week from the attack, except one, who had erythema nodosum, before she had regained her strength, and she remains still in a weak state.

The two first cases occurred in November, 1857, the four latter between the 8th of April and the 2nd of May, 1858, and no similar cases took place during the interval, in the house or its vicinity.

The discharge from the nostrils differed from that in scarlatina in being more watery than albuminous, as it formed no incrustations, nor did it excoriate the upper lips. The tonsils, also, were by no means as much swollen as in cases of scarlatina anginosa.

Dr. T. Ogier Ward, 18*th of May*, 1858.

II.—Liver and its Appendages.

18. *Cases illustrating the causes and effects of Obstruction of the Hepatic Ducts.*

The following cases illustrate some of the modes in which the hepatic ducts become obstructed, and demonstrate some of the ill effects which may ensue.

(1.) The causes of obstruction in the accompanying cases were

various: in the *first*, the obstruction was due to the growth of a small tumour in the parietes of one of the larger tubes; in the *second*, it was the result of stricture; in the *third*, it was produced by the impaction of a gall-stone in the common duct; in the *fourth*, it depended on the compression and partial destruction of the ducts by a series of knotty tumours; in the *fifth*, on cancerous infiltration of the walls of the ductus communis; in the *sixth*, on the constriction produced by malignant deposit in the tissue of the lesser omentum; and in the *seventh*, on the pressure arising from scirrhus of the glands about the head of the pancreas.

(2.) The consequences of obstruction also were various, the variations being dependent partly on the degree and age of the obstruction, and partly no doubt on accidental peculiarities in the condition of the patient, and even of the organ itself. The consequences were manifested in the ducts, in the contents of the ducts, and in the hepatic structure.

(*a*.) The ducts became dilated, in consequence of the accumulation of biliary fluid within them. In one case, where the obstruction had been partial, the resulting dilatation was sacculated; but generally it was tolerably uniform, and the enlarged ducts formed a series of branching canals from half an inch, or even two-thirds of an inch in diameter, downwards. The parietes of the dilated tubes were, I believe, generally somewhat thickened, or at any rate not less thick than natural. In one or two instances, there was possibly some degree of thinning; and in one (that of M. S., page 223), the parietes had become almost entirely destroyed, and a number of irregular biliary channels had resulted, in which suppuration had taken place, and which had finally formed numerous communications with the accompanying portal veins, and, through the medium of an abscess, had opened into the bronchial tubes.

(*b*.) The condition of the fluid in the bile ducts, if there be not from any accidental complication, admixture with blood or pus or other matters, would seem to undergo but little change. In almost all the cases recorded in this communication, the fluid was watery, and (according to the conditions under which it was viewed) of a dark-green or brown hue, without cholestearine, and without concretions of any kind.

(*c.*) In most of the appended cases, the liver was enlarged; in two its bulk was natural; and in one decidedly diminished—these changes being analogous to the parallel changes occurring in the kidney in connection with obstruction of the ureter, and being explicable on the same principle. The substance of the organ was generally soft, and not only soft, but loose and flabby in texture, it had acquired a deep olive-green tint, and yielded a watery bilious fluid on pressure. These alterations in consistence and colour, though frequently pervading the entire liver, were generally most marked along the portal vessels, and sometimes in the beginning affected isolated patches of tissue only (as is shewn in case (1.), and also in the case of J. W. H., page 223). Under the microscope, the tissue of the affected liver was occasionally found to present no trace of liver cells, the place of these bodies being occupied by oil, and greenish or yellowish granules, and masses of concrete biliary matter. This destruction of cells, however, seems to be by no means constant, and even when present is often limited to certain parts of the organ only; for in cases where the obstruction has been of long duration, and in which its ill effects in other respects have been extreme, the hepatic cells may still be in existence and little altered from the natural condition, except that they may be loaded with oil, or biliary colouring matter, or concrete bile. There can be no doubt, however, that the tendency is to the ultimate destruction of the cells, and that the looser and more succulent the tissue has become, the more likely shall we be to find that the cells have disappeared.

CASE 1. *Obstruction of one of the Hepatic Ducts by a Tumour developed in its walls. Partial Dilatation of Ducts, etc.*

C. W.—F., æt. 25, married. Four months before death delivered of a still-born child. About six weeks after this she was attacked with very severe hæmoptysis, and soon after became jaundiced. The hæmatemesis, with melæna, recurred several times, and she died after a severe attack at the end of May, 1850.

Post-mortem examination.—Liver large, soft, and rather pale. The gall-bladder and the surface of the liver in its neighbourhood were adherent to the duodenum. The former was natural in size,

but flaccid (being nearly empty); and on its right side, half way between its neck and fundus, presented an orifice about a quarter of an inch in diameter. This orifice communicated with a pouch-like sinus about half an inch long, which opened into the first part of the duodenum, by a perforation resembling in size and other characters that by which the sinus opened into the gall-bladder. On making an incision into the liver, parallel and about an inch and a half to the right of the suspensory ligament, a spherical mass was laid open, measuring an inch in diameter, and consisting of a soft, yellowish-green material. The mass was deepest in hue in the centre, and towards the circumferences shaded off insensibly both in colour and in other respects, into the surrounding structure. A large hepatic duct, passing from behind forwards, was in contact with it inferiorly, and two considerable branches —one from the right, the other from the left—joined it in this situation, passing in their course through the substance of the mass. They were somewhat dilated, and their walls had a green hue. The mass was external to the ducts, and did not appear to communicate with them. On tracing the first-mentioned duct backwards, it was found to dilate (about half an inch behind the mass above-described), into a cavity which occupied about an inch of its length and measured about an inch in circumference, and which was surrounded, in the greater part of its extent, by a soft greenish substance, similar to, but less in amount, than that constituting the mass previously alluded to. On tracing the duct forwards, it was found, about an inch and a half from the junction of the cystic and hepatic ducts, much dilated and almost entirely blocked up by a growth which sprung from its lower wall. This growth was about equal in bulk to a moderate-sized horse bean, was of a pale liver colour, soft in consistence (especially in its interior), somewhat irregular in shape, and appeared to have originated in the substance of the wall of the duct, inasmuch as the lining membrane could be traced in parts from the duct on to the sides of the tumour, though not completely over it. Several other ducts which communicated with this one behind the seat of obstruction were laid open, but found to present no abnormal appearance.

The microscope displayed a large excess of oil in the liver-cells generally. The greenish substance presented a few liver-cells

distended with oil, and numerous free oil globules floating in a yellow fluid, but no cholestearine. The growth appeared to consist of a faintly-granular, almost structureless matrix, with numerous oil-globules disseminated through its substance.

Several ulcers were found in the duodenum, at a distance of an inch or two from the pylorus. One in the upper wall with smooth round edges, communicated with the sinus before described. In the neighbourhood of this were two or three small superficial excoriations; and on the opposite wall of the gut were two similar ulcers of rather larger dimensions.

CASE 2. *Cirrhosis; Abscess of Liver; Stricture and Dilatation of Ducts; Fatty Kidneys.*

B. P.—M. æt. 39. Jaundice, enlarged and fatty kidneys. Liver adherent to surrounding parts. Its size was nearly normal; but the relative size of the two lobes was reversed. On section of the left lobe, the tissue generally was found to be somewhat indurated, granular, and of a dark olive-green colour. Here and there manifest cirrhosis was present. The hepatic veins of the lobe were normal. The branches of the artery and of the portal vein were also healthy; but the ducts which accompanied them were frequently dilated to two, three, or four times the diameter of the contiguous portal venous branch. The walls of these ducts were comparatively thick and tough, and almost exactly like those of the hepatic veins, and nowhere shewed any tendency to atrophy or perforation. They contained a thin light-yellow biliary fluid, loaded with yellow sabulous matter and darker coloured concrete masses of comparatively large size. On dividing the right lobe, a considerable portion of its substance presented the same characters as that of the opposite lobe, but much of it was in an advanced stage of cirrhosis, and a very considerable portion was reduced to a dense light-coloured fibröid material from which all traces of gland structure were absent, or were present only as an occasional olive-green nodule. In one place was an abscess as large as a good-sized chestnut, it was bounded by dense cartilage-like parietes, and was filled by dirty yellowish

pus, in which were disseminated minute fragments of solid biliary matter. The vessels and biliary tubes of this lobe were healthy. The common gall-ducts were pervious and healthy, and filled with thin yellowish granular bile. The cystic duct was pervious and the bladder distended by a slightly glairy, transparent, greenish fluid. The left hepatic duct, close to its union with the right was much contracted, and scarcely admitted the passage of a probe, the circumference at the point of constriction not measuring more than two lines. The stricture, which exactly resembled an urethral stricture, and was attended by thickening of the parietes, with evident marks of cicatrization, did not occupy more than a quarter of an inch of the tube; and immediately beyond it, the tube became dilated to such an extent as to measure between three-quarters and one and a quarter of an inch in circumference. The right hepatic duct was healthy.

CASE 3. *Obstruction of common Duct by a Gall-stone; Dilatation and Destruction of Hepatic Ducts, etc.*

See case of M. S. (page 219.)

CASE 4. *Knotty Tumour of Liver; Obstruction and Dilatation of Hepatic Ducts; Ascites, etc.*

J. W. H.,—M., æt. 33. Intense jaundice, anasarca, ascites.

The liver was decidedly diminished in size, of a deep olive-green colour, and so soft that numerous lacerations were produced in its removal. The ducts were extremely dilated, those leading directly to the transverse fissure being nearly capable of receiving the tip of the little finger. They contained a thin, watery, and very slightly yellowish fluid. Their parietes were little changed, but were, if anything, somewhat thicker than usual. Occupying the substance of the liver, in the situation of the lobulus Spigelii, and transverse fissure, and extending through to the upper surface, were a series of knotty tumours, altogether about equal in size to a hen's egg. Several projected from the upper surface, but a still greater degree of projection (sufficient to displace the portal vessels)

was present on the lower surface. The branches of the vena portæ and hepatic artery connected with these growths, were pervious and healthy, but the right and left hepatic ducts could not be traced by their walls more than half an inch from their junction; and after careful examination, it was found that each hepatic duct, for a distance of about one inch and a half, was totally destroyed, and replaced by an irregular channel, passing through the centre of the tumours, the parietes being formed by the substance of the tumours, to which adhered a tough, greenish-yellow deposit. These channels could be traced with difficulty, and were so irregular that they had probably formed a complete barrier to the passage of the bile. The gall-bladder was full of tenacious, stringy, brownish mucus, and contained two or three gall-stones, each about as large as a marble. The common duct was pervious throughout, but contained no trace of bile, and its parietes were perfectly colourless. Under the microscope, the liver-cells were found to be nearly, if not quite, as perfect and as abundant as in the healthy organ. They contained but little oil, and had, for the most part, a yellow tinge; and intermixed with them were numerous yellow and brownish masses of what appeared to be concrete biliary matter.

The intestines contained no trace of bile.

CASE 5. *Cancer of Stomach, Liver, and Peritoneum; Cancer of Walls of Common Duct; Obstruction and Dilatation of Tubes.*

J. D.,—M., æt. 54. Cancer of stomach, liver, and peritoneum. Jaundice. The liver was large, and presented several cancerous tumours. Its substance was soft, and deeply stained with bile, and the ducts were generally and greatly dilated. Under the microscope, its cells were seen to be loaded with biliary matter and oil, and mixed with them were numerous free granules, small oil-globules, and minute yellow concretions. Here and there the cells appeared to be absent, and replaced by the other elements just described. The gall-bladder was of ordinary size, and contained a little brownish bile. The cystic duct, a little above its union with the hepatic, was found to be much thickened by cancerous infiltration of its walls; and the common hepatic duct was in precisely the same condition. By careful dissection, the

canal was traced in both instances, and the mucous surface was found to be healthy. Yet, although the passage could be demonstrated, they were virtually obstructed by the thickening of the parietes; as was shewn by the deep jaundice present, by the emptiness of the ductus communis choledochus below the tumour, and by the great dilatation and distension, with bile, of the hepatic duct above.

CASE 6. *Cancer of Lesser Omentum; Obstruction and Dilatation of Hepatic Ducts.*

C. H.—F., æt. 50. Deep jaundice, great emaciation.

Liver larger than natural, soft, and of a uniform deep olive-green colour. The ducts were universally dilated, but not to an extreme degree, and they were filled with deep-green limpid fluid. Gall-bladder, of moderate size, and filled with the same kind of bile as that observed in the ducts. The small omentum, from the liver to the pancreas, was infiltrated with dense white scirrhus. The vessels and ducts passed through the midst of this mass—the former were pervious, but the latter were narrowed and compressed, so as to be completely impervious.

CASE 7. *Cancer of Pylorus, Duodenum and adjacent parts; Obstruction of Common Duct; Dilatation of Hepatic Ducts.*

R. J., a married woman, æt. 49, was admitted under my care on the 6th of October, 1857. She stated, that six months ago she began to suffer from pain at the chest after food, with occasional vomiting of clear acid fluid. These symptoms continued to increase upon her, and six or seven weeks since, slight jaundice made its appearance. Latterly she had occasionally vomited fluid, having a coffee-ground character.

On admission, she was found to be emaciated and feeble, and much jaundiced. She vomited after everything she took in the way of food, and suffered constant pain in the region of the stomach, and in the back. She had no appetite, complained of thirst, and her tongue was coated. The urine was high-coloured, and the motions pale, though decidedly tinged with bile. The bowels were confined. Pulse 94. A distinct tumour could be felt

through the abdominal parietes, in the epigastrium to the right of the mesial line. Under the treatment that was adopted (nitric acid with calumba and opium, and occasional purges) the more distressing symptoms were for a time arrested; the pain diminished, the vomiting ceased, the appetite so far improved that she at times enjoyed her meals, and the bowels became tolerably regular. But occasionally the old symptoms returned, and especially towards the close of her life. The other symptoms, however, never presented any decided amelioration; the jaundice, at one time lighter, at another more intense, continued; the tongue remained furred, the pulse rapid; the urine was always stained with bile, and the motions, though usually tinged, continued pale; the fluid vomited had every now and then the character of coffee-grounds; the tumour in the abdomen could always be distinguished, and she became uniformly weaker and more emaciated, and died on the 12th of November.

Post-mortem examination.—Much emaciated and deeply jaundiced. The thoracic viscera were healthy. On opening the abdominal cavity, the peritoneum appeared, for the most part, healthy. The stomach was much dilated. Its outer surface was generally healthy, but in the neighbourhood of the smaller curvature was studded with lenticular patches of hard cancer, which became blended with one another as they approached the small omentum, which was itself, in part, infiltrated with cancer. The muscular and mucous coats were also, on the whole, healthy. The cavity contained much brownish material, which had a little of the appearances of coffee-grounds. The pyloric valve was much thickened in all its dimensions; and on a vertical section, it was seen that the mucous and sub-mucous coats, in this situation, were infiltrated with a whitish, and not very hard, material, that the muscular coat was hypertrophied, and that the external parietes were thickened, and the seat of cancerous growth. The disease extended for about two inches along the duodenum, occupying its entire circumference. The parietes were thickened, and infiltrated with cancer, but the internal surface was smooth and slightly granular, though apparently slightly excavated. It looked as though it had been evenly destroyed by ulceration, and that the process had become arrested, for there were no traces of

sloughing, and none of fungating granulations. The liver was of ordinary size, decidedly not hypertrophied. Its surface presented a deep olive-green hue, studded however with numerous spots of a lighter and yellower tint. On passing the finger over the organ, a sensation was experienced, in many situations, similar to that caused by the presence of a vein in indurated brawny integuments. On section, the liver was found to be soft and flabby in texture, and to yield a large quantity of greenish-yellow fluid on pressure. Its tissue was partly of a deep olive-green hue, and partly of a bright greenish-yellow colour. The darker coloured portions seemed to be somewhat softer than the rest, and to be arranged (though unequally so) along the portal vessels. The ducts throughout the organ were much dilated, the primary trunks measuring about an inch in circumference and being large enough to admit the tip of the finger, many of the others being nearly equally capacious, and the rest varying from this size to that of a goose's quill. The walls of the ducts were certainly not thinned, indeed they seemed, if anything, thicker than natural. They were all filled with a dark-green limpid fluid. The common hepatic duct was traced from the transverse fissure to the duodenum, and found to be pervious in its whole extent. Its upper half was dilated, though less so than the branches which united to form it. Its lower half was somewhat constricted, and considerably compressed by accumulation of cancerous deposit in the tissues and glands around it; and it appeared that the pressure thus produced, had caused almost complete obstruction to the passage of bile. The gall-bladder and cystic duct were both of them somewhat dilated, and contained a similar fluid to that observed in the hepatic ducts. Pancreas, for the most part, healthy; its right extremity, however, was indurated, and evidently partly involved in the cancerous growth developed in its neighbourhood. The tissue of the lesser omentum, and some of the glands in the great omentum, along the spine, and in the mesentery, were the seat of scirrhous cancerous growth. All the other abdominal viscera were healthy, except the uterus, whose os was obliterated, and the ovaries which were much atrophied.

On examining the liver with the microscope, its cells were found, in many parts, to be undistinguishable, and replaced by

oil and by concrete biliary matter in the form of orange-coloured granules, and masses. In other parts they were present, sometimes healthy, at other times smaller and less perfect than natural, but generally loaded with oil, stained with bile, and presenting granular concrete biliary matter. The cells were absent and least distinct in those parts of the organ which were softest and of deepest colour.

It may be worthy of remark, that the nitric acid was given under the impression that its local influence might be beneficial upon the cancerous ulcer that was supposed to exist; and that there is some reason to believe, both from the decided amelioration of the symptoms referrible to the stomach, and from the *post-mortem* appearances, that the action of the remedy was really that which was desired. Dr. Bristowe, *17th of November*, 1857.

---

19. *Medullary Cancer of the Common Bile-duct; Dilatation of all the Biliary Ducts; Enlargement of the Gall-bladder; Cancerous Growth in the Pancreas; Intense Jaundice.*

The history of this case of cancer of the common bile-duct, which produced obstruction to the flow of bile, and intense jaundice, is briefly as follows:*—Y. S., a cabinet-maker, æt. 36, was in good health until about the 1st of June, 1857, when he was first troubled with vomiting and purging. In the course of three or four weeks, he became intensely jaundiced. He did not remember ever having passed gall-stones. On the 17th of July, he complained of a settled dull pain in the region of the liver, loss of appetite, thirst, and lassitude. The pulse was frequent, but feeble; the stools were white; the urine loaded with bile. The liver was much enlarged, and sensitive to pressure. The patient said he had been under the influence of mercury, but no local applications had been employed in the region of the liver. Saline aperients, and a nitro-muriatic acid mixture, with taraxacum were ordered, and mercurial ointment was applied to the region of the liver. This treatment was continued till the 31st

* I am indebted to Dr. Cooper Rose, of Hampstead, and to Mr. Balding, for notes of this case.

of July, at which date the general symptoms remained much the same as before, but the liver was diminished in size, and was much less sensitive. A mercurial course was now commenced.

On the 4th of August, the jaundice was as bad as ever; the stools were white, and the urine contained much bile. The liver was not so sensitive to the touch, and was considerably diminished in size. A blister was applied, and dressed with mercurial ointment; and small doses of mercury were given twice a day. On the 13th, he felt better; the liver was reduced to nearly the natural size, and the tenderness had disappeared. The gall-bladder was perceptible to the touch, and was apparently about the size of a small pear. He was now slightly under the influence of mercury. The jaundice had increased, the stools were still pale, and the urine dark. He felt low-spirited, and spent sleepless nights. On the 25th, the gall-bladder was more prominent.

On the 1st of September, he was admitted into the Middlesex Hospital, with intense jaundice. He complained of pain about the region of the liver, and of tenderness upon manipulation. The dulness on percussion extended downwards almost to the umbilicus, but its extent was not well-defined. In the right hypochondrium, there was a firmer resistance than on the left side, but no distinct irregularities of the liver could be made out. The urine was very dark-yellow, and the motions were quite chalky, without a trace of bile. A nitro-hydrochloric acid bath, every second night, was ordered; also gentian and taraxacum. The patient appeared better for a few days; but about a fortnight after admission, a tumour was detected in the right iliac region. On percussion, the dulness produced by it was continuous with the hepatic dulness, but the tenderness over it was greater than at any other part of the abdomen. About a week after this, he became suddenly unconscious, and symptoms of rapid dissolution, with muttering delirium, supervened. These symptoms, however, gradually subsided in the course of an hour, and no further head symptoms were observed; but he gradually sank and died, on the 21st of October, nearly six months after he first took ill. Among the remedies employed may be named, the iodide of potassium, the bicarbonate of potash with infusion of gentian,

also a lotion of nitro-muriatic acid, and subsequently an ointment of iodide of potassium with mercurial ointment.

Post-mortem examination. — Body emaciated and intensely jaundiced; abdomen drawn in; no œdema of legs. The right lung was firmly fixed by old adhesions; the left pleural cavity contained five ounces of yellow serum. The pulmonary substance was of a dark-yellow colour, and on pressure yielded a yellow frothy fluid. The heart weighed six ounces, was flabby, and stained yellow; the pericardium contained half an ounce of yellow serous fluid. The liver weighed sixty ounces; the upper border reached to the level of the fourth rib; the fundus of the gall-bladder projected three inches beyond the anterior margin of the liver, and extended to within an inch of the anterior superior spinous process of the ileum. The gall-bladder measured seven inches and a half in length, and its coats appeared very thin from the great distension. The common bile-duct was also much distended, and appeared larger than a man's thumb. On cutting into the liver, a large quantity of fluid, resembling barley-water, poured from all the divided biliary ducts, which were evidently much dilated; the cut surface exhibited a dark olive-green colour, with the outline of the lobules distinct, and all the biliary ducts were enormously dilated. The gall-bladder was very much distended, and contained fifteen ounces of a pale muddy fluid, resembling barley-water, which, on standing, deposited a dark sediment, consisting of particles of inspissated bile. This fluid was alkaline, and its specific gravity was 10·10. On being examined with the microscope, it was found to contain numerous very large cells, with from two to four nuclei, having nucleoli, besides masses of tesselated epithelium, granular matter, etc. The internal surface of the gall-bladder had lost its reticular appearance, and presented a rather rough, red, granular surface; the cystic duct was much dilated. The common bile-duct was obstructed, but a probe could be passed upwards from the opening in the duodenum. The obstruction of the duct was produced by an exuberant growth of medullary cancer from the internal surface of the duct, and this extended from the opening in the duct for about two inches upwards; the growth was nodular, and appeared to be extending upwards; on cutting into some of the

nodules, a glairy tenacious juice was obtained, which, examined with the microscope, exhibited several large, compound, nucleated cells, free nuclei, and spindle-shaped cells. The large compound cells were similar to those found in the fluid from the gall-bladder.

The head of the pancreas was involved in a growth larger than an orange; on section, this was found to present a medullary appearance, and yielded a copious, thick, milky juice, which, examined with the microscope, exhibited many large nuclei, but no mother cells. This tumour, no doubt, pressed upon the common bile-duct, but did not perforate its walls; the growth in the duct appeared to have arisen independently from its lining membrane, although the tumour of the pancreas was in close proximity.

All the other organs were tolerably healthy, but were, for the most part, stained with bile. Even the brain presented a jaundiced appearance.

Dr. Van der Byl, *2nd of February*, 1858.

---

20. *Cirrhosis of the Liver; the Gall-bladder filled with four Biliary Calculi, one of them Encysted.*

R. S., æt. 73, was long subject to chronic indolent ulcers of both legs, for which he was a frequent inmate of a Hospital. He was very intemperate, and had been a hard drinker for many years, during which time he had delirium tremens several times, and suffered from symptoms indicating chronic disease of the liver and spleen. He was admitted into Hospital for great debility, accompanied by fever, and died a few days after admission apparently from old age.

The *post-mortem examination* was made by myself, twenty-four hours after death. The lungs were perfectly healthy, and pleuritic adhesions were present in various parts, the results of former inflammatory attacks, as they formed thin membranous bands, of a character resembling fibrous tissue. The heart was larger than usual; the aortic valves were studded with atheromatous deposits, and so were the mitral valves, and the muscular structure of the organ seemed fatty. The coronary arteries on both surfaces of the

heart were affected with atheroma, and each vessel contained a fine delicate string of fibrin, resembling a white thread, which was visible through its coats. The aorta and its branches were dilated, but not diseased. The intestines were healthy, but very small, especially the entire colon. The liver was one half its natural size, hard, and nodulated on the surface, in a state of cirrhosis, presenting a good example of the hob-nailed variety. On searching for the gall-bladder, I discovered it to be almost completely embedded in the surface of the liver, and full of hard substances which proved to be calculi, four in number. Three of these were of the same size and colour, and consisted of cholestearine and colouring matter; whilst the fourth as large as a robin's egg, weighed sixty-six grains, was of a whitish colour, intermixed with little coloured patches, and composed of pure cholestearine. The surface of this calculus was, for the most part, crystalline, and this appearance was due to an aggregation of flat and foliacious crystals of cholestearine, as seen under the microscope, a good deal like the mineral selenite, or crystallized sulphate of lime. It blocked up the cystic duct most completely, and had become regularly encysted. Not a drop of bile was present in the gall-bladder, but on dissecting the arteries of the liver, their internal surface had the same colour as if bile had existed therein. One part of the liver seemed to be gangrenous, as was also both kidneys, superficially. A section of the latter organs, shewed a large quantity of fat surrounding the calices. The spleen was enlarged, had lost its purplish-red colour, and was covered with irregular hard white patches here and there, but especially over its convex surface. Some of these were cartilaginous and elevated, varying in size from a crown-piece to a pea. Its internal structure was rather different, and none of it possessed a normal firmness. The remaining viscera were healthy. The thyröid and cricöid cartilages, together with the upper rings of the trachea, were in a state of ossification from calcareous deposit.

The interesting feature of this case is, that the largest and most perfect calculus occupied a distinct cyst, blocking up the cystic duct, and preventing the passage of the bile into its reservoir. The presence of a cyst is a peculiarity by no means

common. Dr. Gross mentions in his *Pathological Anatomy*, third edition, page 618, that he has occasionally seen biliary calculi encysted, and in one instance, he found several of considerable size, situated beneath the mucous membrane, in separate sacs.

Dr. Baillie, in his *Morbid Anatomy*, likens the structure of the shining white crystals of cholestearine in biliary calculi, to mica or spermaceti, and whilst admitting they much resemble the latter, I think the mineral selenite, affords a still better resemblance of their true appearance.

It is due solely to the fact of its being encysted that this oval calculus has preserved such a beautiful surface; had it been otherwise, attrition would have produced the same form as in the other specimens. Dr. GIBB, 16*th of February*, 1858.

---

21. *Calculus of Inspissated Bile, associated with Fibrous Tumours of the Uterus.*

An aged woman, died from apparent old age in the General Hospital at Montreal, in September, 1845, when I was a medical officer of that Institution. I made a *post-mortem examination* the following day, and found a small calculus in the gall-bladder, of a dark blackish-brown colour, of a somewhat quadrangular form, the size of a small pistol-bullet, and composed of inspissated bile. It seemed to be an agglomeration of about thirty smaller bodies, which separated on the slightest handling, the entire weight being ten grains. Two fibrous tumours grew from the walls of the uterus, one the size of a walnut from the lower part of its left side, the other as large as a marble from the lower part of its right anterior surface. Nothing else abnormal was found. The uterus, with these two tumours, is preserved in the Museum of the French School of Medicine at Montreal.

Some time afterwards, I came across another example of a similar form of calculus of the same colour, composed of inspissated bile, weighing seventeen grains, crumbling on slight handling, which I removed from the gall-bladder of another old woman, who died of typhus fever.

Of the three varieties of gall-stones usually described by chemists, namely the cholestearic, mellitic, and biliary, the last is

considered very rare, being made up of inspissated bile, and is sometimes of a semi-concrete consistence. This is especially the case when first removed from the gall-bladder; it then becomes dry and brittle, and soon crumbles into fragments, as was the case with the two specimens which I exhibited on this occasion. Inspissated biliary calculi assume a yellowish-cinnamon colour, but are less common than the blackish-brown.

Dr. Gibb, 16*th of February*, 1858.

---

22. *Specimen of Cancer of the Liver, with Remarks on twenty-nine cases.*

This is the largest cancerous liver I have yet met with, and occurred in the youngest but two of twenty-nine subjects, with cancer of the liver, examined by me at the Middlesex Hospital.

The liver weighed twelve pounds, and contained several cancerous growths varying in size from half an inch to four or five inches in diameter. The largest growth was situated in the right lobe, and extended into the right iliac region. On section, the hepatic tissue appeared normal, and all the cancerous growths exhibited a well-defined outline. They were mostly round, firm, yellowish-white, and presented a fibrous stroma, with a clear juice between the meshes; but, on squeezing, yielded a turbid juice (not thick and pulpy) which under the microscope exhibited numerous nuclei of large size, but no mother-cells.

In this case, cancerous growths also involved the skull and dura mater, the sternum, humerus, lungs, and spleen.

The growth on the skull was about the size of half an orange, and situated over the occipital bone. It sent bony spicula inwards, which involved and penetrated the dura mater, below the left lateral sinus, and produced yellow softening of the brain, and breaking up of the cerebellum. The upper part of the sternum was involved in a tumour, about the size of two fists, the half of which projected into the chest. It was firm, nodulated, and elastic, exhibiting a radiating fibrous appearance on section. The lower half of the humerus was surrounded by a layer of can-

cerous growth, about one inch thick. A soft tumour was situated along the right side of the lumbar vertebræ; and a section having been made in the mesial line, it was found to protrude into the spinal canal, and produce compression of the cauda equina, having destroyed a portion of some of the bodies, and transverse processes of the vertebræ. The glands in the groin were enlarged. The right lung contained a medullary mass the size of a walnut, in the upper lobe; the surrounding pulmonary substance was for the most part solidified, and contained several small abscesses, but there did not appear to be any tubercle anywhere. The left lung was œdematous, and congested at the back. The heart weighed twelve ounces; the valves were healthy; there was no disease of the aorta; some serous fluid, with a little recent lymph, occurred in the pericardium. The spleen weighed five ounces, and contained a white nodule the size of a pea, with the same structure as the growths in the liver. The stomach was healthy. The kidneys were pale, flabby, and fatty; the capsule was adherent, and the external surface lobulated. Two or three fibröid nodules about the size of peas, occurred in the medullary cones.

History.—The patient, a young man, æt. 28, was admitted into the Middlesex Hospital on the 11th of March, 1856, with an enlargement in the right side of the abdomen, which he had noticed for about a week. He stated, that nine years ago, he had had syphilis, which was followed by sore-throat; that he took mercury, and was salivated. He remained in tolerable health till nine months before admission into the Hospital, when he had an attack of rheumatism, chiefly in the bones, which compelled him to give up work. He soon recovered; but, two months before admission, he was seized with pain in the arm, followed by swelling, and shortly afterwards, a swelling appeared over the sternum. These swellings in the arm and sternum, as well as the tumour in the abdomen, had increased very rapidly in size. Soon after admission, a friction sound was heard in the cardiac region. He did not complain at first of any pain, except a deep-seated aching in the spine. Subsequently, he had pain and tenderness over the enlarged liver. Early in April, he called attention to a swelling over the occipital bone; this increased rapidly in size, but was only painful when pressed upon. He

sank gradually, and died on the 28th of April, less than four months after he had first noticed the swelling of the arm.

Remarks.—Although the enlargement of the liver was not noticed until some weeks after the swelling appeared in the arm and over the sternum, yet I am inclined to consider this a case of primary cancer of the liver, because it is very probable that the disease was going on in the liver long before it was noticed, and the very rapid secondary development of a growth over the occipital bone, after the tumour of the liver was noticed, leads one to think that the cancer of the humerus and sternum were probably also secondary growths. At all events, the disease ran a very rapid and wide-spread course.

Cancer of the liver occurred in twenty-nine cases out of three hundred and eighty *post-mortem examinations* conducted by me; that is, in upwards of seven and a half per cent. of the patients dying from various diseases. Out of these twenty-nine cases, thirteen were males, and sixteen females. The average age of the thirteen males was 41·4 years; the youngest was 15 years of age; the oldest, 55. The average age of the sixteen females, was 50; the youngest, 33; the oldest, 70. The average weight of the liver of the thirteen males, was 71·5 ounces; the average weight of twelve of the females, was 49·5 ounces. The average weight of the healthy liver of twenty-six males, examined by me, was 51·3 ounces; and of twenty-five females, 43·8 ounces. So that cancer increases the weight of the liver about forty per cent. in the male, and about twelve per cent. only in the female.

It is difficult to state, exactly, in how many of these twenty-nine cases, the liver was the primary seat of the cancer; or, to be quite sure in which organs the disease commenced. In three cases, cancer did not exist in any other organs, and these may, therefore, be considered as undoubtedly primary cancer of the liver. But, in the remaining twenty-six cases, other organs were involved in the cancerous disease, as follows:—the lungs, in nine cases; the breast, in seven; stomach, in six; uterus, in five; rectum, in two; post-peritoneal glands, in two; lumbar glands, in two, inguinal glands, in two; external genitals, in one case; face, one; tongue, one; œsophagus, one; and membranes of brain,

in one case. By counting the case, which forms the subject of this paper, along with the three undoubted cases of primary cancer of the liver, it appears that cancer occurs primarily in about one-seventh of the cases in which the liver is affected by this disease.

Cancer is generally said to be more frequent in the liver than in any other organ. Out of the three hundred and eighty *post-mortem examinations* conducted by me, the relative frequency of cancer in different organs was as follows:—in the uterus, thirty-two cases; the liver, twenty-nine; lungs, nineteen; breast, eighteen; pleuræ, ten; stomach, nine; tongue, six; kidneys, six; bladder, five; œsophagus, four; rectum, two; external genitals, two; pericardium, two; dura mater, two. Although cancer of the liver did not occur quite so frequently as cancer of the uterus: yet, making an allowance for the proportionally greater number of females admitted with cancer of the uterus, on account of our having special cancer wards, whereas cancer of the liver ranks with other internal complaints, I think that cancer is certainly far more frequent in the liver than in any other organ.

The principal morbid appearances which accompanied these twenty-nine cases of cancer of the liver, were:—chalky concretions, or cicatrices in the lungs, in eight cases; pleuritis and carnifications of the lungs, in three; granular kidneys, in seven: fibrous tumours in uterus, in three; peritonitis, in two; fatty heart, in one; adhesions to transverse colon, in one; jaundice, in two.

The liver-tissue intervening between the cancerous growths, generally presented a normal appearance; hence, doubtless, the rarity of jaundice, which only occurred in two out of the twenty-nine cases. In one case, the liver-tissue is noted as somewhat waxy, and in one case as fatty.

Dr. Van der Byl, *6th of April*, 1858.

---

23. *Large rounded Cyst in the substance of the Liver, containing fluid and surrounded by a thick layer of Carcinomatous material. Cancer of the Pylorus of the Stomach.*

The cavity was about equal in size to that of a large cricket-ball. It was surrounded by a layer of softish carcinomatous

material, of a yellowish-white colour, and of about three-quarters of an inch in thickness (Lign. 7). This carcinomatous material was not separated from the substance of the liver by any capsule or proper investment, nor was its inner surface, that usually forming the boundary of the cyst, covered by any kind of membrane. On the contrary, the parietes of the cyst were roughened by the projection into it of jagged processes of carcino-

LIGN. 7.

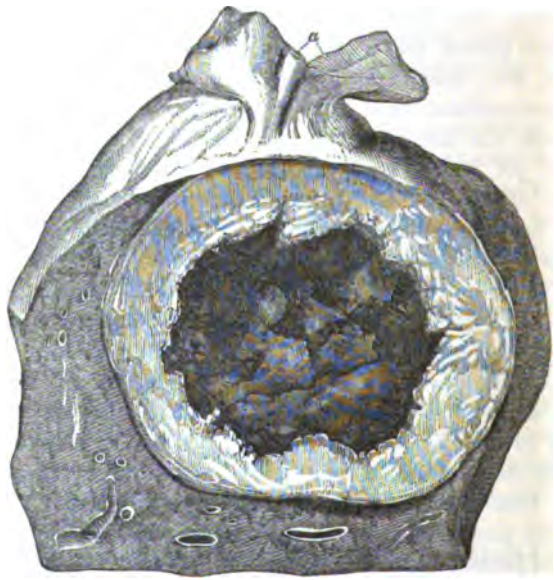

This figure represents the cyst, with its carcinomatous investment, and the portion of the liver, in which it was situated.
a. Part of the diaphragm.

matous material. The cyst was full of light-coloured fluid, containing shreddy particles of broken-down carcinomatous material which had evidently been separated from the walls of the cyst. On section, the whole cyst with its thick walls, reminded one forcibly, at first sight, of a small cocoa-nut full of fluid. The cyst was situated in the right lobe of the liver, and

at its upper part was so near the surface of that organ as only to be separated from the ordinary fibrous capsule of the liver by the thick deposit of carcinomatous matter forming its thick wall. That part of the capsule of the liver above-mentioned was very thickened, and at this place the liver was firmly adherent to the under surface of the diaphragm which here was corrugated or thickened (*vide a.*, Lign. 7.). Besides the mass of carcinomatous matter which surrounded the cyst, masses of a similar nature were found in other parts of the liver, forming nodules and tubera of various sizes; chiefly situated near the surface of the left lobe. In no other instance, however, did any cavity exist in connection with the growths. The substance of the liver generally was congested, but not otherwise obviously affected; the vessels and ducts appearing healthy.

Much thickening also existed of the pyloric end of the stomach, with ulceration of its inner surface, owing to carcinomatous infiltration; but no other organ was affected in a like way.

No excess of fluid existed in the peritoneal cavity.

History.—The specimen was removed from the body of J. P., a man, æt. 50, who having suffered from a so-called "stoppage at the pit of the stomach," with much pain and "rising of clear water," and vomiting, came into St. George's Hospital. He was much emaciated, and the subject of frequent hiccough, and much discomfort after taking food. The bowels were confined and there was some fulness, but not any hardness perceptible about the epigastrium; he had sickness at intervals, but never had vomited blood or any grumous matter. The dulness on percussion caused naturally by the liver, was greatly increased, but although the countenance became very pallid, no distinct yellowness of skin was produced. On one occasion whilst in the Hospital, he vomited blood. Before death, which was apparently from inanition, he became comatose.

Microscopical Appearances.—The thick walls of the cyst shewed exactly the same histological characters as the carcinomatous masses in other parts of the liver, which were those of soft encephalöid as ordinarily met with. Moreover, the flakes and small masses met with in the fluid contained in the cyst, and which gave it a slight turbidity, presented the same character-

istics, but also contained much fatty matter. No cholestearine or biliary colouring matter or indications of the presence of entozoa were seen in the fluid.

Remarks.—The case is interesting by reason of the connection between the large cyst and the mass of carcinomatous material; what this connection may be, is open to question. It might, under some circumstances, be a dilated duct in the walls of which the growth had arisen, but the absence of any other similar instances in the liver, and even of any apparently diseased ducts or vessels of any kind, and the freedom from biliary matter in the fluid contents of the cyst, are facts opposed to this idea. Of course the fluid had nothing to do with the development of entozoa; and I can only conclude, that the cyst was formed by the gradual softening and crumbling down of a large (the largest) mass of carcinomatous material in the liver spreading from the centre towards the periphery—watery fluid from some source or other accumulating. I am, however, quite at a loss to account for the absence of so much solid matter, as must, under this supposition, have once existed, and have been in some way or other removed, making way as it came for the fluid.

In a practical point of view, the cyst is most interesting as shewing one of the difficulties which may arise in diagnosis in connection with supposed collections of fluid, serous or purulent, as in the liver. The cyst was evidently approaching the surface of the liver by the gradual diminution of its walls, of which a part was situated at the very surface itself of the liver, and had formed adhesions to the diaphragm shewing a tendency to soften and so open in that direction. It is clear, that if such a carcinomatous growth were situate near the anterior margin of the liver, adhesions between it and the anterior abdominal parietes might form, as with the diaphragm (the upper abdominal parietes), and thus we might in time have fluctuation and prominence perceptible by the hand.

In this way the question would arise as to puncture and withdrawal of the fluid whatever its nature might be, by trocar or the establishment of suppuration, under the supposition that we were dealing with a serous cyst, or abscess, or entozoic collection

of fluid. I have not myself ever seen any other instance like the present one, which would form a precedent for supposing that a fluid formation in a cancerous mass might exist within the liver. Thus in addition to the above kinds of fluid collections, the possibility of a carcinomatous cyst, must enter into our criterion of diagnosis, and of course, our prognosis will be affected accordingly, as no doubt, in all such cases of carcinomatous cysts, the microscope will reveal some remnants of disintegrated particles by which a knowledge of the future course of such a cyst may be attained. The only cases of carcinomatous deposit which I can call to mind as shewing the formation within them of cysts arriving at any great size, are some of cancer of the mammary region, but in none I believe did they approach in size to that of the present instance. Dr. JOHN W. OGLE, *2th of April*, 1858.

---

24. *On the connection between Abscess of the Liver and Gastro-intestinal Ulceration.*

The close connection existing between abscess of the liver and dysentery has long been recognized. But the nature of this connection has been variously interpreted by different authors; so that while some have looked on it as purely accidental, others have regarded the intestinal affection as secondary to the hepatic, and others again, have considered the abscesses of the liver as the direct consequence of the colic ulceration.

The difficulties which attend the investigation of this subject are by no means slight. For, if the cases be chronic, as they usually are when they come under observation in this country, they can rarely be relied on for the determination of the relative priority of the co-existing lesions; and even if they be acute, the presence of hepatic abscess may not infrequently be overlooked; especially when its own symptoms, naturally obscure, are masked by the more urgent sufferings which belong to the dysenteric complication.

That the frequent concurrence of the two diseases, is the result of mere accident, as Dr. Abercrombie suggested, is a view which is utterly untenable, and has been abandoned on all hands.

The theory which attributes the dysentery to the effects of

hepatic disease is that, I believe, which has been generally adopted by the Indian writers, and is maintained by them, even to the present day. But the difficulties which it involves in reference to the explanation of the mode of production of the intestinal disease, have thrown just suspicion on its truth, and have unjustly tended to weaken the force of the facts on which it is founded.

The last theory—that which makes the abscesses in the liver dependent on the colic ulceration, and explains their formation on the well-known principles of purulent absorption—was proposed by Dr. Budd some thirteen years ago, and sustained by many ingenious arguments. The theory was so plausible, it explained so clearly and so thoroughly all that had before been dark; that, notwithstanding isolated facts and experiences which have seemed to militate against it, it has, I believe, received the almost unanimous sanction of the medical profession of this country.

But Dr. Budd has gone further. Not satisfied with thus explaining the coincidence of abscess of the liver with dysenteric ulceration, he extends the application of the principle to all cases in which hepatic suppuration is associated with ulceration of any part of the gastro-intestinal mucous membrane and its diverticula, no matter what the nature of that ulceration may be. And he expresses a decided belief, that almost all cases of abscess of the liver, which are not dependent on mechanical causes, are the result of purulent infection.

Having had some reason, from facts which have occasionally come under my notice, to doubt the general applicability of Dr. Budd's theory; I have, for the purpose of testing it, analyzed the *post-mortem* records of St. Thomas's Hospital, which have accumulated during the last eight years; and I intend to lay the results of this analysis before the Society this evening.

During this period, have been preserved the records of about one thousand five hundred post-mortem examinations; out of which number, three hundred and twenty-four presented either distinct ulcers, or cicatrices in the gastro-intestinal mucous membrane; and thirty-one exhibited abscesses in the liver, or conditions closely related to abscess.

One hundred and sixty-seven of the three hundred and twenty-

four cases of ulcer, furnished examples of tubercular ulceration of the small or large intestine, or both. And of these, twelve were associated with the small tubercular cavities of the liver, which have been well described by Louis; but not one was accompanied by true hepatic abscess. I need scarcely observe, that there is no ground whatever for supposing, that the vomicæ alluded to were due to purulent infection; they were true tubercular cavities, associated generally with distinct unsoftened tubercles in the same organ.

Forty-five were specimens of typhöid ulceration of the ileum, combined, in some instances, with similar disease of the colon. Twenty-five were cases of malignant ulceration of the stomach, rectum, or some other part of the alimentary canal, accompanied frequently by cancerous growths in the liver or other viscera; but in no instance was either of these forms of ulceration associated with hepatic suppuration.

In fifty-five cases, the ulcers were of a miscellaneous nature; that is, some were simple ulcers of the stomach, or of the small or large intestines; others were mere cicatrices; others were the result of disease, commencing on the exterior of the gut; one was a duodenal ulcer, consequent on a burn; one was the sequel of a pyæmic abscess, arising in the substance of the intestinal walls; and the remaining examples were equally indeterminate in character, and difficult of classification. Three of these cases were conjoined with abscess of the liver. But in one of them, the hepatic abscess and the intestinal ulcer were equally the effect of general pyæmia; in another (see vol. viii., p. 346), the erosion of the bowel was due to the pointing of a circumscribed accumulation of pus in the peritoneum, which had itself resulted from the rupture of an hepatic abscess; and in the third (case of M. S., in the following paper), the duodenum and transverse colon were directly perforated by an abscess connected with the hepatic duct, and situated in the transverse fissure of the liver; so that in all three the connection was purely accidental, and in neither of them could the hepatic suppuration have been produced by the intestinal lesion.

Thirty-two cases of ulceration still remain. To these, I have ventured to apply the term dysenteric, and in four of them, ab-

scess of the liver co-existed with the intestinal disease. But these cases varied a great deal amongst themselves; some being very slight, others exceedingly severe, and others again presenting peculiarities which render it doubtful whether the classification of them under this head is altogether justifiable.

Sixteen, or one half of the total number, were very slight; and of these, eight were associated with acute pneumonia (to which fact I have drawn attention in a paper published in the last volume); one was combined with acute peritonitis, one with intense congestion of the lungs, liver, and kidneys; and one severally with empyema, heart disease, renal affection, pyloric cancer, delirium tremens, and apoplexy; but not one was associated with abscess of the liver.

The remaining sixteen were all severe. Seven were chronic, and of these, four were attended by phthsis, to which the intestinal affection was probably essentially due; one accompanied renal disease; and two were idiopathic and uncomplicated. Nine were acute, and of these, one was developed in the course of empyema, one in the course of chronic vesical and renal inflammation, and one supervened on sloughy ulceration of the legs. One was combined with gangrene of the lungs, and epileptic convulsions, a combination which proved fatal after a few days; and the remaining four were all associated with abscess of the liver.

The analysis up to this point, therefore, gives no support to Dr. Budd's theory, so far as that theory relates to the dependence of hepatic abscess on gastro-intestinal ulceration generally; but it tends to confirm Dr. Budd's, and the commonly-entertained belief, in the intimate connection between abscess of the liver and dysenteric ulceration. Since, however, the analysis must necessarily be imperfect, without taking into consideration the number of cases in which hepatic abscesses were discovered, and without an examination of the causes on which the abscesses depended, I shall proceed to investigate this second branch of the inquiry.

The histories are preserved of thirty-one cases, in which suppuration in one form or another, was discovered in the liver; but in twelve of these cases, the abscesses were simply tubercular, associated with tuberculosis of other organs; in five, they were

due to general pyæmia, and were small and numerous as such abscesses usually are; in four, they were produced by the presence of hydatids; and in the remaining ten only, were they, in the conventional application of the term, idiopathic.

Of the last ten cases, which alone require to be analyzed, in reference to any connection with intestinal lesion, six were associated with ulceration of the bowels. But of these six, in two instances (which have been previously alluded to), the intestinal complication was directly or indirectly produced by the discharge of the contents of the abscess through the intestinal walls; so that in four cases only can the possibility be entertained of the dependence of the hepatic suppuration on the intestinal disease, and in each one of these, the disease of the bowels was severe and well-marked acute dysentery.

In one of the six cases unconnected with dysentery, the abscesses were consequent on obstruction of the common hepatic duct by a gall-stone, followed by dilatation and partial destruction of its ramifications in the substance of the liver. In another, the abscess was small, associated with cirrhosis, and accompanied by stricture of the left branch of the hepatic duct. The abscess may, possibly, have been due to by-gone ulceration in the seat of stricture; though I suspect not, and my suspicion is strengthened by the fact, that the stricture and the abscess were in opposite lobes. The other four cases, however, were, so far as could be ascertained, strictly idiopathic. And hence the conclusions to be derived from the examination of the above cases are still adverse to the existence of any necessary connection between ulceration of the intestines (exclusive of dysentery), and the formation of hepatic abscesses.

From the large proportion, however, which cases of abscess of the liver, associated with dysentery, bear to the total number of cases of idiopathic hepatic suppuration; the importance of the connection between the two affections, which was strongly indicated in a previous part of the inquiry, becomes remarkably confirmed. But what the nature of that connection may be, remains still to be ascertained by an examination of the facts presented by the four cases in which the lesions were combined. Let us then proceed with the examination.

In the first case, that of T. S., the patient was admitted after having laboured under obscure symptoms for a fortnight only. On admission, there were clear indications of an hepatic abscess, which was opened at the end of three days, and at the end of six began to discharge through the lung. Two weeks after admission he died, the bowels having been regular and the motions natural until the morning of the day on which he sank, when, for the first time, the motions assumed a dysenteric character. This man had never been abroad, and never suffered from any severe illness; and although he admitted that he had had diarrhœa for ten days, six weeks before admission, the attack was so slight that he only acknowledged it after having been pressed upon the point by myself, and then spoke of it as a very trifling matter. Now, I cannot admit that there is any reason to suppose that he laboured under dysentery at that time; and if he did not do so then, it is perfectly clear that the hepatic suppuration preceded by four weeks the occurrence of the dysenteric ulceration, and that therefore the latter was secondary to the former. But even if it should be maintained that the antecedent diarrhœa was essentially dysenteric, and that the hepatic abscesses were the result of it, it is still clear that the bowels recovered their natural condition and continued healthy for a period of eight weeks, and during the greater part of his illness, and that the final dysenteric attack, therefore, was undoubtedly secondary to the hepatic disease. I may add, that the *post-mortem examination* revealed no indication of old intestinal ulceration; it was all of one character, recent and severe.

In the case of C. H., the man had been abroad, and even wounded with a sabre over the region of the liver, many years ago, but had never suffered from fever or dysentery, had enjoyed perfect health, and had continued in its enjoyment until five days before his admission. When first seen, he was clearly suffering from an abscess in the liver; after fourteen days it was punctured. Two days after the operation, he passed, for the first time, a dysenteric stool; and evacuations of the same character were repeated during the day, and in the early part of the next, in the afternoon of which he died. Now, it is quite clear that in this case no intestinal affection either preceded the hepatic suppuration, or ac-

companied it, until the day before the patient's death; so that here also the hepatic abscess anticipated the dysenteric disease. A fact which the post-mortem examination also tended to confirm.

The third case is that of J. C. This man had been abroad and suffered at one period of his life from some hepatic affection. The disease for which he was admitted was chronic pleurisy, under which he had been labouring for seven months, and under which he continued to labour in the Hospital during the five months which preceded his death. Diarrhœa came on two or three weeks before the final issue of his case, but no hepatic abscess was ever, I believe, suspected during life. Now, the diarrhœa had certainly only existed two or three weeks, and the autopsy shewed the recent character of the ulceration. But how long had the abscesses been in existence? They were large, and from the flocculent character of their surface, probably extending; yet, at the same time, the liver-structure around them was indurated—a condition which never accompanies recently-formed abscesses. From which latter circumstance, as well as from the fact that the presence of empyema on the same side must necessarily have masked any symptoms the abscesses might have given rise to, I believe they had been in existence for a considerable period, at all events much longer than the ulcers in the colon. In confirmation of which view I may direct attention to the remarks which I appended to the *post-mortem examination* at the time it was originally written out, remarks made at a time when all the facts of the case were before me, and when, moreover, I had no theory of my own to support or upset.

In the fourth case, that of R. F., the history is unfortunately very meagre and incomplete, though so far as it goes, authentic. He was admitted after having suffered for four weeks from diarrhœa, he continued in the Hospital fifteen days, and at the end of that time died. During this time he was treated for his most prominent syptoms, namely, those of chronic diarrhœa; but no abscess of the liver was either discovered or suspected. The intestinal disease was extensive, and the hepatic abscesses were large, so that from *post-mortem* appearances it was utterly impossible to say which had had the priority. It might be supposed that the dysentery had preceded the hepatic affection, from the greater

prominence which its symptoms had assumed. But it must be recollected, that the abscesses were not even suspected towards the close of life, at a time when it is certain they must have been present; and hence they may have been in existence and escaped discovery during a considerable period of time, so that there is really nothing to indicate that they were secondary to the intestinal affection. The fact is, that the case tends to confirm the connection only between the two diseases, and not to throw any light on the nature of that connection.

I think it must be admitted that the above cases are not propitious to Dr. Budd's views. In the first two, the hepatic disease decidedly preceded the intestinal mischief, and if, therefore, these lesions were related to one another in the way of cause and effect, must have produced the dysentery. In the third case, the sequence of events is not so clear, but the balance of probabilities is, I think, decidedly opposed to the pyæmic theory. In the fourth case, however, there is nothing at all to indicate which was the original lesion, and hence it cannot be regarded as either favourable or unfavourable to the theory in question.

The facts, then, which I have collected from the experience of a large Hospital, extending over some years, yield no sort of confirmation to the supposed dependence of abscess of the liver, on portal pyæmia resulting from gastro-intestinal ulceration. For not only do they fail to shew any kind of connection between hepatic suppuration, and any kind of intestinal ulceration, except the dysenteric; but they indicate that even in those cases in which hepatic abscess and dysentery were conjoined, the only demonstrable connection between them was the converse of that which the pyæmic theory requires.

Since I have ascertained how little the results of my own experience accord with the general applicability of the theory which Dr. Budd has advanced, I have examined more closely than I had hitherto done, the evidence by which that theory is supported; and shall proceed to comment briefly upon it.

Dr. Budd adduces, first, the fact of the occasional occurrence of hepatic abscess in the course of general pyæmia, and justly infers from analogy, that portal phlebitis must be capable of producing purulent infection, which from the peculiar distribution of the

portal system would necessarily produce its most serious manifestations in the substance of the liver. And indeed, further on in his work, when discussing the diseases to which the vessels of the liver are liable, he reports one or two cases in which suppuration of the portal vein, unconnected with ulcerated intestine, produced a large number of small hepatic abscesses; and he quotes several examples in which numerous abscesses (probably pyæmic) supervened rapidly on surgical interference with the lower part of the bowel. So that, I think, that he has succeeded in shewing satisfactorily, that portal pyæmia does occur, and that it may lead to hepatic suppuration; and I am even prepared to admit, that the quoted cases were, most probably, what they are represented to be, and that they further shew the possibility of portal pyæmia and abscesses of the liver succeeding upon surgical operations connected with the intestines. Whence I cannot but allow the possibility of hepatic abscesses being, in some instances, produced from portal pyæmia arising in connection with ulceration of the stomach or bowels. But has Dr. Budd done anything more than pointing out the possibility, which I admit, of this sequence? I confess I think not. From an analysis of his own, and of other published cases of abscess of the liver, he shews that hepatic abscesses are very frequently associated with ulcers of the intestines; and he infers from that, that they are, therefore, secondary to them; but when one considers how commonly ulcers, or the remains of ulcers, are observed in some part of the alimentary canal, one can scarcely be justified, I suspect, in interpreting the mere frequency of their coincidence as a proof of the existence of a causal relation between them; yet this in truth is the only kind of proof, which he adduces of a pyæmic connection between abscess of the liver, and the ordinary forms of intestinal ulceration. He points out clearly enough, however, that there is an intimate relationship between dysentery and hepatic abscess, and demonstrates quite satisfactorily, I think, that the connection between this form of intestinal affection and abscess of the liver, is far too intimate and remarkable to be looked upon as accidental. But even here he fails altogether, in my opinion, to prove by a single fact, his view of the relationship between them. He remarks, "I have generally found it impossible to tell from

the history of the case, which had the priority, the disease of the liver or dysentery," and his own cases indicate clearly the greatness of the difficulty which he thus acknowledges. For neither of the instances which he adduces from his own practice in support of his theory, proves more, than that dysentery may precede the appearance of abscess; or (perhaps with more logical accuracy) than that severe dysentery, which has been known to exist for some time, may be associated with hepatic abscesses, which from their smallness, and from their never having been recognised during life, are inferred to be of subsequent origin. Further, in none of these cases is there any history of dissection having discovered phlebitis of any of the mesenteric veins connected with the ulcerated bowels. And I may add, what Dr. Budd allows, that the abscesses connected with dysentery are usually few and large; instead of being numerous and small, as one generally, if not always, finds them to be when they are due to undoubted purulent absorption.

It seems to me, therefore, that since the accumulated experience of Indian writers, tends in general to oppose Dr. Budd's theory, since my own facts are adverse to it, and since Dr. Budd's own arguments, as I read them, only prove its possible applicability in some cases, we are justified in rejecting the pyæmic theory of the acknowledged relationship between dysentery and hepatic abscess, and in seeking, therefore, for some other explanation.

The explanation which refers the dysentery to antecedent hepatic disease, is to some extent supported by three of the cases which I have brought forward; since there can be no doubt that in them the intestinal disease was secondary in point of time, at least, to the formation of abscess in the liver. Notwithstanding, however, that numerous cases are recorded in which either it is certain, or there is good reason to suppose, that the intestinal lesion supervened on that of the liver; there are great objections against regarding the hepatic disorder as the cause of the dysenteric ulceration. For, in the first place, acute and severe dysentery is of constant occurrence, especially in hot climates, without any kind of evidence of antecedent or associated hepatic disorder; and abscess of the the liver not very infrequently runs

its course without any dysenteric complication. And, in the second place, if the sloughing of the colic mucous membrane is to be regarded as the result of the hepatic disorder, the only conceivable mode in which that result can be attained, is, as Dr. Budd justly remarks, through the irritating effects of the hepatic secretions. Yet, how is it possible to suppose, that if the dysentery is produced by the passage of irritating or unhealthy bile over the colic mucous surface, the mucous membrane of the whole length of the small intestines should so invariably retain its integrity! I may here remark, that in none of the five cases of hydatid abscess of the liver—cases in which the suppuration was as extensive as in any of the cases of idiopathic abscess I have described, and which, in fact, resembled them in everything save the exciting cause—that in none of them was the large intestine affected, although such a complication might naturally have been looked for, if dysenteric ulceration were capable of being produced by hepatic suppuration.

If then, we are forced to the conclusion that, notwithstanding the frequent coincidence of dysentery and abscess of the liver, the abscess of the liver cannot be regarded as the consequence of the intestinal disease, nor the dysentery as the result of hepatic disorder, what plausible explanation of their coincidence can be given? In the first place, as before remarked, it is certain that in those countries in which hepatic abscess is common, dysentery also is remarkably prevalent. In the second place, it is incontestable that where dysentery prevails, though some cases may be associated with hepatic suppuration, the majority are uncomplicated; and it is equally incontestable, that hepatic abscess may exist without being associated at any time with dysenteric disease; since, therefore, both diseases appear to arise indiscriminately under nearly, if not quite, similar circumstances, it seems not unfair to assume, that that general cause, which in one individual may excite abscess of the liver, in another may give rise to dysentery, and in a third, to a combination of the two diseases; or in other words, that when the two diseases co-exist, they may be usually regarded as the concurrent effects of one cause, which is equally capable of producing each affection separately. I must admit, that in three

of the cases which I have appended to this paper, the relationship which I have here sought to establish is not satisfactorily displayed; yet, bearing in mind the analogies, which are offered by the mode in which joints are successively affected, even up to the end of the disease, in rheumatism, and by the supervention of renal disease in the course of scarlet fever, we shall scarcely be indisposed to admit, that the same cause which produced the primary affection in other classes of disease, would be competent to excite the secondary, even though the latter were developed a considerable time after the former. Yet, even if these cases do not fall in with my theory, I feel sure that the explanation which I suggest is more generally applicable and less liable to objection than either of those which I have ventured to criticise. Moreover, its probable truth is enhanced by facts, which I have previously laid before the Society, in reference to the connection between pneumonia and dysentery—facts which are fully discussed in a paper published in the last volume of the "Transactions" (vol. viii., page 66).

CASE 1. *Abscesses of Liver; Punctured externally, and opening through the Lung. Dysentery.*

T. S., a stevedore, æt. 31, was admitted on the 22nd of September, 1857, into St. Thomas's Hospital. He stated that he had been a great drinker, but had enjoyed good health until a fortnight ago, when he was attacked with pain under the point of the right shoulder, and on the following day observed his belly beginning to swell. These symptoms, attended by prostration of strength and loss of appetite, continued up to the time of admission, but during the first week of this period they had not been sufficiently urgent to prevent him from following his ordinary occupation. He had not suffered from cough or sickness; nor had he laboured under diarrhœa or abdominal uneasiness, neither had he experienced rigors. Further inquiries elicited that, about six weeks before admission, he had had an attack of diarrhœa which lasted two weeks, but it was so mild in its character that he only acknowledged the fact in reply to a leading question. He had never been out of the United Kingdom.

On admission, he appeared feeble, and had a somewhat anxious expression, but was quite sensible. The skin was dryish and sallow, but not jaundiced. The fingers were clubbed. The tongue was dry down the centre, but clean. He was thirsty, and had lost his appetite, but was not sick, and had no cough. He could lie only in one position, *viz.*, on his back with an inclination to the right side. The right side of the chest was much distended, and the lower intercostal spaces appeared widened and convex from above downwards. There was complete dulness over the lower half in front and laterally, with diminished vocal fremitus and absence of breath sounds. The belly was not tender, but the epigastric region was much distended, and presented a nearly hemispherical swelling, measuring between three and four inches in diameter. Ordered; two grains of calomel, and five of Dover's powder to-night; a large linseed-meal poultice to the belly; milk diet; and a warm bath to-morrow morning.

During the next two or three days he continued in much the same state. Was ordered on the 23rd, a grain of iodide of mercury thrice a-day; and on the 24th, ten leeches to the epigastrium, and soda-water.

25th.—On this day the epigastric tumour, which had been getting larger, distinctly fluctuated and appeared to have but a thin wall. It was opened by a small incision, and about half a pint of thick pus escaped. A probe, introduced through the orifice, passed for at least four inches perpendicularly backwards, but could not be directed into, or even towards, the dilated and dull portion of the right side of the chest.

Medicines, previously ordered, to be omitted. To take three grains of sesqui-carbonate of ammonia, and ten minims of tincture of cinchonæ, out of decoction of cinchonæ, thrice daily—two eggs and porter one pint daily.

26th.—Slept well last night and awoke refreshed. Tongue cleaner and more moist. Has taken his food, and his appetite is altogether improved. Mixed diet instead of milk diet.

27th.—Slept badly last night. Skin warm and somewhat moist. The bowels have not been opened since the 22nd. The wound has been kept open by a pledget of lint, but not more than an ounce or two of pus have escaped daily, and this has

gradually become extremely fetid. To take a dose of castor oil.

28th. — The oil operated freely. Last night he began suddenly to spit up pus; could not sleep, and was occasionally light-headed. Has lost his appetite—pulse 132, very weak—no abdominal tenderness. To return to the milk diet; to have two eggs, beef tea, and three glasses of wine daily.

1st of October. — His cough has continued troublesome, and last night he brought up much thick purulent matter; slept very badly. Tongue morbidly red and glazed, dry all along its centre, thirsty. Skin dry, but he sweats at night; pulse 112, small and feeble, respiration 32. Perfect dulness over the whole of the right side of the chest, except quite at the upper part, and absence of respiratory sounds over the lower half, and of all movement during respiration.

2nd.—The patient evidently becomes more and more feeble. Sleeps badly. Pulse 102, small. Respirations 33. Had a suffocative fit of coughing early this morning, during which he brought up a large quantity of pus. Bowels open naturally twice a day. His face and skin generally are sallow, but not jaundiced. Features sharp. Lips pallid and dry. Tongue red and dryish; is thirsty. The phenomena connected with the chest are the same as yesterday. There is a diffused fulness in the epigastrium, in the centre of which is the incision made on the 25th of September, and which still discharges an ounce or two of fœtid pus daily. There is but little abdominal tenderness; but his only comfortable posture in bed is an oblique one, inclining to the right side.

3rd.—Much the same; passed a very bad night and groaned much. No attacks of cough or expectoration of pus. Pulse 100, very feeble. Expression very anxious.

5th.—Much worse. Cheeks sunk, face very anxious, expiration attended by a groan. Pulse 140, scarcely perceptible. Spat up three or four ounces of pus a little after noon, but none between then and the last visit. Bowels opened yesterday and during the night, the motions presented nothing remarkable.

6th. — Was very restless this morning, but became more calm towards noon; at two o'clock P.M., he passed motions twice

consisting apparently of black clots of blood; and at a quarter to three he died quietly, retaining his mental faculties to the last.

Post-mortem examination, on the 7th. Height, five feet eleven inches. Weight, nine stone ten pounds. Somewhat emaciated, not jaundiced. The right side of the chest and upper part of the belly seemed distended, and a small incision existed a little below the xiphöid cartilage.

Chest.—Pericardium and heart healthy. The left lung was unadherent, large, crepitant, and healthy throughout. The right lung was very firmly adherent by old, thick adhesions; and these adhesions between the lung and the side of the chest presented a tough fibröid mass, infiltrated with earthy deposit, about equal in area to the entire hand, and from a quarter to one-third of an inch thick. The lung was small and pushed up high into the chest. Its posterior half and its apex were, for the most part, slightly crepitant and not unhealthy; but the greater part of the lower lobe, and especially its anterior portion, were hollowed out into a series of cavities communicating freely with one another, and through the diaphragm with an abscess in the liver. The cavities contained greenish-yellow and somewhat stringy pus, and their parietes were formed by softened, lacerated, shreddy, lung-tissue, without any thickening, or any deposit of lymph on the surface. They looked, but did not smell, gangrenous. The bronchial tubes connected with the lower part of the lung contained pus.

Abdomen.—The liver was exceedingly large, its lower edge extending below the margins of the ribs as far down as the umbilicus. It was attached by not very firm adhesions to the parietes in front, but much more firmly and completely to the diaphragm. It was removed in conjunction with the right lung, to the base of which it was almost inseparably united. It was then discovered that the right lobe alone was enlarged, that it had extended not only down to the umbilicus, but high into the right side of the chest, and had encroached somewhat on the left side also. It contained about half a dozen abscesses which varied a little in size, but on the average were as large as a good sized orange. One, which had during life occupied the apex of the

scrobiculus, and was immediately to the right of the suspensory ligament, was adherent to the anterior parietes, and still presented an opening by which it had been punctured during life. Its cavity contained a little thick pus, had partially collapsed, and had been compressed by the enlargment of neighbouring abscesses. Its parietes presented a reticulated, fibröid character, the fibröid layer, however, being exceedingly thin and delicate. The largest abscess was situated behind and to the right of this, and communicated freely through a large, irregular, ragged orifice in the diaphragm, with the cavities in the lung. It contained a yellowish-green, glairy pus, and numerous soft, flocculent, flesh-coloured shreds of tissue. This abscess also was somewhat irregular in shape, apparently from collapse and pressure; and its parietes, like those of the former, were corrugated, reticulated, and formed of a whitish, fibröid material. In both cases the reticulated character was due to the projection in relief of a network, the intersections of which were irregular in size and distribution, and looked not unlike an arborescent arrangement of vessels; a careful examination, however, failed to confirm what first appearances seemed to indicate. There were at least four more large abscesses in the right lobe, equally distinct from one another and from the two just described. They were each more or less globular, full of thick, curdy pus, and their immediate parietes were formed, for the most part, by a deposit of flocculent lypmh. In some situations the layer of lymph was very thin and delicate; in others it varied between a quarter and one-third of an inch thick, was homogeneous in texture, and tolerably tough; while in other situations again, they were immediately bounded by liver-structure infiltrated with pus, which when the pus was washed away, was found to consist only of a loose network of soft, fibrous, flesh-coloured tissue. In some cases the infiltrating abscesses, just described, were merely continuations of the larger ones, to which they were conterminous, while in others, although the same connection might really have existed, it was not discovered. In the case of the larger abscesses above-described, the separation between them and the liver-structure was due merely to a recent, and, for the most part, thin deposit of lymph. As regards those collections of pus, however, which I have termed infiltrating

abscesses, they were not separated from the surrounding tissue by any definite limit, but their loculi, becoming smaller and smaller, ultimately lost themselves in the surrounding structures. The left lobe presented two or three abscesses about as large as walnuts. In each of them, the centre formed a small but distinct abscess, whilst the periphery consisted of a series of pus-holding loculi, which, gradually becoming smaller and smaller, and less distinctly purulent, passed insensibly into the liver-substance around. The tissue of the left lobe of the liver was generally pale and healthy; but the little that intervened between the abscesses in the right lobe was soft and congested. None of the larger abscesses communicated (at least directly) with one another. The ducts and vessels of the organ and the gall-bladder, were healthy.

The cæcum, ascending and commencement of the transverse colon, presented numerous sloughy ulcers, most of which took a transverse direction and occupied the prominent folds. They varied from one to one and a half inches in length; their surfaces were shreddy, slate-coloured and sloughy-looking; their margins also were shreddy, but not thickened; there was no congestion of the mucous membrane immediately surrounding them, neither was the corresponding serous surface in any way affected. The ulcers in fact, appeared quite recent, and due, apparently, to sloughing, of isolated portions of mucous membrane. There were no scars and no evidence whatever of old disease in any part of the large intestines.

The stomach and small intestines, and all the other abdominal viscera were healthy; and there was no peritoneal mischief beyond the adhesions which bound the liver to surrounding parts.

The abdominal cava for three inches of its length was distended with coagulum, a small part of which was fibrinous, and slightly adherent to the walls; but there was no evidence of disease in the walls themselves. The part obstructed was situated in the lumbar region, two or three inches below the liver. Aorta healthy.

CASE 2. *Abscess of Liver, punctured externally. Secondary Hepatic Abscesses. Dysentery.*

C. H., a rigger-man, æt. 54, was admitted on the 6th of October, 1857. He stated that he had been much abroad, and in the habit of drinking; but that he had generally enjoyed good health, and had never suffered either from fever or from dysentery. He had had a sabre-wound years ago over the region of the liver, but had never suffered any ill-consequences. He asserted that he had been ill, and unable to attend to his duties for the last five days only; that his illness began with sharp pains in the left side of the epigastrium, working thence to the right hypochondrium, and increased by pressure. He first observed enlargement of the upper part of the belly a day or two afterwards; and this, together with the other symptoms, increased up to the time of admission. There was no irritation of the bowels during this period, neither had there been any previously; on the contrary, there was a decided tendency to constipation. He had not suffered from nausea or sickness.

Present condition.—The skin is hot and dry, and not jaundiced. The lips are somewhat parched, the tongue is covered with a white fur. He complains of thirst, and has lost his appetite. Bowels confined. Pulse 98, tolerably strong and full. Heart sounds natural. He has no cough; the chest is normally resonant, and the breath sounds are healthy. There is great fulness in the epigastric and right hypochondriac regions; resistance to pressure as though from the presence of a solid mass beneath; and dulness on percussion as low as the umbilicus, and for two or three inches on each side of the mesial line. He has considerable tenderness over this space, and complains of constant and severe throbbing pain which prevents the slightest movement of the body, and obliges him to lie on his back. He neither has, nor has had, pain in either shoulder.

Eighteen leeches to the epigastric region. A purgative dose of jalap and calomel to-morrow. Milk diet.

8th.—The leeches procured so much relief, that he experiences now no pain so long as he is perfectly still; and the bowels have been freely relaxed by the powder. He has slept comfortably,

and in all other respects remains in the same condition as before.

To take five grains of blue-pill and a quarter grain of opium, thrice daily; and a dose of castor oil to-morrow.

12th—The bowels were relieved by medicine on the 9th; and since the 10th, have acted naturally. The abdominal tumour appears to have become more prominent, and at the same time to have extended over a large space. Its most tender point is to the left of and below the ensiform cartilage, and in that situation an indistinct sense of fluctuation exists. His sleep has been somewhat disturbed. The tongue is fissured, dryish, and covered with a white fur. He is thirsty; without appetite; has a disagreeable taste; but no nausea. Pulse 94; respirations 26, quiet. No pain in the tumour while at rest. Omit pills. The tumour to be painted with tincture of iodine.

14th.—Is very weak; and has, to-day, for the first time, a short cough, the paroxysms of which produce considerable pain in the region of the liver, and are followed by the expectoration of a little tenacious mucus, streaked with black pigment. Fluctuation still indistinct. Bowels open.

17th.—Was ordered on the 15th, one ounce of the decoction of bark, three times a-day. His nights have been restless; his bowels open, without medicine, two or three times in the twenty-four hours. He is becoming more and more feeble; and his expression of anxiety is becoming every day more marked. The tongue is still dry, but the fur has diminished and exists in irregular patches. He is thirsty and takes nothing solid. Skin dry and cool. Cough less troublesome. The respiratory sounds are healthy; and the chest is normally resonant, except that the resonance on the right side does not extend below the sixth rib. The tumour has become somewhat more prominent on the left side, and fluctuation has become distinct. The pain in it has been gradually returning during the last two or three days. Pulse 92, urine of an orange colour, with a copious red deposit. Linseed-meal poultices to the belly. Wine, two glasses.

21st.—On the 19th, three grains of Dover's powder three times a-day, and a grain of opium every night, were prescribed in order to procure him sleep, and to relieve his abdominal pain. He slept

comfortably the next night; but during the whole of last night was disturbed by constant hiccough, which, attended by frequent groaning, continues to the present time, coming on with nearly every other inspiration. He has been getting much more feeble and exhausted; the pulse is weaker and has mounted to 106; the pain in the tumour has been getting more severe, and for the last few days he has been able to lie on the right side only. The tumour itself has been getting more prominent, fluctuation has become more distinct, and the lower ribs of the right side have began to bulge a little. The tongue, too, has been getting somewhat drier and covered by a brownish fur. But he still has no sickness, and the bowels have been regularly opened two or three times daily until to-day.

Ordered, sulphuric æther, aromatic spirits of ammonia, compound tincture of camphor, and camphor mixture, every four hours.

On the 22nd.—Is in a low, typhöid state. Pulse, scarcely perceptible. The hiccough and groaning continue. The abdominal pain is considerable. In the hope of relieving these symptoms, it was determined to open the cyst, although the skin over it was moveable, and although, therefore, uncertainty as to whether adhesions had formed, which had contra-indicated the operation previously, still existed. An opening was made over the most prominent part of the tumour, and nearly two quarts of chocolate-coloured, puriform fluid escaped. Although rendered extremely faint (which condition was obviated by two glasses of wine), he experienced immediate and great relief.

On the 24th.—Although considerably relieved, as regards pain, by the operation, and although the hiccough has disappeared, he has continued to sink. He slept comfortably last night, but woke about four A.M., and has continued groaning ever since. At nine this morning, he passed an extremely fœtid motion, mixed with puriform matter. Expression haggard and anxious; extremities cold; lips parched; tongue rough and dry, but not furred; much thirst. Pulse 106, just perceptible; repirations 18. Cough and expectoration as they were when last described.

On the 25th.—Extremely feeble; pulse, imperceptible at the wrist; respirations 36, and attended by groans. Did not sleep. Complains only of feeling heavy. Has had two motions similar

in all respects to that passed yesterday morning. The opening in the abdomen has been kept open, and has discharged three or four ounces of pus daily.

He died about a quarter of an hour after these notes were taken, etc.

Post-mortem examination.—Height, five feet seven inches; weight, seven stone ten pounds. Somewhat emaciated, but not jaundiced. There was an incision an inch long in the scrobiculus, a little to the left of the mesial line, and the scar of an old sabre wound in the right hypochondrium.

Chest.—Pericardium healthy. Heart rather large; but it was healthy, and its ventricles were contracted. Pleuræ healthy. Lungs large; their anterior halves were inflated, their posterior congested and œdematous. The bronchial tubes contained much muco-purulent fluid.

Abdomen.—On opening the abdominal cavity, the liver was found to be very large, extending down nearly to the umbilicus; the left lobe, which projected to the right of the mesial line, was firmly adherent to the abdominal parietes in front, and to the diaphragm above. The upper part of the great omentum also was attached, but less firmly, to the abdominal walls, and a portion of it was turned upwards over the left angle of the liver, and had become adherent. The incision before-mentioned, was made near the centre of that part of the liver which was united to the parietes, and turbid, purulent fluid escaped from it. Thick, purulent fluid also was discovered infiltrating the tissue of the upper part of the great omentum, and appeared to be connected with the free edge of the left hepatic lobe. The greater part of the peritoneal surface appeared quite healthy, and the general cavity contained no fluid. The diseased parts were removed in mass, and examined carefully.

The liver, as before stated, was large, and its left lobe occupied quite as large an area as its right. The serous membrane covering the whole of the right lobe, the lobulus Spigelii, and more or less of the outer margin of the left lobe, was perfectly healthy; but the greater part of the upper surface of the left lobe was adherent to the diaphragm, and to the abdominal parietes, and on cutting vertically through it, it was found to form the upper and anterior

wall of an exceedingly large abscess. This was evidently situated chiefly in the left lobe, was bounded laterally as well as above, by liver-structure, but below and behind by the lesser omentum, part of the anterior surface of the stomach, and by that portion of the great omentum which extended between the greater curvature of the stomach, and the abdominal walls to which it was attached.

The size of this abscess, it would be difficult to estimate correctly; it involved, at least, two-thirds of the enlarged left lobe, extended slightly into the right, and moreover occupied a portion of the peritoneal cavity, limited below by the stomach and omentum. All that portion of the wall of the abscess, which was formed by the liver, was covered by a lining of soft, flesh-coloured, flocculent, fibröid material, which was evidently the remains of the fibrous matrix of that portion of the organ which had been destroyed by suppuration. The material was so abundant, that it seemed almost to fill the cavity, and the contained pus chiefly occupied its interstices. There was no distinct line of demarcation between the abscess and the liver-structure around it; but in many parts the flocculent material acquiring greater and greater closeness of texture, became continuous with the liver-structure, which was infiltrated, more or less, with pus, yet presented in other respects a pretty healthy appearance.

Scattered throughout the rest of the left lobe, were a few small abscesses; and both in it, and in the right lobe, were numerous patches of suppurating tissue, the sectional surfaces of which varied from half an inch in diameter downwards. All these latter had a yellowish colour, which was most intense in the centre, but faded away towards the margins. In all of them the tissue was softened, and yielded pus on pressure, but presented more or less distinct evidences of healthy structure. A careful examination shewed that some of these deposits were isolated, but that others were arranged, more or less continuously, along the portal vessels.

The gall-bladder, the cystic, the common, and the hepatic ducts were healthy, and appeared to contain healthy bile. The ramifications of the ducts were traced throughout the substance of the liver, and were seen to be, for the most part, healthy. Several of considerable size, however, were traced on to the abscess, and

their walls, first thinned from without, and then ceasing by ragged, filmy ends, were found to open directly into it. The portal veins were, for the most part, healthy; but several branches were found opening directly into the abscess. Two or three of these, large enough to admit a No. 4 or 5 catheter, were examined closely; their parietes, like those of the ducts, were first infiltrated for half an inch or more with pus, so that the vessel appeared to be surrounded, for a short distance, by a quantity of suppurating tissue, from which it was separated by the thin lining membrane only; and then its walls ceased completely in a thin, shreddy film. These vessels, as far as their connection with the next large branches, were exceedingly pale, and one contained a small cylinder of pale yellow, opaque, and evidently pus-infiltrated coagulum. The hepatic arteries and veins appeared healthy. The liver-structure between the abscesses was generally healthy.

The stomach was rather large, and pushed backwards, and to the left. Its mucous membrane was perfectly healthy, and so also was its posterior external surface; but its anterior surface (in its right half), and that of the commencement of the duodenum, took part in the formation of the walls of the abscess. The mucous membrane of the duodenum, and of the small intestines, was healthy throughout. The serous surface of the cæcum, and of the ascending and descending portions of the colon was quite healthy. The transverse colon, concealed by the omentum, appeared, at first sight, to form a part of the walls of the abscess, for pus seemed to infiltrate the portion of the omentum which covered it, and that between it and the stomach. A careful examination, however, shewed that the surface of the colon itself was not yet implicated.

The whole length of the mucous membrane of the large intestine was thickly studded with ulcers. The disease was most advanced in the cæcum, and diminished gradually in intensity towards the rectum; yet, even in the rectum it was extensive. It presented the following characters:—The mucous surface, and especially its prominent folds, presented numerous ulcers, which had a tendency to take a transverse direction, and varied in their long diameter for one inch and a half downwards. The diseased patches or ulcers, consisted, for the most part, of thickenings

(from one quarter of an inch to one-third of an inch), of the mucous and sub-mucous tissues the surfaces of these thickenings to a considerable depth, being soft, livid, ashy, and evidently sloughy—the edges being formed by softened and sloughy mucous membrane. In a few cases, the sloughs had become broken up, and partially separated. In the descending colon, sigmöid flexure, and upper half of the rectum, the ulcers were fewer and smaller, and looked almost more like excoriations than ulcers of the same kind as those described above. The mucous membrane between the ulcers was very little congested, and there were no cicatrices, or other indications of disease, antecedent to that described above, which was itself evidently recent.

Spleen, pancreas, kidneys, supra-renal capsules, and aorta healthy. There was no scar in the peritoneum corresponding to the external sabre-scar, and it was quite clear that the wound had been simply a superficial one.

Remarks.—There can be no doubt that the large abscess in this case, was in progress of extension, that it was essentially recent and acute, and that it did not depend on portal or general pyæmia. The small abscesses scattered throughout the organ, however, were clearly of a different nature to the large abscess, and had originated in a different mode. Their numbers and dimensions suggested, even at first sight, their pyæmic origin; and that they were really due to purulent absorption, was strongly confirmed, if not absolutely proved, by the discovery of the orifices of ulcerated portal veins communicating freely with the large abscess, and by the fact of pus-infiltrated coagulum being found in one of the branches of the portal vein. The case shews, in an interesting manner, how a primary abscess in the liver may, by discharging its pus into the veins of the organ, produce pyæmia and its consequences.

CASE 3. *Empyema, Paracentesis. Abscesses of Liver. Dysentery. Incipient Phthisis.*

J. C., a sailor, æt. 40, was admitted on the 12th of July, 1853, having at that time been suffering for seven months from the complaint for which he sought advice. On admission, he was

found to be labouring under chronic pleurisy of the right side; and for this, during the five months he was in the Hospital, he was treated by various remedies, and tapped two or three times. Diarrhœa of a dysenteric character came on during the last three weeks of his life; and gradually sinking under the complication of diseases, he died on the 12th of December. I believe there was no reason during life to suspect the tubercular affection of the lungs, which had doubtless only developed itself in the course of his other maladies. Neither, I believe, was it suspected that abscesses existed in the liver, although there was a history of hepatic affection while the patient was abroad. The presence of empyema, however, of the right side, would be amply sufficient, to mask and even effectually conceal, an almost identical co-existent disease, in an organ so contiguous to the pleura as the liver.

Post-mortem examination. — Height, five feet nine inches. Weight, eight stone four pounds. Spare, but not much emaciated.

Abdomen.—On opening the abdomen, it was found to contain a little thin yellowish sero-purulent fluid; and a small quantity of soft lymph was spread over the surface of the liver, and that of most of the other organs. The transverse colon was slightly adherent to the liver, and on endeavouring to remove it, a large quantity of yellow, fœtid pus escaped; and a similar rush took place on lifting the liver from the stomach. The organs were removed together and examined with as much care as possible.

The liver was very large, and nearly its whole surface had a bluish-black colour; the exceptions being the lobulus Spigelii, and adjacent parts, which still retained a pale-yellowish hue. The under surface of the right lobe presented two circular patches between two and two and a half inches in diameter. The larger was in front and had adhered to the transverse colon, and after separation was occupied in the greater part of its extent by a ragged orifice communicating with a large liver-abscess. In the posterior patch the wall was exceedingly thin, and broke down almost as soon as touched. On the under surface of the left lobe was a ragged orifice, like that on the right side, but it was not more than an inch in diameter, and appeared to have been closed by slight adhesion to the stomach. On making a vertical section

through the right lobe of the liver, three abscesses were discovered each of which was nearly as large as the fist. They were filled with yellow, very fœtid pus, and their parietes were universally soft, ragged and flocculent. The anterior and posterior of these three were the ones that had been seen from without. The middle one was separated from the others, partly by the flocculent tissue already-mentioned, but essentially by walls of liver-structure about half an inch thick, and indurated, blackened, and otherwise altered. The liver-structure surrounding the abscesses on other sides, was of similar character. Two smaller abscesses, one as large as a pigeon's egg, the other as large as a chestnut, were discovered more deeply seated in the substance of this lobe. One presented in all respects similar characters to those just described; but the other, and that also in the left lobe were somewhat peculiar. They contained pus like that in the others, but the liver-structure around them, to a distance of half or three-quarters of an inch, was rendered exceedingly pale, and the lobules constituting it appeared to be separated more or less from one another by an extension of the suppurative inflammation between them. In none of the abscesses was any wall, or any approach to a wall consisting of dense fibrous tissue. The structure of the liver, except where blackened, was pale and clay-like, but apparently tolerably healthy—under the microscope the cells were found in a fatty condition, but not in an extreme state of degeneration. The ducts and vessels, so far as could be seen, were in a natural condition; but on tracing the right hepatic duct, it was found to open, about two inches from its junction with the left, into the middle one of the three large abscesses. The opening was large and patent, and the walls of the duct, rendered thin and ragged, terminated gradually. The gall-bladder was healthy, but full of bile, which was of moderate thickness, and of a light orange colour.

The large intestines were much diseased. The internal surface was so crowded with ulcers, that but little healthy mucous membrane existed between them. The ulcers varied from about a line to an inch in diameter; those from half an inch in diameter downwards were generally circular; those above that size irregular, and formed, perhaps, by the union of smaller ones. Those

of medium size had generally the following characters. The mucous membrane covering the patch was thickened, opaque and white, and adhered more strongly to the subjacent muscular tissue than did the surrounding healthier part. The central portions of these thickened patches presented a slate or blackish colour, were circular, and varied in their proportionate size, so that the margin of thickened and pale membrane around them was sometimes broad, and sometimes reduced to a very narrow rim. In most of the larger patches, and in many of those of intermediate size, the blackened portion was separated, or in process of separation, and the subjacent cellular tissue, or even the muscular coat itself was exposed. Where the sloughs had completely separated, the edges of the ulcers had in some cases the natural thickness and other characters of healthy mucous membrane, but in others, still retained a greater or less degree of thickening. The smaller ulcers (those of about a line or two in diameter) were somewhat different in character; they consisted of a tumid ring of white and adherent mucous membrane, surrounding a small cup-like depression, but in no case was a slough adherent to them, nor was it at all evident, that sloughs had separated from them. The disease was most advanced in the cæcum, and diminished towards the rectum.

The stomach and intestines were healthy, and none other of the abdominal viscera presented appearances worthy of remark.

Chest.—The right pleura contained rather more than two quarts of thin, yellow, purulent fluid. The surface of the membrane was universally covered by a thin deposit of pulpy, yellowish material which was evidently deposited from the fluid; and beneath this it was lined uniformly by a layer of adherent, tough lymph, measuring about half a line in thickness. The lung was compressed to the size of the fist, was of a slate colour, and tough, but slightly crepitant in the upper part. In its upper lobe were two or three small masses of drying-up tubercle. The left pleura was healthy. The left lung was voluminous, and in the greater part of its extent crepitant and healthy. It presented four tubercular cavities from the size of a filbert to that of a hazel-nut, of which two were situated in the apex of each lobe; and a few miliary tubercles were scattered throughout different parts of the

organ. The heart was healthy; but the pericardium presented numerous adhesions of not very old date.

Remarks (copied verbatim from what was appended originally to the post-mortem records).—The association of hepatic abscess with ulcerated intestines is interesting, and in this case probably accidental. The ulceration could scarcely have been produced by the flow of irritating bile into the intestines, since the whole of the small intestines were in a healthy condition. Neither could the ulcers in the intestines account for the abscesses in the liver, for the abscesses were probably of old date; the ulcers quite recent. The abscesses had the character of old abscesses, and there was also a history of the patient's having had hepatic affection whilst abroad. The ulcers were recent, for most of them were covered by sloughs, and even where the surfaces were raw, the sloughs had clearly only just separated. There was no evidence of old or chronic disease in the mucous membrane. And lastly, the history shewed that they had only existed for the last fortnight of life. The character of the ulceration closely resembled that seen in typhöid fever.

4. *Dysentery. Abscesses of Liver.*

R. F., a dock-labourer, æt. 46, was admitted on the 1st of September, 1857, having been ill four weeks with diarrhœa. While in the Hospital, the diarrhœa with vomiting continued, and he gradually sunk, and died on the 16th of September.

Post-mortem examination.—Height, five feet six inches. Weight, eight stone eleven pounds.

Abdomen.—Peritoneum for the most part healthy. The liver was large. Its structure generally was normally consistent, had a yellowish-brown hue and appeared healthy. The right half of its right lobe was attached to the diaphragm by not very firm adhesions; and in this half were two abscesses, each about half as large again as a duck's egg. One was situated towards the anterior edge, the other towards the posterior. Both approached the upper surface, projected in that direction, and were separated from the peritoneal cavity by a very thin layer. They were filled by yellowish-white curdy pus, and their internal parietes

were formed by a flocculent layer of soft and similarly coloured material. They appeared to have no proper walls, except this soft shreddy layer which separated them from the surrounding liver-structure. That portion of the latter which immediately bounded them, was somewhat softened and much congested. In the upper part of the left lobe was a yellowish, fibrinous mass about as large as a horse-bean, in the centre of which was a small irregular cavity containing pus. The vessels and ducts of the liver were healthy.

The large intestine was much diseased—the disease being situated chiefly in the cæcum, ascending colon, sigmöid flexure and rectum. In these portions of intestine, the diameter was much increased, the walls were from one-eighth to one-quarter of an inch in thickness, and the mucous membrane was extensively ulcerated and in a sloughy condition. The ulcers were large, varied in size, had a tendency to take a transverse direction, but communicated more or less with one another so as to leave between them a kind of imperfect network of mucous membrane. The surface of the ulcers was ragged and sloughy, and presented either an ashy hue or a more or less livid discolouration. The muscular coat was rarely displayed. The mucous membrane forming the network was much thickened, soft and somewhat pulpy; and the edges bounding the ulcers partook, in the characters which I have described, as belonging to the ulcerated surface. In many places the mucous membrane was undermined, and neighbouring ulcers communicated with one another beneath a cross band of mucous membrane. The tracts of tolerably healthy mucous membrane were studded somewhat sparely with small ulcers; some of which were round, others more or less elongated, but all situated on prominent folds, and more or less sloughy. The diseased intestine yielded a decidedly gangrenous odour. The muscular coat of the diseased portions of gut was thicker than natural and presented a succulent appearance.

All the remaining abdominal viscera, together with those of the chest, and the contents of the skull were perfectly healthy.

Dr. J. S. Bristowe, *20th of April*, 1858.

---

25. *Specimens of Syphilitic Disease of the Liver.*

There is no absolute proof that these specimens afford examples of the effects of syphilis on the liver, but the probabilities are all in favour of this being the case, both from the evidence contained in themselves, as well as that derived from comparing them with others. The difficulty in directly demonstrating the connection between syphilis and this peculiar affection of the liver and other organs is not from want of opportunity in examining a large number of patients in whom these appearances are likely to occur, but in the difficulty in obtaining a good history of their previous habits. Thus, the opinion in this country is still divided as to the effects of syphilis on the internal organs. Hitherto, the belief has been, that tertiary symptoms have been confined to the larynx, bones, etc., and a few other external parts, but of late, attention has been directed to the consequences of a specific influence on the internal organs, and there can be little doubt, that pulmonary affections, such as varieties of bronchitis and phthisis, are constantly met with in those who are subjects of inveterate syphilis, and several authors have alluded to hemiplegia occurring in the same class of patients, which they have attributed to nodes on the cranium, but as it (according to an improved pathology) cannot have such a cause, it is most probable, that the symptoms have arisen from a fibrinous deposit in the central parts of the brain or from a softening produced by disease of the blood-vessels. With regard to the deposit in the liver, one reason for its non-recognition has probably arisen from its association with lardaceous or waxy affection of the organ, for it is well known that the latter condition is constantly associated with disease of the bones and is a form of degeneration found in those cachectic persons who have long suffered from disease of the osseous system arising from syphilis or other causes. In such cases we have frequently observed fibröid nodules associated with this condition, but it was not until meeting with the instance given in the last Volume of these "Transactions,"* that the disease was clearly defined and the history perfect. Since that time, we have not met

* Vol. viii., p. 240, and Plate III.

with so good a case owing to the absence of history obtained during the patient's lifetime. The following three examples, however, afford strong probabilities that the changes found in the liver were due to syphilis.

CASE 1.—A man, æt. 43, came into Guy's Hospital with enlargement of the liver and spleen, together with ascites: he also had nodes on the legs, and marks of an eruption of the body. He stated, that six years before, he had syphilis, and had suffered ever since from rheumatic pains and eruptions on the skin; he had also been intemperate. In this case the kidneys, spleen, and liver were found enlarged and waxy or lardaceous. In the latter organ there was also a quantity of tough fibrous tissue interspersed with the other material. This spread through the organ in long branching filaments, and here and there was more concentrated, producing large round distinct nodules. The question arose at the time of examination, and may again recur, whether the intemperate habits of the man; being a recognized cause for fibrous change in the liver, were not the sole one in operation for its production. The objection is, that the fibrous tissue was not diffused as in cirrhosis, but collected into masses, and moreover, such explanation leaves untouched the cause of the waxy condition which undoubtedly must be attributed to a cachectic state induced by syphilis as already established. If, then, a constitutional cause was in operation to produce one condition of the liver, it is not too much to presume that the same cause induced the other. We leave the case, however, as an equivocal one, stating merely that such a condition of liver, a combination of waxy and fibrous degeneration, is constantly met with in the class of subjects of which this man was an example.

CASE 2.—A woman, æt. 27, was admitted into Guy's Hospital in a wretchedly cachectic condition. She was a woman of the very lowest character, but she was never interrogated as to syphilis. She had been ailing for several months, and when taken in, was found to be covered with scars as of an old ecthymatous rash, and had necrosis of the clavicle. She shortly died of peritonitis, when the kidneys and spleen were found enlarged and

waxy, and the liver contained a number of fibrous masses throughout its substance. These were white, hard, and composed of simple fibrous tissues and nucleated fibre, and were probably in an early stage of formation, as they were not so defined on their circumference as is usually seen. In this case, unfortunately, no history of syphilis was inquired for, but the probabilities are all in favour of this disease being the cause of the cachexia; any surgeon looking at the patient would, without hesitation, have considered it to be so. We cannot but attribute the changes in the viscera to a constitutional condition, and the waxy state of the organs has unquestionably such an origin, and therefore, probably the other morbid element associated with it. We believe, however, that the waxy or lardaceus change is due immediately to a cachectic condition in which the bones are involved, as the same is observed in scrofulous diseases of the osseous system. The true syphilitic product appears to be fibrous.

Case 3.—A married woman, æt. 33, came to the Hospital with a chronic laryngeal affection of several months standing. The breathing became so difficult, that at night tracheotomy was performed. She unfortunately died, and no history of syphilis was obtained. The larynx, on examination, was found to have a hard mass of fibrous tissue infiltrated into the sub-mucous tissue of the glottis, whereby the latter was closed by a hard lump which might almost be called a tumour. This was composed of very dense fibrous tissue, and the independent opinion of two surgeons unhesitatingly pronounced the disease to be syphilitic. On the front part of the liver was a large fibrous mass, which, by contracting the hepatic tissue around, had produced a cicatriform appearance of the surface. This mass, on being cut through, was found to be composed of a number of smaller nodules combined. These were of a yellowish-white colour, defined and tough.

Remarks.—It is to be regretted that better histories of the patients do not accompany these cases, and therefore opinions may differ as to the connection endeavoured to be established between syphilis and the appearances found. These facts, however, remain, that in cachectic persons long ill, such changes in the viscera as mentioned above, are constantly met with, and the question arises to what

is due to the constitutional vice producing them. We think the probabilities are all in favour of this being syphilis.

Dr. WILKS, *4th of May*, 1858.

Postscript.—In connection with these cases, see also case of supposed syphilitic disease of the lungs, liver, etc., among the diseases of the Respiratory Organs, in the present volume, page 55.

---

26. *On the Modes in which Hepatic Abscesses may be formed in connection with Disease of the various Systems of Tubes which ramify throughout the Liver.**

In a previous communication which I made to the Society, I shewed that the evidence derived from the *post-mortem* records preserved at St. Thomas's Hospital is, so far as it goes, totally opposed to the theory which makes abscess of the liver to depend, in the majority of cases, on intestinal ulceration. But I did not intend the remarks which I made on that occasion, to imply any disbelief on my part in the possibility of the suggested sequence, or indeed any doubt of its occasional occurrence; as will appear from a consideration of the facts presented by some of the cases I am about to adduce.

My special object, however, in the present paper, is to shew, from cases which have come under my own observation, how abscesses in the liver may be produced in connection with disease of the various systems of tubes which ramify throughout the substance of the organ.

In connection with the hepatic arteries. General pyæmia.

The occurrence of suppuration in the liver in the course of general pyæmia is a fact which has long been recognized, and one that sufficiently often receives confirmation in the dead house, to render it at the present day unquestionable. Yet it occurs much less frequently than has been generally supposed, and the abscesses themselves, though numerous, are rarely so large or well developed as those originating in other causes. Of this form of

* Several of the cases recorded in this paper are parallel to cases published in Dr. Budd's valuble work on "Diseases of the Liver."

hepatic abscess, the notes of five cases have been recorded during the last eight years.

In the first, pyæmia supervened on abscess of the prostate, and manifested itself in the lungs, kidney, cellular tissue of hand, and in liver, the abscesses in the latter being very small (case 1).

In the second, pyæmia was the consequence of diffuse cellular inflammation of the foot, and secondary deposits were found in the heart, lungs, liver, spleen, intestines, and kidneys. Those in the liver were numerous and minute.

In the third, it was produced by suppuration in one of the feet, and secondary abscesses were observed in the lungs, liver, and several other parts of the body. One of the hepatic abscesses is stated to have been large and diffused.

In the fourth, the abscesses of the liver, which were numerous and small, appeared to be the consequence of fracture of one of the ribs and pleural abscess.

In the fifth, the cause of pyæmia was not apparent, but the usual manifestations were present in the lung. There was a secondary abscess in one of the kidneys, and a minute one in the liver.

In almost all of these cases the secondary abscesses were in a very early stage of formation; and in the two, which were recorded by myself, and of which the details are minutely given, the depôts were small and circumscribed, and formed, for the most part, of a soft fibrinous material, which had, here and there only, softened into a puriform fluid. The depôts were moreover intermixed with, and frequently situated within, large, but circumscribed patches, in which the liver-structure was altered in colour, though not apparently in other respects. These patches were distinguished in some instances by pallor, in others by slight, yet marked congestion, and not infrequently, when pallid, were bounded by a halo of vascular injection. They possibly indicate, in the one case, the condition of congestion, in the other, that of effusion, which precede suppuration, or which surround it; and, though they may be in themselves unimportant, I have dwelt upon their description, partly because I believe they frequently accompany secondary hepatic abscesses, and partly

because I have observed them on two or three occasions in cases of pyæmia, when no other evidence of disease in the liver has been visible.

In connection with the Vena Portæ.—Although, as before remarked, I have never yet chanced to observe any case in which hepatic suppuration was caused by portal pyæmia, resulting either from intestinal disease, or from surgical operations in connection with any part of the bowels; I have, nevertheless, met with cases in which abscess of the liver resulted from portal pyæmia originating in other causes; and have noted other cases again, which, taken in combination with the last, indicate the possibility of hepatic abscesses being occasionally produced by intestinal affections.

The occurrence of portal phlebitis in dependence on intestinal disease is shewn in case 2, in which a chronic ulcer of the stomach was followed by suppurative inflammation of the entire thickness of the walls of the viscus, and of two or three tracts of the jejunum. This complication produced death; and at the *post-mortem examination*, fibrinous clots, containing distinct pus, were found in many of the branches of the portal vein. No abscesses, however, were discovered in any part of the liver; though it is clear that almost all the conditions which, in the present state of our knowledge are deemed necessary for their production, were present.

But the link in the chain of events, which is wanting in the above case, is furnished by others, in which portal pyæmia dependent on other causes produced hepatic abscesses. For example, in the case of C. H., recorded in my previous paper, there were, in addition to one large idiopathic hepatic abscess, numerous smaller ones, which were clearly produced by the conveyance of pus from the primary abscess along branches of the portal vein—a fact indicated; firstly, by the circumstance of several branches of the veins communicating freely with the large abscess; secondly, by some of the portal branches containing pus-infiltrated clots; and thirdly, by the secondary abscesses being, for the most part, distinctly situated along the portal vessels. It is possible, also, that some of the hepatic abscesses in case 4, were dependent on a similar cause.

In connection with the Hepatic Veins.—One is naturally led to suppose that the result of effusion of pus into branches of the hepatic vein, would lead directly to general pyæmia and its usual consequences. But of such a sequence I have no experience. It may, however, lead to the production of secondary abscesses in the liver itself, as is shewn in case 3. Here a large hepatic abscess had laid open some branches of the hepatic vein, and discharged a portion of its contents into them. That pus, which was effused into the proximal portion of the injured vein, became confined within it by adhesions, and thus general pyæmia was prevented. But that which was poured out into the distal ramifications, was forced along them in a direction opposite to that of the normal current of the blood, and thus produced a series of branching abscesses, which ultimately became irregularly dilated in consequence of partial destruction of the venous walls.

In consequence of Affections of the Ducts.—It is not unreasonable to imagine that abscess of the liver might be produced in connection with the ducts, on a similar principle to that explained in the last paragraph. Yet, no doubt, secondary abscesses rarely result from perforation of the ducts and effusion of pus into them, notwithstanding that perforation is common in the progress of both simple and hydatid abscesses. I have seen one case only in which I suspected this mode of production of secondary hepatic abscesses, but as it is very far from being a conclusive one, I have refrained from increasing the length of this paper by quoting it.

In case 4, the hepatic suppuration was a consequence of the complete obstruction of the common duct by a gall-stone. The hepatic ducts became dilated, their walls destroyed, and ultimately free communications were established with the trunk and branches of the portal vein, and even with the intestines. The biliary channels thus formed became enlarged at intervals into irregular cavities, some of which contained distinct pus, and the rest a mixture of the same with bile—the suppuration being probably due to the irritating effects of the retained bile on the attenuated duct-walls, and on the surface exposed by their destruction.

In the instance furnished by J. W. (case 5), the small abscesses secondary to an hydatid abscess were, as in the last case,

apparently the result of obstruction in the course of the duct which received its tributaries from that portion of the liver in which the suppurating points were observed. From the facts stated in the records of the case, there seems good reason to suppose that the distended hydatid abscess had compressed and obstructed the duct in question; that in consequence of this obstruction, a stasis of bile and destruction of tissue had supervened in some of the lobules; and that the lobules thus affected had ultimately acted as irritating foreign bodies and excited suppuration in the circumambient tissue.

Description of the various stages which are presented by Hepatic Abscesses.—When an abscess is in process of formation, we find the newly-affected lobules pale, more or less buff or straw-coloured, and somewhat softened—these changes being most marked towards the centre, and least distinct at the periphery, in which situation the diseased and the surrounding healthy structures usually merge insensibly one into the other, or are at most separated by a halo of congestion.

As the abscess extends, the parts in which the above changes have occurred break down. The liver-cells become separated, washed away from the fibrous net-work which binds them together, and destroyed—but the fibrous net-work itself persists for a time in the form of soft, loose, flocculent, pale flesh-coloured shreds, which, often in great abundance, hang from the parietes of the abscess into its cavity, and float in the purulent contents like confervæ in a stagnant pool. Occasionally, when the suppuration is extending with great rapidity, the disintegration of the cellular elements is effected to a considerable distance around the primary abscess before the newly-invaded portions become absorbed, as it were, into it; and in this case the fibröid tissue not merely forms a loose flocculent mass hanging into the cavity, but constitutes around the original abscess a series of pus-holding loculi, which communicate more or less freely with one another, and diminish in size as their distance from the abscess increases.

When the progressive enlargement of the abscess has become arrested, its parietes assume a different character. The primary abscess and its diverticula, by the breaking down and destruction of the flocculent tissue before-described, gradually form one dis-

tinct cavity. The walls then become tolerably smooth and lined by a thin layer of yellow opaque lymph, which separates the cavity from the possibly congested, yet not necessarily unhealthy liver-structure surrounding it. But the surface thus formed, though comparatively smooth, is not wholly so; for it generally presents a reticulated or ribbed or arborescent marking in relief, which appears to depend in some measure on inequalities of the subjacent liver-structure, and possibly in some cases (as the character of the surface seems to warrant) on the ramifications of vessels—an explanation, however, which my own experience does not confirm.

When the abscess has become quite stationary, and has passed into a chronic condition, its fibröid parietes become increased in thickness, and acquire a dense cartilage-like character; the inner surface remains tolerably smooth, and is, of course, in immediate contact with pus, or at all events with a sediment of mortary material deposited from that fluid in the course of time; but the outer surface is ill-defined and passes insensibly into the subjacent hepatic structure, which itself for some little distance around presents a greater or less degree of induration.

1. *Pyæmic Abscesses in the Liver.*

P. F., a shoemaker, æt. 50, was admitted on the 14th of February, 1853, labouring under suppuration of the prostate and vesiculæ seminales, and he died on the 27th of the same month. At the *post-mortem examination* was discovered extensive suppuration of the prostate and vesiculæ seminales, together with numerous abscesses (the result of pyæmia) in various parts of the body. Secondary abscesses were observed in the lungs, kidneys, liver, and cellular tissue of the hand.

The liver was of usual size, its capsule smooth and transparent. Its surface, which in the greater part of its extent presented an ordinary, but rather pale liver-colour, was mapped out by large irregular patches from three or four square inches in area downwards. The greater number and the larger of these patches had a light port-wine hue, produced apparently by local and well-defined, though slight congestion; but some of the smaller pre-

sented a very pale-clay colour. At the anterior edge of the right lobe were numerous well-defined, circular straw-coloured patches between one and two lines in diameter.

On section, appearances similar to the above were remarked pervading the substance of the organ; both congested and anæmic patches extended to various and often considerable distances into the liver, and had a distinct outline, though appearing to differ in colour only from the surrounding normal liver-structure; and it was found (a fact only slightly indicated by the superficial view) that the whole extent of the liver presented numerous small defined deposits of a pale straw-colour, clearly fibrinous, but not infrequently softened into pus.

2. *Chronic Ulcer of Stomach, Suppuration, Inflammation of the Stomach and Jejunum; Pus in the Portal Veins.*

T. M., a labourer, æt. 46, was admitted under Dr. Peacock on the 9th of January, 1858. He stated that he had been intemperate, and was in the Hospital eighteen months ago for a similar complaint to the present. His present illness has lasted continuously eight months; during which time he has complained of severe pain in the region of the stomach, increased by lying on the back and especially by food; and often followed and relieved by vomiting. The bowels have been much constipated, and he has become feeble and emaciated. He continued in the condition described above until the night of the 26th, when he was seized suddenly with intense abdominal pain, became rapidly collapsed, and vomited a large quantity of coffee-ground fluid. Soon after a further quantity was brought off by voluntary vomiting; and a little later he retched up a small quantity of blood. He continued in the same collapsed state, with cold extremities, imperceptible pulse, and complaining much of thirst, until the 29th, when he died.

Post-mortem examination.—Somewhat emaciated. Thoracic viscera all healthy.

Abdomen.—On laying open the abdomen, the peritoneum was found slightly congested; three or four ounces of purulent fluid were discovered in the pelvis, and a little lymph was observed

here and there on the surface of the viscera. The liver was invested in the greater part of its extent, and was slightly attached to surrounding parts. It was of usual size, and on section, appeared perfectly healthy. The ducts and the hepatic arteries and veins were also healthy; but on laying open the two first divisions of the portal vein and their branches, for a distance of about three inches from the point of bifurcation of the trunk, they were found to be filled, for the most part, by a series of imperfectly cylindrical clots, which were either not adherent, or very slightly adherent at points to the parietes. Those seated in the two primary branches were continuous with one another, and with a similar one prolonged a little way into the portal trunk, and were nearly as thick as the little finger; those which extended into the secondary branches, varied between the size of a goose's, and that of a crow's quill, and after a course of one or two inches, terminated in abruptly-rounded or tapering, extremities to which, in several instances, were attached small bands of ordinary *post-mortem* coagulum. The clots here spoken of, were soft and somewhat flaccid; had, for the most part, a brownish-red, mottled hue; and in some places were almost buff-coloured. On section, the larger ones were found to be filled with a brick-red, pulpy fluid, the transition between which and the comparatively firm parietes was gradual. The parietes of the smaller ones were somewhat firmer than those of the larger ones, and their interior presented less a continuous channel than a series of cavities, containing in some instances sanious, in others, buff-coloured, purulent fluid. Two or three branching coagula, about an inch long, and similar to the above, were found isolated in some of the smaller branches of the portal vein, but generally the portal veins were empty, or contained only a little fluid blood. The walls of the vessels were perfectly healthy throughout.

The stomach presented its normal shape, but was very much enlarged. A little lymph was deposited here and there on its posterior surface, and most abundantly in the position of the smaller curvature; but its anterior surface, in a space equal to that of the open hand, presented a yellowish hue, and a peculiarly reticulated, uneven appearance—the reticulation forming promi-

nent arborescent markings of considerable size, rounded and smooth on the surface, and suggesting the idea of their being large, thin-walled, varicose, pus-containing vessels. On a more careful examination, however, it was found that all the changes were due to a thick layer of soft, opaque lymph, attached to the serous surface, and that the vessel-like appearance depended on accumulations of pus in the substance of the false membrane. On opening the stomach, it was found to be filled by a large quantity of thin yellowish fluid. Its cardiac and pyloric orifices were healthy, but immediately behind the latter, and within half an inch of it, was a large, oval, chronic ulcer, which measured about two inches from above downwards, and about an inch and a half from side to side. Its left margin was overhanging and undermined, yet rounded; its upper, and a portion of its right lip presented a slight involution of the mucous membrane; but the remainder of the edge was bevelled off, more or less distinctly at the expense of the mucous and muscular coats. The ulcer varied in depth; it was quite shallow near the pylorus, and increased to about three quarters of an inch in depth towards the opposite side, where the excavation was deepest. The floor was generally smooth and evidently cicatrized; but that portion which was most depressed, presented several small, hemispherical elevations which turned out to be portions of the pancreas, and though it was smooth in other respects, it was discoloured, and appeared to be involved in the recent inflammation. A large portion of the mucous surface, corresponding very nearly in position and size with the peritoneal area of inflammation, presented a dirty yellowish hue, mottled with dusky and livid patches, and in several places exhibited small excoriations. This surface was more uniformly smooth than that of the healthy portion of mucous membrane, but was covered here and there with shreds of lymph. The parietes of the diseased portion of the stomach were considerably thickened, but did not appear to be infiltrated with anything of the nature of pus.

The duodenum and first three feet of the jejunum were perfectly healthy; but to these succeeded a portion, about a foot long, which was much diseased. The serous surface of the affected portion was deeply congested, and covered more or less completely

by soft, yellowish lymph. The mucous surface presented a dirty yellowish hue, and was remarkably tumid even up to its margins, which were abruptly separated from the contiguous healthy membrane. It appeared to be covered throughout by a layer of false membrane, which was firmly adherent to the subjacent surface, and could only be separated (and then to a very slight extent) at the margins. The valvulæ conniventes were very tumid, but folded on one another, and slightly adherent; and on separating them, the bottom of the depressions between them were found to be exceedingly pale, and occupied by distinctly purulent fluid. It appeared, therefore, that the inflammatory process had caused a deposit of lymph on the more prominent portions of the valvules (through the medium of which adhesions had been produced), while it had caused the formation of pus on the surface of those parts which had become separated by adhesions from the proper canal of the gut. The margins of the diseased tract were congested, as also were the free edges of the valvules. The parietes were much thickened, but did not appear to contain pus. About a foot below this patch, was a similar one as large as half-a-crown; and about half a foot below this was another, of precisely the same character, which measured three or four inches in length, and occupied the entire circumference of the intestine.

The remainder of the small intestines, and the whole of the large, were perfectly healthy, except that here and there a film of lymph adhered to the serous surface. Spleen, covered by a little lymph, but healthy. Pancreas healthy, except where involved in the ulcer of the stomach. Kidneys, and supra-renal capsules, aorta and vena cava and their branches, and mesenteric glands, all perfectly healthy.

Since the clots in the portal vein were not discovered, until after the removal of the liver and other viscera, the opportunity of thoroughly examining the portal system was lost. Still several of its branches were examined, and nothing abnormal was found in any of them.

Microscopic examination.—The fluid in the clots occupying the portal vessels, was found to contain distinct pus corpuscles. It might be objected that those in the brick-red coloured fluid, since they were intermingled with numerous blood corpuscles, were

nothing more than ordinary white cells. But this objection could scarcely be valid in the case of the pus-like fluid, contained in the imperfect loculi which occupied the smaller branches, since the fluid presented immense numbers of these bodies, with few or no blood corpuscles, and nothing else beyond a few granules. All these bodies were acted on in the usual way by acetic acid, the cell-walls becoming distended and the nucleus divided into two or three spherules. The substance of the liver was tolerably healthy; its cells presenting only a little more oil than usual, in the form of minute globules.

The pus-infiltrated lymph, covering the stomach and other parts in the abdomen, contained large numbers of bodies resembling pus; but, though probably really pus, they were not characteristically affected by acetic acid.

---

3. *Abscess of Liver, with Secondary Abscesses of the same Organ, due to Perforation of the Hepatic Veins.*

C. B., a coppersmith, æt. 30, was admitted on the 24th of May, 1853, and died in the beginning of the following July.

Post-mortem examination.—In good condition—lower extremities œdematous. There was recent deposit of lymph over the lower half of each pleura, and a few old adhesions at the apex of the left. The lower lobe of the right lung was collapsed, but in other respects the respiratory organs were healthy. Pericardium and heart healthy.

Abdomen.—On opening the abdomen, the liver was found very much enlarged, and the posterior half of its right lobe firmly attached to the diaphragm. Behind, and to the right, it contained a large globular abscess between six and eight inches in diameter, no part of which descended below the ribs. This contained a whey-like, slightly glairy fluid, together with a considerable quantity of opaque, greenish-yellow, stringy semi-fluid material which was connected with the parietes by a tolerably thick layer of almost putty-like substance. The immediate walls of the abscess consisted of a dense fibrous material between half a line, and two lines in thickness, the outer surface of which passed

gradually into the liver-structure around. In several places the abscess closely approached the surface, and the layer of healthy liver-structure which separated it from the diaphragm was not more than one-eighth of an inch thick. The liver independently of the abscess was much enlarged, and its tissue coarse and pale, the peripheral part of the lobules being comparatively dark and healthy, the central pale and fatty.

In the right half of the anterior portion of the right lobe, and in that part alone, were a considerable number of abscesses varying from mere points to an inch in diameter. Those of intermediate size were generally somewhat lobulated, as though formed by the union of several, or the branching out of one. In the same region with the abscesses, many branches of the hepatic vein were observed filled with more or less decolourized, adherent clots; many of which yielded a small quantity of puriform fluid on pressure, while some were filled with similar fluid.

On opening the vena cava opposite the hepatic vein, it was found that a large branch of the latter—the branch going to the right portion of the right lobe—was blocked up. Its orifice of communication with the cava, looked at first sight like the mouth of an abscess; it was covered in by a thin adherent layer, or as it were lid, of discoloured lymph, which projected towards the canal of the cava, and was so soft, that it became almost a question, whether a small tear, that was discovered, had not taken place during life. A little pus exuded through this orifice from the interior of the vein; and a small quantity of tough, yellowish lymph was attached to the walls of the cava in its neighbourhood. On tracing the vein into the liver, it was found to be filled with a mixture of lymph and pus; and, at an inch from its termination, to open abruptly into the cavity of the large abscess, or rather to cease abruptly, for its orifice of communication was completely blocked up by adherent lymph. Its walls, however, could be traced for a short distance branching on the parietes of the abscess.] Another, and smaller vein, passing from the cava into the liver in the direction of the abscess, had also its proximal extremity blocked up by adhesions of lymph, of which a little was prolonged on to the walls of the cava around it. Its canal was obliterated by cellular adhesions; it contained no pus, and was not traced into the abscess.

Having thus obtained an important clue, some of the smaller abscesses before-described were more carefully examined, and on tracing them, were in all cases found to be branching canals, which had the appearance only of being globular cavities by the accident of section, and were evidently branches of the hepatic vein, in which suppuration had taken place, belonging, doubtless, to that system of which the main trunk was the vein before-described, opening on the one hand into the cava, on the other into the abscess. In some cases (and these have been pointed out before) the walls of the veins were perfect, though thickened somewhat, and the canal contained a mixture of pus and coagulum. In other cases the walls had been completely destroyed, and the situation of the vein was occupied by an irregular pus-containing channel. One branch of the hepatic vein, about a quarter of an inch in diameter, was very carefully traced; it was filled partly with clots, and partly with pus; and was found to pass directly back to the abscess, where it ended abruptly; its orifice being completely blocked up by lymph.

The lining membrane of the portal vein was a little congested in places, and a few of its smaller branches were filled with coagulum, but nothing of the kind was observed in any of the larger ones, and none of them contained anything like pus. The gall-bladder, and the ducts, so far as could be ascertained, were healthy. The former was filled with light yellow-ochrey bile.

The stomach and intestines were quite healthy, and presented no trace of ulceration, and no cicatrix. The spleen, kidneys, and other abdominal viscera were healthy. The blood in the systemic veins and arteries was natural; and there were no softening clots in the heart. There were no indications of general pyæmia.

---

4. *Obstruction of the Common Duct by a Calculus; Dilatation, Suppuration, and Destruction of Hepatic Ducts; communication with Branches of Portal Vein and with Lung.*

M. S., æt. 32, was admitted on the 20th of April, 1852, and died on the 9th of June. She was suffering from intense jaundice, and other symptoms of hepatic disease; and shortly before death spat up bile-stained pus.

Post-mortem examination.—Of ordinary stature; in tolerably good condition; deeply jaundiced.

Chest.—Pericardium and heart healthy. Left pleura universally adherent; and the corresponding lung crepitant and perfectly healthy. There were a few adhesions at the posterior part of the right pleura, and the base of the lung was firmly attached to the diaphragm. The upper and middle lobes were healthy and crepitant; the lower was quite airless from collapse, tough, flabby, and slate-coloured. But on separating it from the diaphragm, it was found that the centre of its base, in an area of a couple of square inches, was superficially eroded and somewhat flocculent, and that this corresponded to a perforation in the diaphragm, and a cavity in the liver. The contents of the bronchial tubes connected with the lower lobe, consisted partly of biliary matter, and one tube was directly traced to its opening upon the ulcerated surface.

Abdomen.—The liver was adherent to all surrounding parts, but especially firmly to the diaphragm, the first part of the duodenum and the transverse colon. It was much larger than natural; and on section, was found to be filled with cavities of various sizes, the largest being about equal in dimensions to a hen's egg, but the great majority considerably smaller. These were not positive cavities lined by a cyst wall, but rather, indistinctly circumscribed portions of liver-structure, in which softening and rarefaction had taken place—their interior being formed, for the most part, of a flocculent, fibrous material which became more abundant and consistent towards the circumference, and thus blended insensibly with the surrounding healthier parts. Most of them presented a deep olive-green hue, and their interstices were filled with similarly coloured biliary fluid; others presented a lighter tint, and others again (more particularly the smaller ones) were filled with a thick, opaque, bile-stained, yet creamy fluid, which was evidently purulent. They were all more abundant in the right lobe than in the left. The liver-structure between the cavities varied in appearance; in some parts it had a uniform, pale-clay colour, shewing evidence, however, on close inspection, of the original lobules; in other places, it had the appearance of a network, from the circumstance of the margins of the lobules being deeply stained with blood. It was everywhere

soft, and on microscopic examination, shewed not a vestige of liver-cells, but was seen to consist entirely of fibrous tissue, intermingled with vast numbers of free oil globules of all sizes, and tinged more or less deeply by biliary matter, which, in some places, formed numerous irregular, bright-yellow concretions. The softened, olive-green coloured parts presented likewise, fibrous tissue and oil globules, but the biliary matter was much more abundant, and more thickly crowded with concrete masses; here and there too, groups of acicular crystals were observed. The largest cavity was situated on the convexity of the right lobe, and was that which communicated with the lung. It was about as large as a hen's egg; its contents were pulpy, and olive-green, and the amount of fluid contained in it was proportionately less than in most of the smaller ones, probably from having been expectorated. The diaphragm was firmly united to both liver and lung, and presented over the abscess, a large, ragged opening.

On the under surface of the liver, in the neighbourhood of the transverse fissure, was a cavity of considerable size formed partly, apparently, in the small omentum. It was bounded above by the transverse fissure, and below by the duodenum and colon; it was filled with biliary matter, and its parietes were highly discoloured and somewhat flocculent. Both duodenum and colon communicated with it by a ragged, ulcerated opening, capable of admitting the tip of the little finger.

The ductus communis was found, and traced from its orifice in the duodenum, to about as far as that point at which the cystic duct joins it, and then it appeared to lose itself in the cavity just mentioned, its walls becoming attenuated and flocculent, and finally disappearing. About an inch below this point, the duct was blocked up by a hard, globular, rough gall-stone, nearly as large as a small marble; but that the occlusion was not perfect was shewn by the fact that the duct immediately below the stone contained a trace of bile. The gall-bladder, which was situated in the upper boundary of the cavity, was very small, and contained only a little colourless mucus, its duct was traced for a short distance, and as far as it was traced was pervious, but after a very short course appeared to be lost on the walls of the cavity before spoken of.

On examing the transverse fissure it was very difficult, almost impossible, to recognize the parts usually found there. At first, I discovered a large tube, which I took to be the dilated duct, and laid open, tracing some of its branches into the left lobe. It contained masses of dark-coloured, soft, concrete biliary matter, and communicated through more than one orifice of considerable size with the cavity around it. I now tried to discover the vein and artery. The latter was soon found, and traced for a short distance, but of the former, I could find no traces; and it now struck me for the first time, that what I had assumed to be duct, was really vein and duct united. That the channels I had opened communicated with ducts was perfectly certain, from the bile and biliary concretions within them; and it was equally certain, that if the veins were not therewith connected, no portal vein whatever existed; and on more closely examining the tubes that had been cut into it was really found, that two different structures were involved. As the parts connected with the left lobe only had hitherto been dissected, and as some clue had now been obtained to the condition of things, the right lobe was dissected with considerable care. I traced into the right lobe a tube which was distinctly the right division of the portal vein; and found it dividing into two chief branches, one passing to the right, the other backwards. The one passing to the right after a short course, gave off several branches. One or two of these I traced and found healthy; but in another, I discovered that at one or two points its walls were thinned from without to such a degree, that the greenish tinge of the external tissues was distinctly evident though the patches of thinning, the largest of which was oval, and almost one-third of an inch long. Tracing the vessel still further, I found that in an oval space of considerable extent, it was perforated and communicated freely with a channel containing bile, the edge of the perforation being thin and shreddy; and that beyond the perforation, it contained a small cylinder of partially decolourized coagulum. Another vein, about as large as an ordinary quill, was traced from the same trunk as that just described. The walls of this presented a large perforation about an inch long, and nearly a quarter of an inch broad, and the portion which was prolonged from the further

pole of the orifice was so thin, that it formed merely a thin membrane shewing the liver-structure through it. Immediately beyond this it divided into two or three branches, which were filled with adherent coloured coagulum.

The chief branch passing backwards, gave merely an indication of its existence, it was prolonged for two or three lines only, and the walls gradually becoming thinner, finally lost themselves in an irregular biliary channel, which presented no parietes beyond those which were furnished by surrounding liver-structure in a softened condition. After tracing this channel, for an inch or an inch and a half, the remains of a vessel sending off several branches and extending to a considerable distance were discovered. It was laid open, and found to consist of a fibrous vein-like wall, a little more reticulated than usual, and presenting great irregularity from numerous thinnings and perforations. It contained no blood, and that end of its trunk which was towards the transverse fissure became gradually attenuated and lost. At first, I thought this a duct, but soon had no doubt of its being a vein, the continuation in fact of the former one.

After further investigation, veins were found and traced in other parts of the liver, presenting thinnings and perforations, or at intervals losing themselves; and accompanied by channels containing bile.

And now with respect to the ducts. There were found in the transverse fissure, in close proximity with the vein, and intimately connected with it, the remains of a tube of larger size than the vein, with an exceedingly thin membranous wall, the inner surface of which was reticulated. There could be no doubt, that this was the enlarged duct; yet although it gave an indication of dividing into branches, I could trace none of its divisions beyond the fissure. The walls got thinner and thinner, and disappeared, and the tubes became converted into large, irregular channels, which accompanied the veins, sometimes almost surrounding them, and frequently, as before-described, communicating freely with them. The walls of these channels were formed of broken-down liver-structure only. Their contents consisted of a good deal of biliary matter and numerous soft concretions. The channels presented occasional dilatations in their

course, and it was evident that the transverse sections of the diseased ducts, and more particularly of their sac-like enlargements, had produced some of those appearances, which in the earlier part of this account were described as being due to cavities.

The general cavity of the peritoneum, and the stomach and intestines, excepting in those situations where perforation had occurred, were healthy. The veins contributing to form the vena portæ were also healthy; but owing partly to the displacements and changes which had occurred in the lesser omentum, in consequence of the dilatation and giving way of the common hepatic duct, and partly to dissection having advanced to a considerable extent, and without reference to the portal system, before any suspicion as to the integrity of the portal vein was excited, the condition of fully two or three inches of the latter was, unfortunately, never ascertained, and therefore, whether the part in question was filled partially or completely by clot, or whether it was affected in any other way, or continued healthy, remains a mystery.

---

5. *Hydatid Abscess of Liver. Secondary Abscesses due to Obstruction of one of the Ducts.*

J. W., æt. 33, was admitted on the 25th of January, 1858, and died on the 6th of February, with symptoms of hepatic disease.

Post-mortem examination.—Much emaciated; slightly jaundiced. There was a little recent lymph on the diaphragmatic portion of the right pleura and on the opposed portion of lung. But both lungs were healthy, though presenting patches of collapse. The other thoracic organs were healthy; and so also were the brain and its membranes.

Abdomen.—On laying open the abdomen, the liver was found to be much enlarged, extending on the one hand high into the chest, on the other down to the umbilicus. The upper surface of the right lobe presented a few old adhesions. The left lobe, together with a small portion of the right, was dilated into a large fluctuating extremely thin-walled cyst, which was firmly united above to the diaphragm, below to the anterior surface of the

stomach, to the transverse colon and great omentum, and in front (in an area of eight or nine square inches) to the abdominal parietes. The cyst contained about three pints of thin, yellowish-white, sickly-smelling pus, in which floated numerous hydatids from the size of a pin's head upwards. One, which was of enormous size and ruptured, had probably originally filled the entire cavity. A few others were lacerated, but the majority were whole, though more or less collapsed. The hydatid-cyst had something of an hour-glass form, the larger division (situated in the left lobe and left anterior angle of the right lobe) being separated from the smaller (placed somewhat posteriorly in the substance of the adjoining portion of the right lobe) by a more or less distinctly-marked rim or valve-like projection. The left lobe was altogether occupied by the cysts, so that no portion of its original gland-structure remained, the walls which it formed being fibröid, and nowhere more than one or two lines thick. The portion extending into the right lobe was surrounded more or less completely by nearly healthy gland-structure. The internal surface of the cavity presented a very irregular appearance. In many parts it was covered by a tolerably smooth, buff-coloured, tough, albuminous layer, about a line in thickness; which had, no doubt, originally lined the entire cyst, but having been destroyed to a great extent by ulceration, formed irregular patches only, the margins of which were abrupt and sinuous and prolonged often into narrow bands. The intervening parts had a little of the rugous condition of the mucous membrane of the contracted stomach, and was covered by a thin, whitish, reticulated, fibrinous layer. The surface presented also, intermixed with the above, many toughish, adherent, irregular fragments of deep orange-coloured material.

Between the anterior wall of the above, and the abdominal parietes was an irregular, flattened abscess, perfectly distinct from the abdominal cavity. It was imperfectly sub-divided by strong fibrous septa, and was separated from the hydatid abscess by a thick, tough membrane, chiefly consisting of the walls of the latter, through which, however, a free communication was established between them by numerous perforations, varying from a line or two to an inch in diameter. The actual position of the

abscess was probably the sub-serous tissue between the peritoneum and abdominal muscles.

The left hepatic duct was very greatly dilated, and its mucous membrane exceedingly pale. After a course of about an inch, it opened by a circular orifice nearly an inch in diameter, into the posterior part of the hydatid cyst. No ulcerated margin, or other evident mark distinguished the lining membrane of the duct from that of the cysts, the two were as perfectly continuous as though the cyst had arisen in a mere dilatation of the duct. On the floor of the cyst, immediately in front of this, was a second orifice, nearly equally large, which opened into a canal, admitting the forefinger for nearly two inches beneath the lining of the cyst. On opening it, it was seen to be the continuation of the duct very greatly dilated, giving off numerous branches, all proportionably enlarged, and ramifying either as distinct canals immediately beneath the cyst-wall, or as open shallow channels upon the surface.

The right lobe was much increased in size, and was, in its posterior half, studded with small abscesses, from the size of a pea downwards, which, for the most part, presented tolerably smooth, at all events distinct, parietes, and were filled with dull-yellowish pus. A more minute examination of the sectional surface shewed several well-marked gradations in the formation of what I have above termed abscesses. 1st. In many situations, isolated lobules were seen, unaltered in consistence, but presenting a bright-yellow or orange-coloured margin, the breadth of which was about one-third that of the lobule itself, and a central spot of a deeper shade, but with little or no tinge of yellow. 2nd. In other cases, the altered lobules were surrounded by a pulpy, dull-yellowish zone, the diseased patch varying from about twice the diameter of a lobule downwards. The circumference of these spots was less abrupt, and lost itself more in the surrounding structures than that of the simply discoloured ones, and the central yellow mass was smaller, as though partially destroyed, and less distinctly a lobule; but from its comparative firmness it could easily be enucleated, though adherent by one or more points to the surrounding healthier tissue. 3rd. In other examples, again, the cavities were larger and more distinctly abscesses, but even in these, there was sometimes to be observed a

small, irregular, orange-coloured, spongy mass, projecting from some part of the parietes into the cavity.

On examining the orange-coloured, unsoftened lobules with the microscope, an entire absence of cell-formation was, for the most part, observed, a bright-yellow, granular, or amorphous mass, crowded in some parts with oil globules, usurping their place. The oil globules appeared to occupy chiefly the central darker coloured nucleus. The liver-cells that were occasionally detected, presented bright-yellow, transparent contents, and more or less oil. There were no traces of pus-cells. In the distinct abscesses, however, the pulpy, yellowish contents were found to consist entirely of densely aggregated cells, having all the characters of pus-cells. In the smaller ones, where a ring of pulpy softening surrounded a yellow, solid mass, the former was found to consist solely of pus-cells, the latter presented the same elements as the yellow lobules, previously-described, with the addition of a few pus-corpuscles.

Near the upper surface of the posterior part of the liver was a mass of softening, about as large as a filbert, which consisted of a dark-greenish, soft, filamentous mass, without any admixture of pus, and passed insensibly at its margins into the surrounding structures. It was just such a circumscribed patch of softening as is frequently produced by obstruction in the course of one of the hepatic ducts. Microscopically it presented no appearance of pus, but consisted chiefly of granular, and of concrete-biliary matter.

The structure of the right lobe generally, that is to say, all that which existed around and between the abscesses above-described, was somewhat congested, though otherwise healthy; and the cells here and there presented a little more oil than natural.

The gall-bladder, the cystic, common hepatic, and hepatic ducts, were of normal dimensions, healthy, and contained healthy-looking bile; and the ducts connected with the right lobe were in an equally normal condition. But a large branch of the right duct, passing directly backwards, though not dilated, ran closely by the side of the hydatid abscess, and must have been pressed upon by the abscess when in its distended condition. Now, the small softening and suppurating patches were all of them seated

in that region of the liver, with which this duct, by means of its ramifications, was connected. And since the small diseased patches differed essentially from those constituting ordinary secondary abscesses; since the successive stages were manifestly,—first, an alteration and breaking down of the tissue without suppuration, second, the supervention of suppuration around these disorganized spots, and third, the formation of a distinct abscess—my belief is, that these disorganised spots acted as irritating bodies provoking suppuration, and that, they themselves (not presenting any effusion of blood, any indication of inflammation, or anything, in fact, beyond simple degeneration) were the results of stasis of the bile in the ultimate tissue of the liver, dependent on the pressure of the hydatid abscess on the duct. This view is borne out to some extent by the presence in the same region of the liver, of a patch of that kind of greenish softening, which, so far as I know, is caused solely by obstruction to the flow of bile, and which, therefore, helps to demonstrate the assumed obstruction. I may add, that no affection of the portal vein was observed.

The general cavity of the peritoneum was healthy. The spleen was rather large, and its capsule thickened; but all the other viscera were in a natural condition.

Dr. J. S. Bristowe, 18*th of May*, 1858.

---

27. *Large Hydatid in the Liver.*

J. W., a lad æt. 12, was sent on the 11th of March, 1858, into the Marylebone Infirmary with scabies. He was observed to have a large tumour in right hypochondrium and epigastrium, but extending largely through neighbouring regions. On the 19th, he had an attack of epilepsy: none previously.

From this date to the 30th of April, when he died, the fits occurred almost daily, and the convulsions were very strong. He was insensible after each, for the last few days entirely so; often vomited, and the bowels were obstinately constipated.

He had been in the Infirmary two years before, but no sign of the tumour was then observed. All that could be learned of his history, as there were no relatives within reach, was that for some months he had complained of abdominal pain.

On the *post-mortem examination*, the liver was seen to be divided into two portions by a large fibrous cyst in its substance, within this is an acephalo-cyst almost filling the fibrous cyst, from which I evacuated twenty-two ounces of albuminous fluid; and one other smaller cyst, containing about two or three ounces. In the fluid contents were numerous echinococci and hooklets seen under the miscroscope. Mr. H. THOMPSON, 18*th of May*, 1858.

V.—DISEASES, ETC., OF THE GENITO-URINARY ORGANS.

1. *Two Calculi of Enormous Size, filling the Urinary Bladder.*

J. W., æt. 46, came under my care in October, 1856, with extreme pain in passing water, which he was compelled to do every ten or fifteen minutes, night and day. His symptoms were generally those of stone in the bladder in an aggravated form.

History.—He had a severe attack of fever at fifteen years of age, and after his recovery, first experienced difficulty in passing water, and much irritability of the bladder. These symptoms continued for many years, but his dread of surgical interference led him to bear his sufferings for a long time without seeking advice.

At thirty years of age, he first passed small fragments of gravel, and has continued to do so, frequently, ever since. At length, he made up his mind to take advice, and consulted among others, Sir Astley Cooper, who told him he had stone, and that an operation was necessary. However, he never permitted any one to sound him, and on the proposal to do so, sought another surgeon immediately.

When he came under my care, after much persuasion, I prevailed upon him to allow me to sound him, for the first time in his life. I found the prostatic urethra filled with fragments of calculus, through which the sound made its way, encountering a mass of calculous matter beyond. Further examinations proved this to be too large to remove by any operative measures, and he remained under my care for palliative treatment until his death,

which took place on the 4th of June, 1857. The small fragments, frequently passed, proved on an examination to be phosphatic.

Post-mortem examination. — On opening the abdomen, the bladder was felt as a hard mass rather larger than the fist, and apparently filled with solid material. Having removed it with the prostate and urethra entire, not without difficulty, for the bladder nearly filled the cavity of the pelvis, an incision made through its walls disclosed a large calculous mass, moulded to the form and size of the interior of the bladder. This proved, after removal, to consist of two hemispherical masses, nearly equal in size, and fitting or locking so closely to each other, as to form, as far as regards any means of extraction, one enormous calculus. A quantity of calculous fragments corresponding to those passed during life, were found blocking up the prostatic urethra and extending somewhat into some enlarged ducts there. The two masses fitted together, form a nearly spheröidal body, weighing, when first removed, fourteen ounces and a quarter, and after complete drying, twelve ounces. The longest circumference is ten inches and a half, the shortest, nine inches.

The composition is mixed; phosphates of magnesia and ammonia intervening in the form of deposits between a few layers of uric acid and urate of ammonia. After making section, it is obvious that the hemispherical form of each calculus is not due to the attrition of two ovöid bodies, but to fresh deposit around the adjacent margins of each.

The bladder was not much hypertrophied; the mucous membrane was somewhat inflamed, less so than might have been expected. But on its surface, there existed, throughout the greater part of its extent, a thin, tough, false membrane, rather adherent, but capable of being raised with care, which appeared to protect the more highly organized structure below.

Mr. Henry Thompson, *3rd of November*, 1857.

---

2. *Urinary Calculus adherent to the Bladder.*

This specimen of a urinary concretion adhering to the bladder, occurred in a woman, æt. 50, who died at the Middlesex Hospital, of cancer of the uterus and ovaries. She had suffered for

about two years from a severe uterine discharge, and during the last three or four months preceding her death, she was unable to leave her bed. No symptoms of a calculus in the bladder were noticed; but judging from the diseased condition of the uterus, it is probable, that the uterine pains obscured all other symptoms.

This little calculus consisted of a more or less flat scale, or lamina, about half an inch in diameter, situated at the base of the bladder, about an inch from the opening of the urethra. On lifting up its edges, the margins of the subjacent surface appeared rough and ulcerated, and minute shreds could be seen passing into the concretion; but it did not appear to be very firmly fixed. The free surface of this concretion was very crystalline, and resembled small crystals of brown sugar. The crystals were found to consist of oxalate of lime; but the phosphate of lime formed the chief part of the calculus.

Dr. Van der Byl, 17*th of November*, 1857.

---

3. *Urine containing Cystine.*

This specimen of cystine was first observed in the urine of a medical man, æt. 23, in good health, holding the office of House Surgeon to a provincial Infirmary, who had his attention directed to an unusual amount of sediment in his urine, at a time when, in addition to his ordinary Hospital duties (at all times rather arduous), he was occupied in reading for an examination. It was in sufficient quantity, when first noticed, to form a considerable sediment at the bottom of the vessel, and during the few days which the examination lasted, it was passed in less quantity than it had been the previous week. As soon as the examination was over, he went on a visit to the country for a week, and during this time there were mere microscopical traces of cystine; at the expiration of the week, he returned to London for a second examination, which lasted for three or four days, and during this time the sediment was again observed in the urine, in very considerable quantity, but after the termination of the second examination, the amount of it rapidly decreased, and one month later none could be detected.

The urine, when passed, was of the specific gravity of 1025, and

contained, in addition to the cystine, prismatic crystals of triple phosphate, octohedral crystals of oxalate of lime, both in large quantity; after standing for twenty-four hours, some few crystals of lactic acid could be detected. At the time this specimen was brought before the notice of the Society, there was every reason to believe that the presence of cystine in the urine was due to the mental and bodily fatigue under which the patient had laboured, and the quantity appeared to be in direct proportion to the amount of work done in the form of study, and Hospital duties, during the week's rest little or none being passed. It is necessary to add, that since that time he has again passed cystine in large quantity, but has not suffered from any derangement of health whatever.

Dr. B. Balding, *17th of November*, 1857.

---

4. *Enlargement of the Prostate, affecting mainly its Anterior, and only slightly its Lateral and Posterior Portions.*

History.—A gentleman in the country, æt. 65, had been suffering from difficult micturition for some months, and was visited by me on that account. I passed a middle-sized catheter into the bladder, relieving it of its contents, not without some little difficulty, which, although not precisely similar to that usually met with, was obviously caused by enlarged prostate, and the symptoms indicated the disease to be in an advanced stage. I saw him only once, but corresponded with his medical attendant until the time of his death, which occurred about five or six weeks afterwards.

On *post-mortem examination*, the prostate was carefully examined; about half of the enlarged anterior portion being sent up to London. The gentleman who made the post-mortem, described it thus:—"The tumour seemed, by as careful an examination as I could possibly make of the parts, *in situ*, to be entirely confined to the anterior or pubic portion of the vesical orifice, and to have its origin immediately under the pubic symphysis; . . . the tumour itself was the size of a hen's egg externally, irregular in shape from the presence of five or six nodular protuberances, similar to the two I have excised for your inspection." He thought at first, that the tumour was malignant in its character, but states,

that careful examination under the microscope afforded no ground for the confirmation of that view.

I found it to be clearly a specimen of tumours embedded in the substance of the prostate, of the kind very frequently met with; and which are made up, mainly, of the organic muscular fibres characteristic of prostatic structure, together with a small proportion of imperfectly formed glandular elements intermixed. Each was isolated by a capsule of fibrous tissue.

Enlargement confined to the anterior part is extremely rare, while the frequency with which undue development of the lateral lobes, or posterior portion (commonly called middle lobe) is familiar to all. Out of upwards of seventy specimens in the Museum of the College of Surgeons of enlargements of the prostate, only three exhibit a condition in which the part which lies anterior to the urethra is principally affected.

Mr. Henry Thompson, 1*st of December*, 1857.

---

5. *Three specimens of Fibrous Tumours of the Ovaries.*

By a reference to the last volume of the "Transactions," it will be seen that a variety of opinion was entertained with respect to the subject of fibrous tumours of the ovary in connection with a specimen exhibited by Mr. Nunn. It was considered that that preparation was a pedunculated tumour of the uterus, rather than of the ovary, not only for special anatomical reasons, but also on account of the supposed rarity of that class of disease, and from the presence of the peculiar microscopic fibres which were thought to belong especially to tumours of the uterus.

The *first* specimen now exhibited shews a large fibrous tumour of the ovary, weighing between two and three pounds, and resembling very closely the hard tumours of the uterus. It came from a woman, æt. 57, and occupied the left side of the abdomen, reaching as high as the hypochondrium; its duration of growth was unknown. It was formed by the left ovary, had a long peduncle, and was altogether free of the uterus, and had no adhesions with any surrounding parts, being smooth on the surface, and of an oval shape. It was cut through with some

difficulty, owing to its great hardness and density, and creaked under the knife. The incised surface presented the appearance seen in similar tumours of the uterus, being made up of fibres interlacing and curving in various directions, and disposed to the arrangement of concentric circles. In the midst of the tumour is a small mass which being softer than the surrounding parts, is vascular, and is probably the remains of the ovary itself; no characteristic structures can, however, be found in it, as it is quite changed into fibrous tissue. The latter, when examined by the microscope, is seen to be composed of simple white fibre, mixed with some nucleated fibre, and also the numerous long flattened bands which cannot be distinguished from the so-called muscular fibres of uterine tumours.

The *second* specimen is one lately sent to me by Mr. Burgess, of Glastonbury. It came from a woman, æt. 54, who, to the knowledge of her medical man, had had the tumour for ten years, her last labour being retarded by it. The tumour weighed three pounds, and involved the right ovary; it was attached merely by the broad ligament to the uterus, having no other connection with this organ. It was quite smooth on the surface, and of an oval form. Its structure is uniform throughout, being made up simply of fibre, and having a few nuclei apparent on treating it with acetic acid; no distinct fibrous bands are visible as in the preceding specimen.

The *third* specimen is one lately met with in Guy's Hospital. The patient was a woman, æt. 28, who had had several children, the last being three years of age. A twelvemonth before her death she became aware of the existence of some lumps in her abdomen; she died of pleurisy. The disease consists in a fibro-cystic tumour occupying both ovaries; each organ is about the size of an ostrich-egg, of an oval shape, and quite smooth on the surface. In both some cysts are seen, although the solid growth greatly preponderates over the fluid portions. In one, these cysts are few and small, but in the other is a cyst of some size. The tumour is hard, firm, and tough; when incised it exhibits a uniform white smooth surface, exuding only a little serum on pressure. The microscope shewed the structure to be very similar to that of the preceding specimens, and to consist of a simple fibre tissue, and,

therefore, an appropriate name for the tumour would be fibrous, rather than fibro-cellular, or fibro-plastic.

Although the elements of these three preparations so closely correspond, the external character of the tumours slightly differ, and thus they afford examples of the various grades of disease which the ovary may undergo. We may see in them the connection between a hard fibrous tumour and the simple cystic disease. We may have, in the first place, a multilocular cystic disease; then a similar disease with the addition of solid fibro-cellular growths between the sacs; thirdly, a disease made up of the same parts, but where the solid predominates, as in the last of the present specimens; fourthly, a uniform fibrous tumour, as in the second; and lastly, a hard dense fibrous growth, resembling the analogous tumour in the uterus, as exemplified in the first one. Dr. S. WILKS, *1st of December*, 1857.

Report of these Specimens.—CASE 1. The tumour comprising the *first* specimen under consideration, presented the density and elasticity of a uterine fibrous growth, and to the naked eye had precisely the same arrangement of its fibröid matrix.

Under the microscope it appeared to consist essentially of a kind of fibrous tissue, the fibres whereof ran, more or less distinctly, in bundles of various sizes, which interlaced with and crossed one another in all directions. The fibres were, for the most part, peculiar, and varied from about $\frac{1}{1500}$th of an inch in thickness downwards. The smaller ones were mere fibrils. The larger were refractive trabeculæ, with more or less distinct and numerous longitudinal markings, and occasional longitudinal fissures producing subdivision—with margins frequently sharp and definite, yet rarely entirely destitute of projecting shreds. Those of intermediate size, though still varying a good deal among themselves as regards dimensions, were generally refractive, at first sight homogeneous, with sharp, well-defined margins, and often (when projecting from a section) presented the same diameter in their entire length. A careful examination, however, shewed that they were all of essentially the same character as the larger fibres already-described, the tendency to fibrillation and other characteristics, being marked by their comparative smallness.

Acetic acid acted rapidly on the whole tissues, rendered the fibres perfectly transparent, caused them to swell considerably, effaced whatever markings they might have previously possessed, rendered them more or less cylindrical, and, at the same time, brought into view a large number of nuclei, scattered thickly and with tolerable uniformity throughout the entire matrix. The nuclei were ovöid and more or less elongated, but generally shorter, and thicker, and more irregular in shape than those of organic muscular fibres. In some situations they had a manifest tendency to run parallel to one another, but generally all uniformity of this kind was absent. They did not appear to be seated in the fibres; we never discovered any in those which projected from sections, and frequently, moreover, when bundles of longer fibres had been cut across and then acted on by acetic acid, the nuclei appeared to be distinctly situated in the meshes of the network which marked the intervals between the dilated fibres. As before stated, the fibres, and especially those of intermediate size, presented a remarkable appearance. Their sharp margins, homogeneous character, and generally uniform diameter, suggested the idea of their being elastic fibres, but the absence of the propensity to curl, and the effect of acetic acid upon them satisfactorily shewed that this view of their nature was incorrect. Their resemblance also to the muscular tissue of the uterus in an early stage of pregnancy was undoubted, and the abundance of nuclei shewn by acetic acid, lent probability to this hypothesis of their nature; but many considerations satisfied us of its incorrectness. Firstly, there was no uniformity in respect to the size of the different fibres, sometimes they were distinctly fibrillated; secondly, the margins were far too sharp for those of organic muscular fibres, while occasionally they were hairy; and thirdly, the nuclei had not the shape of those of muscular tissue, and were, as we believed, external to the fibres instead of within them. Our view, therefore, of the structure of the tumour is, that it was made up of a peculiar form of fibröid tissue, in connection with which were developed a considerable number of nuclei, but that there is no reason for believing that it contained organic muscular fibres.

The above growth in its general features so closely resembled uterine fibrous tumours, that, had there been the slightest room

for doubt, we should unhesitatingly have regarded it as such; its anatomical relations, however, distinctly and beyond all question proved that it was ovarian. Under these circumstances, therefore, we were anxious to ascertain whether the resemblance, which to the naked eye was exact, extended to the ultimate elements, of which the growth was composed; and, as may have been gathered from the preceding descriptions, it was discovered that there was a considerable resemblance even in this respect. After a very close and careful examination, however, we were unable to recognise the existence of muscular fibres, which, as we believe, constitute a large bulk of all uterine fibrous tumours. The presence or absence of these fibres would, of course, form a very important distinction, and if it should ultimately turn out that while constituting an essential element in uterine fibrous tumours, they are totally absent from those originating in the ovary, we shall have obtained a very valuable diagnostic mark by which to distinguish the two forms of growth from one another. Unfortunately, however, as is well known to all who are in the habit of examining the uterus and its fibrous tumours, there is extreme difficulty in isolating the muscular fibres in their undeveloped condition (as they exist in the unimpregnated female), and that difficulty is greatly enhanced when the parts become, as in elderly women, or from various causes, degenerated or atrophied; so that the fact of this not having been discovered in any single specimen, can scarcely be regarded as conclusive against their presence. And this view, therefore, with respect to the structure of the tumour under consideration, can be adopted only with the reservation here implied.

As the present case has a very distinct bearing on one brought before the Society last year, and more especially on a report which we presented upon that case; we feel that it would be scarcely right to omit pointing out how our examination of the present specimen modifies the arguments we then employed to establish views which were maintained by us. It may be recollected that the question to be decided was, whether a large growth connected with the womb was a pedunculated fibrous tumour of the uterus, or a fibrous tumour of the ovary; and that as arguments in favour of the former view (the view

which we adopted) we stated, "we are unacquainted with any ovarian fibrous growths which have attained anything like the dimensions of this body; there is no evidence whatever to shew that ovarian tumours contain muscular fibres; and we cannot understand how, if the tumours under consideration were ovarian, the opposite ovary and its Fallopian tube should spring from it." We are bound to admit that the facts of the present case, quite invalidate the first of the above arguments; and throw a strong suspicion on the second. But the third argument remains wholly untouched, and we repeat that the anatomical relations of the parts were quite sufficient in themselves to establish our view of the case.

Case 2. The tumours of the ovaries forming the *second* specimen were, for the most part, solid and tough, but loose and yielding in texture, homogeneous, and without any of the more salient features of uterine fibrous tumours. Moreover, certain portions of each presented all the usual characters of ovarian cystic growth.

Under the microscope they were seen to consist of fibröid tissue, in bands and bundles of various sizes, interlacing and communicating with one another in all directions, and in many places the larger bands had the wavy arrangement of ordinary fibrous tissue. Acetic acid rendered the whole transparent, and brought into view scarcely a trace of cellular or nuclear growth.

The walls of the cysts had the same structure as the solid tissue of the tumours; the only difference being that the fibres were arranged with greater regularity, and often appeared to form parallel bundles, a difference depending, probably, upon the stretching to which the parts had been subjected by the distension of the cysts by fluid.

The growths were, consequently, of a very different nature to that in the previous specimen, and had no resemblance to uterine fibrous tumours. The view which we took of them, is that previously communicated by Dr. Wilks, *viz.*, that they were of the same nature as ordinary cystic ovarian tumours, but that the intercystic or solid tissue had been developed in a far greater proportionate degree than usual.

Case 3. The tumours forming the *third* specimen are probably ovarian, but from the effects of the fluid in which they have been

DESCRIPTION OF PLATE IX.

Figure 1 represents the parts of Generation, in Dr. Sydney Jones's case of Enlarged Clitoris, p. 305.

Figure 2 illustrates the case of Cystic Tumour of the Cervix Uteri, removed by Mr. Spencer Wells, p. 333.

The anterior aspect of the tumour is represented, shewing the distorted cervical canal and the projection of cysts on its surface, covered by the injected mucous membrane.

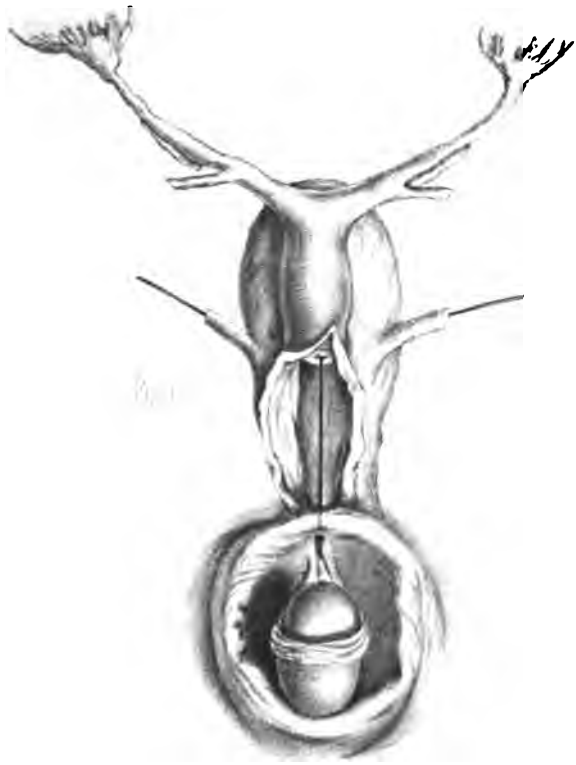

Fig 1

Fig 2

Tint from West Irth

W West x

attempted to be preserved, we cannot venture to give any opinion upon their nature.

J. S. Bristowe,
J. Hutchinson, 20*th of April*, 1858.

---

6. *Specimen of enlarged Clitoris.*

The preparation was taken from a child, æt. 6 weeks. The clitoris was about an inch in length (Plate IX. Fig. 1), and had a distinct glans and prepuce. From the extremity of the glans a groove ran backwards, an inch in length, to the orifice of the vagina. This groove presented three or four apertures, the orifices of mucous glands. Well-formed female organs were found on dissection. The urethra opened into the vagina just behind the anterior termination of the latter.

Dr. Sydney Jones, 15*th of December*, 1857.

---

7. *On the minute Anatomy of the so-called Fibrinous Deposits in the Kidneys.*

A careful examination of several specimens of fibrinous deposit in the kidneys, of which one or two were shewn to the Society, has afforded the following results.

1. The deposit when recent, is raised above the level of the surrounding renal tissue; it is firm, anæmic, with only here and there a coloured, vascular patch, but with an intensely red injected margin. The older deposits are softer than the surrounding tissue, appear shrunk and depressed, and have not the red margin.

2. On a microscopical examination (Plate X. Figs. 1-4), the uriniferous tubes in the seat of the deposit are found to have been rendered opaque by the abundance of their contents, as compared with the tubes in the other parts of the organ. Many of the tubes contain large quantities of oil.

3. Many of the inter-tubular capillaries contain granular coagula, and others contain oil globules, which are clustered in the form of rings, surrounding the tubes. Granular coagula and oil globules are also seen, though less frequently, in some of the

Malpighian capillaries, and in the arteries. The coagula in the vessels are best seen after the tissues have been made transparent by acetic acid.

4. The red zone surrounding the deposit, shews intensely injected Malpighian bodies and inter-tubular capillaries.

5. From these appearances, it seems evident that the morbid process in the kidney begins with the formation of coagula in the inter-tubular capillaries. In consequence of the blood stagnating there, the Malpighian capillaries become gorged, and pour an albumino-fibrinous effusion into the tubes, which renders them opaque. Subsequently the exudation, the epithelium of the tubes, and the fibrinous coagula in the blood-vessels, undergo a fatty transformation.

In some cases, the fatty transformation goes to the extent of destroying all trace of the natural structure. This had happened in a case recorded by Dr. John Ogle, in vol. vii. of the "Pathological Transactions," p. 177; and twelve years ago I made a note of a kidney in which there were several circumscribed patches of fatty degeneration; the tubular structure in these patches being nearly obliterated. The final result of the process is, that the part which is the seat of the deposit undergoes complete atrophy and absorption, and a fissure or cicatrix is left.

The intensely red margin of the recent deposit is explained by the engorgement of the Malpighian bodies, and inter-tubular capillaries, consequent on obstruction of those inter-tubular capillaries, which should receive the blood from the distended vessels. The morbid process appears to spread in a wave-like manner from a centre; an island of healthy tissue being occasionally found in the midst of the deposit.

While Rokitansky teaches that these deposits result from the coagulation of the blood within the vessels in the actual seat of deposit, Virchow, Kirks, and others, have explained the appearances in question, by supposing that fibrinous coagula from the valves of the heart, or other distant parts of the circulatory organs are mechanically arrested in passing through the minute vessels. There are insuperable objections to the latter theory so far as it relates to the kidney.

1. It is inconsistent with the fact, that the coagula are more

numerous in the inter-tubular capillaries, than in the Malpighian capillaries.

2. If the fibrinous coagula were so minute as to pass through the Malpighian capillaries before being arrested in the inter-tubular vessels, they must be so equally diffused through the blood of the renal artery, that they would be pretty evenly distributed over the whole kidney, and not in circumscribed patches.

3. Fibrinous coagula conveyed by the blood of the renal artery and plugging, as they would, the small arteries and the Malpighian capillaries before entering the inter-tubular vessels, would have the immediate effect of lessening, or entirely cutting off the supply of blood to the tubes. This obstruction of the arteries and Malpighian vessels would not give rise to that effusion into the uriniferous tubes, which renders the seat of the recent deposit firmer and more elevated than the surrounding parts, nor would it explain the red zone of injected vessels round the fibrinous patches. These phenomena are completely accounted for by the obstruction of the inter-tubular vessels, which results from the coagulation of their contents. Dr. G. JOHNSON, 15*th of December*, 1857.

---

8. *Tubercular Disease of the Testicle.*

This testicle was removed in the dissecting-room of the Westminster Hospital, from a man who was known to have had the organ affected for some months previous to his death. The whole testicle was considerably enlarged, but the epididymis was nearly twice its usual size, and when cut into, presented a curdy appearance; a small abscess was also present in its lower part. Spots of tubercular matter were scattered throughout the body of the gland. On microscopic examination, scarcely any normal structure could be found in the epididymis, and the seminal tubes in the body of the gland were irregularly dilated and apparently filled with tubercular matter.

Dr. Andrew Clark kindly made a further microscopic examination of the specimens and remarks:—"Of upwards of thirty specimens which I have studied, I have found none which illustrated more completely these two important truths respecting tubercular deposit in the testicle.

1. That the matter is produced in the first instance in the tubes, which are simultaneously thickened, and that it afterwards extends to the inter-tubular tissue by disintegration of the tube walls.

2. That the deposit has a different structure at different periods of its growth and at different parts of the same deposit. Thus, in the centre of a large deposit, the structure is chiefly granular; at the circumference, chiefly cellular.

There is a circumstance in this specimen which I have not recorded. Between those tubes in which the deposit is being produced, there are numerous free crystals of the triple phosphate. The relation of these crystals to the pathological process I have not determined."

Microscopic illustrations appended by Dr. A. Clark (Plate X. Figs. 5-8). Mr. C. HEATH, 15*th of December*, 1857.

---

9. *Extremely degenerated Kidney in Bright's Disease.*

These specimens came from a woman, æt. 50, who had been ailing some time, but had only been under notice a few months with œdema of legs, albuminous urine and other renal symptoms. The kidneys were remarkable for their extreme atrophy, one was much smaller than the other, and the two together weighed less than one ounce and a half.

Dr. WILKS, 15*th of December*, 1857.

---

10. *A Series of Eleven Uteri and Appendages, in which the majority had the Left Ovary placed at a greater distance from the Body of the Uterus, than the Right One.*

The right ovary in some of the specimens was placed at the greater distance; in one or two the distances were equal.

Mr. Nunn brought these specimens before the Society, doubting the pathological character of the peculiarities specified, but believing that certain pathological conditions and phenomena might possibly receive explanation from a knowledge of the fact of there being an inequality in the distances of the respective ovaries from the uterus.

DESCRIPTION OF PLATE X.

Figures 1 to 4 illustrate Dr. George Johnson's communication on Fibrinous Deposits in the Kidney, p. 305.

Fig. 1. Coagula in inter-tubular capillaries.

Fig. 2. Oil in inter-tubular capillaries.

Fig. 3. Coagula in Malpighian capillaries.

Fig. 4. Oil in uriniferous tube.

Figures 5 to 8 illustrate Dr. Andrew Clark's Examination of Mr. C. Heath's Specimens of Tubercular Disease of the Testicle, p. 308.

Fig. 5. Moderately healthy seminal tube.

Fig. 6. Tube with tubercular deposit, and embryo cyst.

Fig. 7. Elements of early tubercular deposit, disappearing on the application of acetic acid.

Fig. 8. Elements of advanced tubercular deposit, scarcely affected by acetic acid.

Figures 9 to 13 illustrate Dr. Bristowe's Observations on Microscopic Cysts of the Kidney, p. 310.

Fig. 9. Series of microscopic cysts.

Fig. 10. Free microscopic cysts.

Fig. 11. Waxy casts of cysts, to one of which a little epithelum adheres.

Fig. 12. Section containing transversely-cut denuded tubes and cysts.

Fig. 13. Cyst ruptured and discharging granular contents.

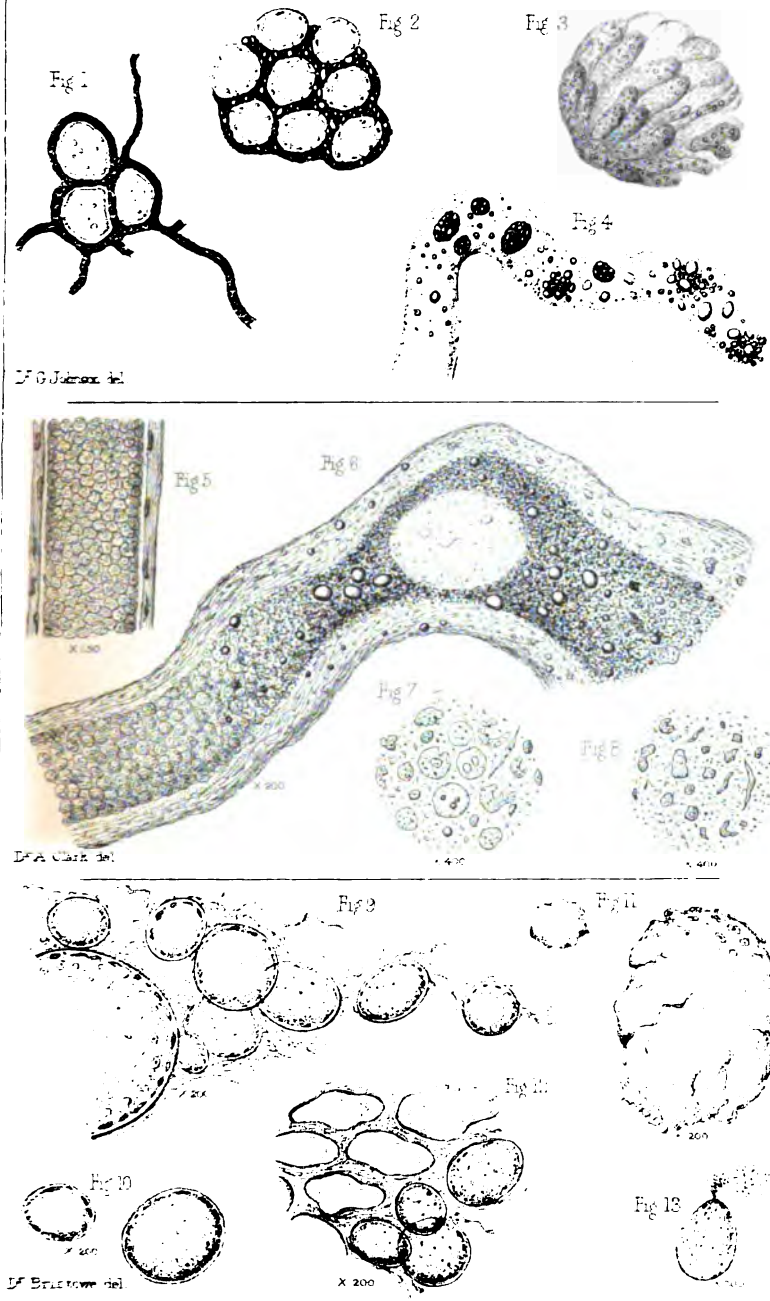
Fig 1
Fig 2
Fig 3
Fig 4
Fig 5
Fig 6
Fig 7
Fig 8
Fig 9
Fig 10
Fig 11
Fig 12
Fig 13
X 200
X 400

None of the works on Anatomy, as far as search has been made, contained any reference to the point, and the question appeared to be whether the left ovary has normally a longer ligament than the right one, in a manner analogous to the greater length of the left spermatic cord; or were certain of the specimens illustrations of the less perfect development of the left side of the body?

Mr. NUNN, *5th of January*, 1858.

---

11. *Diseased Kidney, with Observations upon Microscopic Cysts of the Kidney.*

The specimen of diseased kidney, on which the following remarks are founded, was brought under the notice of the Society in order to furnish an opportunity for certain gentlemen, who had expressed the wish, to investigate and report upon microscopic renal cysts. It was removed from the right lumbar region of a female, æt. 54, who had died from softening of the cord, consequent on fracture of the spine. It was of usual bulk, lobulated on the surface, and on section, found to be hollowed out into a series of cavities, varying in size between that of a filbert and that of a hazel-nut. The cavities, in some instances, presented a smooth, polished surface, and limpid contents; in some cases, they were filled with thick, white material, like moist, fine plaster of Paris; and a few contained small concretions. The cavities first mentioned, communicated freely with the pelvis, but the others formed distinct cysts. The secreting structure of the kidney was reduced to a nearly homogeneous, tough layer, from one-twelfth to one-sixth of an inch in thickness, which formed the partitions between adjoining cysts, and separated them from the capsule of the organ. The pelvis of the kidney was small, and its mucous membrane much thickened. The corresponding ureter also was much thickened and contracted, but pervious. It was clear that the morbid appearances were due to tubercular disease, and that the cysts which contained clear fluid were of the same nature as those containing mortar-like material, but differed in having opened into the pelvis, and discharged their contents. There was no tubercle or remnant of tubercle in any other organ; and indeed, the only other morbid conditions were a fatty state of the liver,

and a development of fibrous tumours in the walls of the uterus. The opposite kidney was healthy.

A close examination of the septa, between the renal cysts, shewed that they consisted of two distinct structures: — first, a tolerably thick fibröid layer, which formed the immediate parietes of the cysts; and second, a red, fleshy-looking substance, which existed generally in greater or less amount between the layers of fibröid tissue, and was especially abundant in the angular intervals, formed by their divergence. The latter material alone displayed the remains of renal elements—these elements being, 1st, matrix; 2nd, Malpighian bodies; 3rd, tubules, and 4th, microscopic cysts.

(1.) The fibröid matrix presented various degrees of density and distinctness. In those parts in which Malpighian bodies and cysts were numerous, it was rare and imperfect; in those in which the latter elements were sparse, it was developed to a great extent, consisted of interlacing fibres, and was permeated by vessels, but rarely presented any traces of those spaces which in a healthy kidney indicate the position of tubules.

(2.) The Malpighian bodies were tolerably abundant, but they were diminished to one-third or one-fourth of their normal diameter; presented thick refractive laminated capsules, sometimes studded or lined by granular earthy matter; and contained within them the atrophied and compressed tufts of vessels, in the form of nodulated refractive masses, which in profile, presented as usual somewhat of a pinnate arrangement.

(3.) Out of a very large number of microscopic sections, three or four tubules only were discovered, and these were empty, had exceedingly thin walls, and were reduced to one-fourth or one-sixth of their original breadth. The tubules, therefore, had almost wholly disappeared, and it seems probable that many of them, reduced to fibröid threads and bands, had become blended and incorporated with the fibröid parenchymatous tissue.

4. The cysts (Plate X. Fig. 9 and 10) were either scattered thinly throughout the fibröid matrix, or collected into clusters, more or less dense, and of greater or less extent. They varied in size from that of a healthy Malpighian body to that of a distended renal epithelial cell; though comparatively few exceeded

in diameter the transverse section of a large tubule. They were mostly globular or ovöid, but sometimes a little altered in shape by external pressure. They presented sharp, definite, even margins, and were evidently enveloped in a thin, structureless, membranous wall. Their contents were refractive, and occasionally presented, a little within the margins, one or more imperfect concentric markings. A few small oval or roundish nuclei were generally thinly scattered over the inner surface of the investing membrane; and in the case of the larger cysts, the corresponding region was in the recent condition occupied by a layer of beautifully distinct globular cells, about $\frac{1}{2000}$ of an inch in diameter; which, however, after the preparation had been placed in spirit, almost wholly disappeared. Under the application of pressure, the cysts, and especially the more bulky ones, were easily ruptured. The actual existence, and at the same time, the tenuity of their parietes, were then distinctly shewn; and their contents (Plate X. Fig. 11), were demonstrated to be a kind of homogeneous refractive jelly-like material, which retained more or less perfectly the shape of the cavity whence it had escaped, or the form impressed on it during its passage through the ruptured orifice. The casts were irregularly serrated or jagged at the margins, and frequently presented deep cracks or fissures; sometimes the epithelial lining of the cysts adhered to their surface. They resembled in fact the common waxy casts of tubes, except in their general form and, perhaps, in their consistence; and equally resembled, I believe, both in appearance and chemical constitution, the tenacious jelly-like or waxy material frequently observed in renal cysts of larger size.

It may be suggested that the appearances above-described were fallacious, and due really to sections of tubes. But that the interpretation which I have put upon them is correct, is manifest from several considerations. First, the bodies appeared uniformly globular or ovöid (Plate X. Fig. 12), and this, not in sections of tissue only, but when fragments were detached by scraping or tearing. Now, when transverse sections of series of renal tubes are obtained, the margins of the cut orifices are scarcely ever even, and rarely assume a geometrical form; moreover, from the fact of the tubes running in various directions, we find that

while the sections of some may be nearly oval or circular, those of others are irregular and elongated, and that generally at the margin unmistakable tubes of various lengths and with ragged ends may be recognised. Still less likely it is that portions detached from the surface of a kidney, by scraping, should present uniformly circular or oval orifices; and yet that must have been the case with the organ under consideration, not once or twice, but invariably, if the appearances described were due to divided tubes. I am not here maintaining that cut tubes can never be mistaken for cysts, but I am contending that it is impossible to confound a series of cut tubes with a series of cysts; and I may add that, by careful adjustment of the focus, one may almost always distinguish a sphere from a short cylinder, not only by the peculiar optical properties belonging to the former, but by the differences which the latter presents as successive planes are brought into view. Secondly, many of the cysts were observed isolated at the margins of microscopic specimens, and invariably in all points of view manifested a distinctly globular form. And further, numbers of them when detached by manipulation, were made to roll under the microscope, and still presented in every change of position the form of perfect spheres or ellipsöids.

The addition of acetic acid or liquor potassæ, rendered the cysts more distinct, from the fact that these re-agents produced little or no effect upon them, while they rendered the surrounding tissues transparent.

The description just given of the microscopic cysts in the case under consideration, corresponds, for the most part, pretty closely with observations which I have made on the same subject, at intervals during the last seven or eight years. I will, therefore, simply add to it the few additional facts which I have observed, and of which the notes I retain bear witness.

(A.) I have always been able to distinguish cysts from cut tubes, partly by the combination of differences above-described, and partly by the fact that liquor potassæ and acetic acid, which render the walls of healthy ducts transparent, have no effect on those of the minute cysts. I must allow, however, that when duct-walls are thickened and refractive, as sometimes occurs

in waxy kidneys, they are then no more affected by the re-agents alluded to than are the cyst-walls themselves.

(B.) I have over and over again detached these microscopic cysts under the microscope caused them to revolve, compressed and flattened them, and seen them as the pressure was removed, recover their original form. I have even ruptured them under my eye, and watched their contents escape (Plate X. Fig. 13).

(C.) Their parietes have always been exceedingly thin, and frequently, though not invariably, have presented a more or less distinct epithelial lining. The contents of some have been refractive and jelly-like, like those in the present case; those of others have consisted of a kind of nebulous fluid. Some cysts have contained minute oily-looking spherules; and some have presented such an abundance of oil-globules, as to give them all the characters of compound granule cells. In one case, I believe that many of the cysts contained altered blood, as did also some of the tubes.

(D.) I have always found the cysts most abundant in atrophied kidneys: for example, in contracted granular organs, in the atrophied state which results from hydro-nephrosis, or analogous causes, and in cases in which isolated tracts of tissue, shrunken from no apparent cause, exist in otherwise healthy glands. I have comparatively rarely found them associated with the larger cysts; and indeed, I think I may say unreservedly, that in the most extreme examples of microscopic-cystic disease which I have met with, larger cysts were not present; and on the other hand, that in the best-marked specimens of the large-cystic affection, microscopic cysts were not discovered. Whenever cysts have been abundant, the tubules have been more or less atrophied, and frequently wholly deficient or invisible. In fact, microscopic cysts and tubes have always appeared to hold an inverse proportion to one another.

Upon the origin of microscopic cysts, I fear I can throw but little light. It is clear, however, that they are developed in some way or other in connection with the tubes; for, as above-remarked, as the cysts increase in number, so the tubes diminish, and finally disappear. Further, it is equally clear, that the development of these bodies is connected with *atrophy* of the tubes; and since

they equally appear, whether the atrophy is dependent on extrinsic or on intrinsic causes, it may be fairly assumed that they are the result, and not the cause, of that atrophy. Still the question as to *how* they are produced in connection with atrophied tubes remains to be answered. And to this, two plausible solutions have suggested themselves to me; between which at present I am unable to decide. One is, that the cysts are developed from the tubes; the other, that the cysts are produced from the tube-contents.

1st. It is well known that, when tubules undergo atrophy, their canals become narrower and narrower, and their parietes thinner and thinner, until at length their remains are lost in the fibröid tissue which surrounds them; that, accompanying these changes are to be recognised—firstly, loss of the normal epithelial lining—secondly, effusion into the tubes of granular matter, or transparent waxy material—and thirdly, the disappearance (with the canal) of the contents which originally occupied the canal. Now it seems not improbable that in the course of the above processes, the obliteration of the tubules, instead of occurring simultaneously in their whole length, should occasionally take place at irregular intervals, leaving a series of ovöid cavities of unequal lengths, and thus producing an irregularly moniliform condition of the tubes. And it seems also not improbable that cysts thus produced, being essentially portions of tubes, should gradually accumulate within them some of those secretions, which were originally poured out into the tubes themselves, and thus become distended into globular bodies, the diameters of which would necessarily vary. The reasons in favour of this view are—firstly, that it accounts for the development of cysts in connection with atrophied kidneys—secondly, that it explains the apparent absence of tubules in the cystic portions—and thirdly, that it accords with the fact, that the cysts may contain all those varieties of contents which are found in diseased tubules. I may add, that their parietes being uninfluenced by acetic acid and liquor potassæ is not opposed to this view; for although the walls of healthy tubes are rendered transparent by these re-agents, those of thickened tubules are no more affected than those of the cysts; and I may add further, that neither is the invisibility of the ob-

literated portions of tubules between the cysts adverse, for if the atrophied lengths are excessively short, or if the atrophy be complete, it is scarcely to be expected that the portions alluded to should be recognised.

2nd. The other explanation is one that I fully believed in some few years ago, at a time when I was bestowing a large amount of time and labour on the investigation of microscopic cysts. It is, that these bodies are developed *within* denuded and atrophied tubules, and that they correspond to the fibrinous and waxy casts, which are commonly observed in the tubes in cases of Bright's disease. The opinion I entertained is, that the secretions constituting them being poured out less copiously and rapidly, or less uniformly then when casts become the result, assume before coagulating a globular or ovöid form, and that the outer surface, coagulating with greatest rapidity, becomes converted into a membrane before the interior loses its fluid character. The reasons which led me to this view are numerous. 1st. The contents of the cysts resembled those of tubes, being sometimes waxy, sometimes faintly granular, sometimes thickly studded with oil-globules, sometimes presenting an epithelial lining, and in one instance containing (to the best of my belief) disintegrated blood. 2ndly. In some cases, in which microscopic cysts were present, and in which waxy or granular casts, or both, were present at the same time, I had distinctly observed, both in the cortex and in the medulla, situated within tubules, linear series of casts, some elongated, some ovoid, and others globular, and so far as I could see identical with cysts. 3rdly. Although this kind of connection between cysts and tubes was certainly not satisfactorily shewn in the greater number of cases of extreme cystic disease of the cortex, still I believed that I had, even in such cases as these, occasionally seen the cysts and tubules distinctly occupying the relative positions referred to. 4thly. This view accounts equally with the former one for the presence of cysts in atrophied kidneys; and accounts, though somewhat less satisfactorily, for the apparent absence of the tubes.

Do the microscopic cysts above-described, produce the larger cysts visible to the naked eye? In answer to this question, I may recall what I have previously stated; namely, that though I have

occasionally observed microscopic cysts and larger cysts associated in the same organ, in most of the cases in which I have found the development of microscopic cyst extreme, there have been no traces of the larger cysts, and in most of the instances in which I have found an abundant formation of the larger cysts, I have detected no evidence whatever of the presence of the miscroscopic ones. Whence it seems scarcely fair to assume that there is any direct causal connection between them, or at least, that such connection can be anything more than occasional and exceptional.

Dr. Bristowe, *16th of February*, 1858.

---

12. *A large Hydrocele in the Right Groin; the Testicle being Undeveloped and detained in the Inguinal Canal.*

History.—A man, æt. 60, was admitted into the London Hospital, and died of pneumonia and chronic gastritis. It was supposed during life that he had a hernia on the right side, but the swelling was not subject to surgical examination in the Hospital.

On *post-mortem examination*, a large swelling was observed in the right groin, and the scrotum on that side was defective and contained no testicle. The swelling was found to consist of a large cyst, with thin walls, which projected from the inguinal canal, through the external ring, and mounted upwards on the aponeurosis of the external oblique muscle. A constriction in the sac corresponded to the external ring. On laying open the sac, the testicle was found in the part lodged in the inguinal canal. The gland with its epididymis was quite small, like the undeveloped testicle of a child, but it was free from adhesions and healthy in structure. The large cyst was the dilated tunica vaginalis; it contained about six ounces of serous fluid. It was slightly sacculated and had no communication with the peritoneum, though it extended up to the internal ring. The vas deferens extended over a portion of the walls of the cyst in its course to the epididymis.

The left testicle was situated in the scrotum. It was somewhat small, but sound in structure. Spermatozoa were detached in the fluid found in the ducts of its epididymis.

Mr. T. B. Curling, *2nd of March*, 1858.

13. *Undeveloped left Testicle, detained in the Groin, outside the Abdominal Ring; Hypertrophy of the Right Testicle.*

M. W., æt. 27, a prisoner in Carlisle Gaol, charged with incendiarism; a man of weak intellect, was apparently in good health until symptoms of intestinal obstruction occurred, which gradually increased up to the time of their fatal termination, at the end of eight days. It was observed during life that the left testicle was absent; there was no cicatrix in the scrotum, and he said that this was his natural condition. The intestinal obstruction was found to be caused by the ascending colon being twisted on its own axis, and death seemed to have immediately resulted from rupture below the seat of stricture.

After carefully laying open the inguinal canal, Mr. Page found the spermatic cord in its usual position, and on tracing it downwards through the external abdominal ring, he observed it to terminate about an inch and a half below that opening in a slightly bulbous extremity. On separating the elements of the cord, and tracing the vas deferens to its termination, it was found to end in a convoluted tube, which evidently represented the epididymis, and was continuous with an elongated glandular body, about an inch and a half long and as thick as a small crow-quill, which had, to the naked eye, a similar appearance to that of the healthy gland when divested of its fibrous-serous tunic. The duct was somewhat distended with a viscid milky fluid, which presented under the microscope fatty granules and non-nucleated granular cells. Surrounding the glandular process and termination of the tube was a sheath of loose fibro-cellular tissue, not at all approaching in firmness to the tunica albuginea, the outside being smooth, as if covered with an imperfectly developed serous membrane. The vas deferens and spermatic vessels preserved their natural relations and size until they reached their respective destinations. The vesicula seminalis was well developed and contained a fluid similar to that found in the duct near the testicle.

The vesicle of the right side was rather larger than that of the left, and contained spermatozoa. The right testicle, which appeared quite healthy, weighed one ounce and ninety-five grains.

Mr. Curling, for Mr. B. Page, *2nd of March*, 1858.

14. *An Ovarian Cyst which was tapped four years before the death of the Patient, and did not fill again until a week before her death. Enormous Elongation of the Fallopian Tubes. Great Dilatation of the Kidneys and Ureters consequent on the Pressure of the Cyst.*

M. T., æt. 40, was admitted into St. George's Hospital, on the 10th of February, 1858, suffering from slight jaundice, œdema of the legs, and extreme debility connected with long-continued privations. Her *history* was as follows:—Four years ago she was tapped for ovarian dropsy, forty-three pints of fluid were drawn off, a statement confirmed by Mr. Robinson, of Lisson Grove, by whom the operation was performed. Constant and severe pressure was applied over the cyst, which did not fill again, and she remained quite well up to seven months ago, when she began to suffer considerable privations. Shortly after this, abscesses formed in the axilla and she became weak and low.

Since that time, she had undergone several attacks of jaundice, and her health and strength had been gradually failing. Six weeks before admission, her legs became œdematous.

On admission into the Hospital, she was much emaciated, her complexion was pale and slightly jaundiced, and the lower extremities were slightly anasarcous. The abdomen was flat and flaccid, but nevertheless, a careful examination failed to discover any enlargement of the liver or gall-bladder, or to detect any fulness or hardness in the uterine region. The urine was abundant, did not contain albumen, and was passed freely. The catamenia were reported to have been absent only six weeks, but to have been scanty for many months. Her symptoms gradually increased; she took little to eat, and sank on the 22nd instant. Five days after her admission, a slight fulness was observed at the lower part of the abdomen. This rapidly increased, and four days before her death, fluctuation could be distinctly felt there.

On *post-mortem examination*, the *brain* was found healthy.

Heart.—Its valves and cavities were in a normal state, but its walls were thin, and its substance soft and pale, and the microscope shewed the muscular fibres to be in an advanced stage of

fatty degeneration, and discovered a large deposit of fat among the muscular fibres of the columnæ carneæ.

Pleuræ.—The right cavity contained a small quantity of clear serum; the left was quite healthy.

Lungs.—The left lung was healthy. In the apex of the right lung was a small cretaceous mass about the size of a pea, and the whole of the upper lobe of this lung was consolidated and apparently impermeable to air, sinking instantly in water. It resembled a portion of collapsed lung, and a microscopic examination failed to discover the slightest trace of morbid deposit. The bronchial tubes were remarkably contracted. The remaining portions of this lung were healthy.

Liver healthy.—The common bile-duct was occupied by two gall-stones which were firmly fixed there, but the duct was dilated, so that they did not prevent the passage of a probe into the intestines.

Spleen healthy.

Supra-renal capsules healthy.

The kidneys were extremely dilated, and their substance was compressed; so that they presented the appearance of large cysts covered by a thin crust of kidney-substance. The ureters were dilated throughout their whole extent to about the size of the little finger. They were quite pervious to their entrance into the bladder, but were adherent to, and compressed by, the pelvic portion of the ovarian cyst.

The *bladder* was healthy.

The calibre of the *intestines* was extremely small, the colon being smaller than the ileum is under ordinary circumstances, and the small intestine being no larger than a man's fore-finger.

The *uterus* appeared healthy.—The ovaries and Fallopian tubes must be described in connection with the ovarian cyst.

The *ovarian cyst* already alluded to, extended upwards a little higher than the umbilicus, occupying the lower portion of the abdominal cavity, and projected downwards into the pelvis, passing between the vagina and rectum to within two inches of the anus. It had contracted extensive adhesions with the surrounding viscera. Its walls were thick; it was partly filled, but not distended with greenish serum, and on its anterior surface, about two

inches below the umbilicus, it presented the mark of an old puncture. No division existed between the upper or abdominal and the lower or pelvic portions of the cyst. Both Fallopian tubes were expanded and elongated around the cyst, the left tube being drawn out to above a foot in length, and forming, together with the edge of the broad ligament, a projection on the surface of the cyst. The right Fallopian tube was also elongated and expanded round the cyst, but to a far less extent. No trace of the stroma of the left ovary could be discovered, and the only remains that could be found of the right ovary was a thin layer of dark-coloured tissue lying below the right Fallopian tube, adherent to the cyst and expanded by the pressure it had caused.

Remarks.—This case is very interesting. 1st, as affording an instance of an ovarian cyst, which for four years did not fill again after tapping. 2ndly, as shewing the extraordinary length to which the Fallopian tubes may be expanded. 3rdly, as proving to how great an extent the ovaries may be altered by disease and pressure without the total cessation of menstruation; and 4thly, as offering an example on a large scale of that condition of the lung, which is known as pulmonary collapse. But it is also interesting in another point of view. How is the extreme distension of the kidneys and ureters to be accounted for? obviously by the pressure of the cyst on the ureters. A careful examination was made to discover, whether some other obstruction to the flow of urine might not have existed, but none could be found. Therefore, as the ureters must surely have recovered, in great measure, their normal condition if no pressure had been made on them during the four years which had elapsed since the date of the tapping; the conclusion seems inevitable, that throughout that period, the lower or pelvic portion of the cyst must have been distended with fluid. And it is not a little remarkable, that during so long a period, one of those circumstances should not have arisen; either that the small quantity of fluid required to fill the pelvic portion of the cyst should not have been absorbed, or that a still larger quantity should not have been poured out, and the whole sac distended.

Dr. Fuller, *2nd of March*, 1858.

15. *Multi-locular Ovarian Cyst, successfully removed by Ovariotomy.*

The patient was a single woman, æt. 29. She had been a general servant, and was in good health up to the age of twenty-one. She then began to complain of pain in the left side, low down, extending to the loins; but she did not observe any tumour until three years and a half ago. The tumour increased gradually, and she was admitted into Guy's Hospital, under Dr. Lever, two years ago, and tapped. After six months she was re-admitted and tapped again; and a third time, after an interval of thirteen weeks. She went to Lambeth Workhouse in June, 1857, and was tapped there four times by Mr. Bullen, at intervals of about two months; the fluid discharged each time averaging about two gallons. Undiluted tincture of iodine was injected twice, but without the slightest benefit; on the contrary, the cyst appeared to re-fill faster than usual. She was admitted into the Samaritan Hospital, under Mr. Spencer Wells on the 9th of February, 1858; and, looking to her age, her moderately good constitution, her earnest desire to be relieved of a disease which made her life miserable, and the fact that her health was rapidly giving way under the repeated accumulation and discharge of two gallons of albuminous fluid, Mr. Wells decided, after consultation with his colleagues, to extirpate the tumour. The operation was performed on the 19th of February. Mr. Wells first made an exploratory incision in the linea alba, an inch below the umbilicus, down to the cyst, and emptied the principal cyst by a large trocar. The secondary cysts were not tapped, but the incision in the abdominal walls was enlarged to the length of seven inches. Very firm and extensive adhesions between the principal cyst and the abdominal parietes were broken down by the hand. A slighter adhesion to the omentum was also broken down. The peduncle was on the left side, and of the breadth of three fingers. It was transfixed in two places, and tied in three portions by whipcord-ligature. Mr. Wells was prepared to divide the peduncle with the écraseur, but he did not trust to this instrument in so large a peduncle. The peduncle was so short that it could not be fastened in the wound. The right ovary was

healthy. The ligature passed through the lower part of the wound, and was carefully fixed to the skin by plaster. The edges and sides of the wound were brought together carefully by deep and superficial sutures. The patient was under the influence of chloroform for forty minutes. She suffered from nausea and vomiting during the two following days; due, it appeared, rather to the chloroform than the operation; but she had no sign of peritonitis. She was kept from the first under the influence of opium, and wine was given freely. There was a very copious fœtid sero-purulent discharge from the abdomen, through the portions of incision kept open by the passage of the ligature on the peduncle. On two or three occasions, when this opening became plugged accidentally, the patient complained of a good deal of pain, and became feverish; but immediate relief was afforded by a free discharge of fluid after clearing the ligature. The wound united by first intention, except for about half an inch where the ligature passed. The bowels were not open until the tenth day, when they moved spontaneously. The ligature around the peduncle came away on the twelfth day, with a large slough attached to it. From this time the patient gradually improved.*

The cyst and contents weighed twenty-six pounds. The contents consisted of the ordinary viscid albuminous fluid, containing many granular cells. The lower part of the tumour consisted of a number of smaller cysts, which had completely filled, and been moulded in form by, the pelvic cavity. It appeared that most of the cysts had been developed independently of the principal cavity, and independently of each other. Small scattered cysts were observed in different parts of the largest cavity, but these were all developed in the substance of the fibrous wall and were covered by the serous layer lining the largest cyst. It was quite evident that, as there were strong fibrous partitions between the principal and the smaller cysts, the latter could not be reached by injection of iodine into the former. Hence the practical deduction that success could only be expected from iodine injections in uni-locular cysts. Mr. Spencer Wells, 16*th of March*, 1858.

* On the 12th of September, 1858.—She is now quite well, and has for some weeks past acted as servant-of-all-work in a family.

16. *Ovaries shewing False Corpora Lutea with commencing Cystic Disease; peculiar Crystalloid Bodies in the Colouring Matter of the Corpus Luteum.*

The specimen was taken from a woman, æt. 25, single, recently under the care of Dr. Chambers, in St. Mary's Hospital, and who died of pericarditis. She had never conceived, and the catamenia had been present, until within two months of her decease.

The ovaries were both of them about twice the natural size, an apparent increase in the size of the right ovary, being chiefly due to the presence of two cysts, one of which, as large as a walnut contained serous fluid, the other, the size of a nut, was distended with semi-coagulated blood. Both were evidently pathologically altered Graafian follicles. Both ovaries contained false copora lutea in various stages of transformation; and a number (about sixteen or twenty in each ovary) of Graafian follicles not yet arrived at maturity, varying in size from a pin's head to a pea. The more recent of the corpora lutea, one-third of an inch in length, were composed of a light-yellow dense structure, one-tenth of an inch in thickness, surrounding a cavity, which cavity contained what appeared to be a cyst. The opposite walls of this cyst were in apposition, but the cyst could be spread out, and might, to all appearance, have been separated with one, two, or more layers. The adhesion of the opposite walls of the cyst, and between the exterior of the cyst and the border of the colouring-matter were not firm in the four or five corpora lutea now alluded to, and the cyst could be easily turned out. The corpora lutea in question, were close to the surface of the ovary, and on the surface corresponding to them, distinct cicatrices were evident. The colouring-matter was light-yellow in those just referred to, but in older corpora lutea the colour was deeper, and in some a bright red. Sections of the portions presenting colouring-matter in the more recent corpora lutea shewed, under the microscope, that the matter in question was composed of fat, together with peculiar crystallized bodies, to be presently alluded to. On careful examination, no distinct membrane bounding the yellow colouring-matter, and separating it from the ovarian stroma could be detected, the colouring-matter, more thickly and profusely de-

posited close to the internal margin, shaded off gradually into the stroma of the ovary.

Dr. Graily Hewitt considered the observation important in a medico-legal point of view. Dr. Montgomery, in the last edition of his work on "The Signs and Symptoms of Pregnancy," states, as one of the marks diagnostic of false from true corpora lutea, that the false corpora lutea "are formed within the cavity of the Graafian vesicle, and consequently, never present either the central cavity lined by a distinct membrane, as does the corpus luteum of pregnancy, or the radiated or stelliform white line which results from its closure." In the corpora lutea described

LIGN. 8.

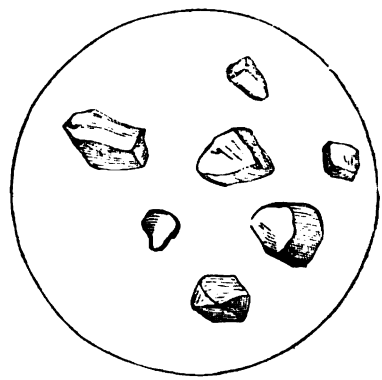

This figure represents the peculiar crystallöid bodies from the yellow matter of false corpora lutea.

by Dr. Hewitt, this central cavity was quite distinct, and as distinctly it was lined by what might easily have been taken to be a membrane. It is, therefore, evident that this point of supposed difference cannot be relied on. Whether the cyst or membrane present within the cavity, was an altered blood coagulum, (as every substance discovered within the colouring-matter is considered to be, by some good authorities), or that the membrane was the Graafian vesicle itself, or a portion thereof, it was not easy to determine. In connection with the question of the

seat of the coloured deposit in corpora lutea generally, the microscopic examination in this case failed to shew any limiting membrane between it and the stroma of the ovary, and together with the presence of the membrane or cyst, internal to the layer of colouring-matter, appeared to indicate that the yellow deposit in question had its seat in the proper surrounding stroma of the ovary.

The crystallöid bodies present in the colouring-matter, (see Lign 8,) were variable in shape and outline; they were colourless, and did not resemble any crystals which the author had seen depicted in the various standard works. It is probable that they were crystals originating in blood-transformation and degeneration.

Dr. Graily Hewitt, 16*th of March*, 1858.

---

17. *Large Multi-locular Ovarian Tumour.*

The specimen was exhibited in a dried state, and therefore had somewhat shrunk from its original dimensions. It was oval in shape, measuring when shewn to the Society, twenty-six inches in longitudinal circumference, and twenty-three inches as to its lateral circumference. Its external surface was smooth and uniform, excepting in one or two places where the parietes of some of the small subdivisions of the cyst projected. Owing to incisions which had been made into the walls of the cyst, it was seen to contain a number of compartments varying in form and capacity. As many as sixteen or eighteen of these compartments could be counted, and portions of septa which had given way at some period, could also be seen indicating the previous existence of other subdivisions. In one or two portions of the walls calcareous matter existed. When recent, I found the above-mentioned numerous cavities to contain quantities of fluid of various kinds, some being clear, others mixed with blood or pus, and many containing much cholestearine.* The tumour had been formed in connection with the left ovary, and when seen at the post-mortem examination, *in situ*, its position and connections were very remarkable.

* This specimen exists in St. George's Hospital Museum, as o. 1, sub series xviii., series 44.

It passed upwards and backwards behind the great omentum and the stomach, and so appearing above the smaller curvature of that organ, elevated it considerably.

It had, as it were, dragged up the uterus into the abdominal cavity by means of the broad ligament with which it was connected, and which was greatly thickened, and owing to the traction exercised upon the uterus, that organ had quite lost its natural appearance, and had assumed, as it were, the form of an immense kidney-bean. It was also very indurated and had a fibrous elongated polypus attached to its inner surface. Moreover, in connection with the right broad ligament existed a very large cyst, which extended upwards in front of the abdominal viscera, and was composed of a firm fibrous membrane in places attaining to a quarter of an inch in thickness, having mucous fibrous granulations arising from its inner surface.

History.—The specimen was removed from the body of a woman, C. B., æt. 67, who died in St. George's Hospital. Two years previously she had been in the Hospital for what was considered ascites, and from which she then had suffered six months, having also had jaundice. The swelling in the abdomen had appeared to come on gradually, not making progress on one side more than the other. When admitted a second time, she had pains in the right side of the abdomen, being much troubled with flatus.

Afterwards, sickness and vomiting came on, and eventually, stercoraceous matter was found to a slight extent; she gradually sank and died. On *post-mortem examination* congestion of the various viscera were found, but nothing of moment in addition to the appearances within the abdomen before-related.

Dr. John W. Ogle, 16*th of March*, 1858.

---

18. *Enchondroma of the Testicle.*

The specimen in this case was the half of a testis, which had been removed by Mr. Hey, in the York Infirmary. It was an excellent example of cartilaginous disease; nodules of crisp, glistening cartilage, varying in size from a pea to a large hazelnut being interspersed throughout its structure. There were

also numerous small cysts, containing a clear, glairy fluid. The nodules of cartilage were perfectly distinct from each other, and the connective tissue was firm and fibrous, but well supplied with vessels. There were no parts at all resembling cancer in structure, nor could the proper tissue of the testis be recognized. I had, however, it must be stated, no opportunity of examining the other half of the organ.

The patient from whom it had been removed, was a man, æt. 43. He had only noticed the testicle to be increasing in bulk for about a year and a half prior to the operation, and as it had then attained the size of an adult fist, the growth had been rather rapid. His general health had continued good, and the weight of the tumour was his only inconvenience. The cord was healthy, and he recovered well after the operation.

Mr. Jonathan Hutchinson, *6th of April*, 1858.

---

19. *Recurrent Fibröid Tumour of the Uterus, with Growths of a similar character in the Pericardium, the Lungs, and in the Body of the Sixth Cervical Vertebra.*

The *history* of this patient extended over a period of six years and a quarter. I am indebted to the kindness of Dr. West, under whose care she was admitted into St. Bartholomew's Hospital, for the following particulars prior to the fatal issue.

When first seen, in October, 1852, she complained of having received a violent blow on the lower part of the back, during a menstrual period, in July of the same year. She was unmarried, æt. 22, and had enjoyed good health. She had menstruated since fourteen, the discharge recurring every three weeks, scanty in quantity, but unattended with pain. The blow was followed by frequent, abundant discharges of blood from the vagina, and in September, 1852, by pain referred to the loins and hypogastrium. To this was added a sense of bearing down, not aggravated by exertion, nor relieved by the recumbent posture. The discharge was habitually offensive, consisting sometimes of fluid blood, often mingled with large coagula, at other times, greenish and watery. On examination, the os uteri was found widely open. A polypus,

the size of a pigeon's egg, protruded, though the finger could not reach the point of its insertion. The hooked forceps were employed, and portions were torn away, but a large mass remained behind in the uterus.

Partly by repeated operations, partly by sloughing of portions of the growth, considerable fragments were from time to time removed. In all, six operations were performed up to March, 1853, by which time the uterus had contracted to a considerable extent, the sound passing three inches and a half, instead of four inches and a half, along its cavity. The fragments removed constantly presented the ordinary characters of recurrent fibröid tumour.

Though the os had now closed, the uterus was by no means reduced to its natural size. In spite of its laceration, and evulsion of portions, the surface of the growth always felt smooth, and it seemed to be reproduced with great rapidity. Its broad base forbade the application of a ligature.

On the whole, the patient was much relieved, and left the Hospital. In June she suffered from sudden and profuse hæmorrhage, portions of the tumour being discharged with this coagula. She was re-admitted in August. The enlarged uterus was now felt through the abdominal walls above the pubes. The os was dilated with sponge and lint, and portions of the growth, in all, about six drachms, were removed by operation. Muriated tincture of iron was thrice injected amongst its debris, but owing to the severe pain which resulted, this remedy had to be discontinued. Chloroform produced so much and such abiding sickness and depression, that it was not possible to have recourse to its use.

Her history for a time was but a repetition of that already given. A ninth and last operation was performed on the 20th February, 1854, but the growth was reproduced as rapidly as ever.

From this time to the year 1857, she was able to follow a sedentary occupation. She suffered from several attacks of hæmorrhage, one in May, 1856, proving very nearly fatal. The tumour could now be felt above the umbilicus, the abdomen measuring thirty-two inches and a half in circumference, and a lobulated, soft growth occupied the vagina, and was continuous with that which filled the interior of the womb.

Thus, for awhile she seemed to amend, in spite of the decided increase of the abdominal tumour. No considerable loss of blood occurred, though the abdomen remained extremely tender, and the patient continued pale as a marble statue.

On the 20th of December, 1857, she re-entered the Hospital for the last time, not suffering indeed from any return of her uterine symptoms, but from pain, which she conceived to be rheumatic, in her neck, and from cough, brought on from exposure to cold a week before.

Some swelling was perceptible on the right side of the cervical vertebræ, and light was thrown upon its probable nature in the course of a few days, by the occurrence of numbness of the right arm and leg, and difficulty in moving them. Next, power over the left arm and leg became similarly impaired, and the urine was voided involuntarily as well as unconsciously. The respiration, too, was laboured to an extent which auscultation did not account for. The strength daily declined, though without suffering, and death took place quickly on the 31st of January, 1858.

On the whole, the impression left on the mind was to the effect that the operations had in no way retarded the progress of the disease. Indeed, the reproductive power must have been extremely active after the removal of the various portions, for when the uterus was examined, shortly after an operation, the surface of the growth was found smooth and prominent, neither rough nor excavated, as might have been expected.

The body, examined after death, was greatly emaciated. The rigidity was well marked. On opening the abdomen, a large oval tumour was seen to occupy the left iliac fossa, extending upwards to the level of the left kidney, and having in front of it several coils of small intestine. This growth was surrounded by a thin, transparent, membrane, which, dipping into its substance divided the tumour into irregular lobes.

The tumour itself, was of a white, or pale straw-colour, and a few large blood-vessels ramifying over its surface, grew from the posterior wall of the uterus, to which it was connected by means of a base two inches and a half in breadth. From this the disease expanded, forming an oval mass, which measured five inches and a half in its chief diameter.

The uterus, lying free in the pelvis, occupied the entire cavity, and rose to some height above the level of its brim. Its walls, a quarter of an inch in thickness, were so stretched that it was difficult to distinguish where they ended, and where the walls of the vagina commenced. Thus attenuated, the uterus surrounded a large tumour, which filled its interior. A broad base attached this growth to the entire posterior wall, through the substance of which it was continuous with the mass which projected into the iliac fossa. Anteriorly, and at the sides, it was perfectly free. This tumour resembled in appearance the one already described. It was soft and elastic, but when portions were torn away, the line of fracture remained rough and irregular.

Independently of this principal growth, measuring seven inches and a half by five inches, a few isolated nodules were connected with the sides of the uterus, and projected, involving the mucous and sub-mucous coats, upon its inner aspect.

The lobed surface of the tumour was free from any irregularities, such as might have been expected as the result of the various operations, but the lobes, projecting into the vagina, were more marked on their anterior and lower portions than elsewhere. The mucous lining of the vagina was extremely pale.

These tumours were composed of the characteristic oat-shaped cells, freely mingled with others of a flattened fibröid form, each containing a single nucleus, having within it several clearly defined nucleoli. Septa formed of an imperfect fibrous material extended through all portions of the growths, and determined their lobulated character. They were as marked at the points most remote from, as at those directly continuous with the walls of the uterus.

Passing upwards from the pelvis, the lumbar glands were found to be infiltrated with the fibröid material, and were thus considerably enlarged. The bronchial glands though enlarged were simply laden with an abundance of pigment. The lungs were filled with nodular deposits, of various sizes, averaging half an inch in their diameter. Some of these were situated beneath the pleura, others more deeply in the pulmonary tissue. They originated in the division between adjacent lobules, and by their increase caused a condensation of the surrounding air-cells.

They resembled, in miniature, the larger tumours connected with the uterus; whilst, however, containing the fibröid cells, they were formed in greater part of those having the oat-shaped character. The parietal pericardium presented three nodules of a structure resembling the preceding; they grew from the fibrous layer, and thence projected into the sac.

It was evident that these growths were all of one and the same nature. Those in the lungs, to which the history pointed as of more recent and secondary formation, seemed, in the greater abundance of oat-shaped cells, as compared with those of a fibröid character, to be approaching more nearly to the nature of cancer formations. This remark applies equally to the tumour which remains to be described.

This growth, involved the body of the sixth cervical vertebra. Everywhere the outer wall of that bone was pushed irregularly before it, forming in front, a considerable nodulated prominence, behind, a less marked and smooth projection which encroached upon the spinal canal, and compressed the cord. On either side the tumour had made way through its bony envelope, involving the sixth transverse process, and projecting laterally through the fifth and sixth inter-vertebral foramina. At the last named points it involved, chiefly on the right side, the nerves which principally form the brachial plexus. The vertebral arteries passed through the lower part of the tumour, and the canal of the right was somewhat narrowed.

As already mentioned, the spinal cord was compressed by the expansion of the posterior wall of the body of the sixth vertebra, the antero-posterior diameter being lessened, chiefly upon the right side. Just above and below this portion, the cord bulged so as to fill the canal, the space between the membranes being obliterated. This change involved nearly half an inch in either direction, the cord gradually regaining its natural appearance. These variations were pretty accurately determined by measuring the antero-posterior diameter at the several points. Thus the diameter of the portion of the canal which had been removed, was found to average twelve-twentieths of an inch; the antero-posterior diameter of the cord at the point of pressure was six-twentieths of an inch on the right, and eight-twentieths on the

left side of the mesian line, and immediately above and below this part, the diameter increased to eleven-twentieths of an inch, whilst half an inch beyond, it measured rather less than ten-twentieths.

These differences were such as to attract immediate notice, especially when the parts were compared with a normal cord. The inference was, that the condensation of one portion had caused a compression of tissue towards the parts adjacent, and hence their bulging. Such a change could scarcely exist without interfering with the functions of the nerves connected with the cord above and below the point of compression. In the present instance it would account for the implication of all the nerves supplying the upper extremities, and would thus explain the symptoms which arose towards the close of the case, more especially the *complete* paralysis of the right arm.

The embarassed respiration, in part explained by the condition of the lungs, may have been determined by the implication of some part of the origin of the phrenic nerves in the changes which the cord had undergone. The other organs of the body presented a natural appearance.

Mr. George Callender, *6th of April*, 1858.

---

20. *Cystic Tumour of the Cervix Uteri, removed by the Écraseur.*

History.—The patient was married, æt. 43, mother of seven children. Her last confinement was in January, 1851. Nine days after it she travelled from Scotland to England, and began to suffer from symptoms of prolapse, which increased gradually until eighteen months before operation, the neck of the uterus fell external to the vulva. She suffered from extreme pain at the menstrual periods, and a troublesome profuse muco-purulent or sero-sanguinolent discharge between the periods. She complained of great tenderness and local uneasiness, sensations of weight and dragging, and there was notable derangement of the general health. She underwent a variety of treatment without benefit, and had been latterly for three months in one of our largest Hospitals. On her discharge, she was told that the disease was incurable, and that she would "bleed to death" if it were removed. She then applied to Mr. Spencer Wells, and was

DESCRIPTION OF PLATE XI.

Figures 1 to 3 illustrate the structure of Mr. Spencer Wells' Cystic Tumour of the Cervix Uteri, p. 333.

Fig. 1. Section of a portion of the tumour, shewing the arrangement of the cysts in the uterine tissue.

Fig. 2. Epithelial debris, with oil-globules and compound granule-cells found in the larger cysts.

Fig. 3. Glandular epithelium lining the younger cysts.

Figure 4 illustrates Mr. R. Taylor's case of Adhesion of the Retina to a Cicatrized Cornea, p. 363.

a. b. Two views of the eye in section.

Figures 5 and 6 illustrate Mr. Hulme's case of Malignant growth within the Eyeball, p. 365.

Fig. 5. Vertical section of the eyeball.

a. Morbid growth commencing at the entrance of the optic nerve, and destroying the retina.

b. Hyalöid and contained vitreous humours pushed forward towards

c. The clear lens.

Fig. 6. Microscopic structure of the growth.

a. Small ill-developed cells, of which the mass was chiefly composed.

b. Larger cells.

c. Earthy deposit, consisting chiefly of phosphate of lime.

d. Granular matter.

Figures 7 to 10 illustrate Mr. Mitchell Henry's case of Fibro-Plastic Tumour of the Humerus, with Myelöid Cells, p. 369.

Fig. 7. Myelöid cells from the original growth in the humerus.

*Fig. 8. Myelöid and other cells, from the softer portion of the tumour which returned in the shoulder.

* The drawing of these cells was made after the specimen had been mounted for several weeks, and the distinctive features somewhat lost.

Fig. 9 Fibrous structure, impregnated with calcareous matter, along with intervening cells. Osseous structure—from the tumour which formed in connection with the scapula, after removal of the humerus.

Fig. 10. Cells from the tumours in the lungs.

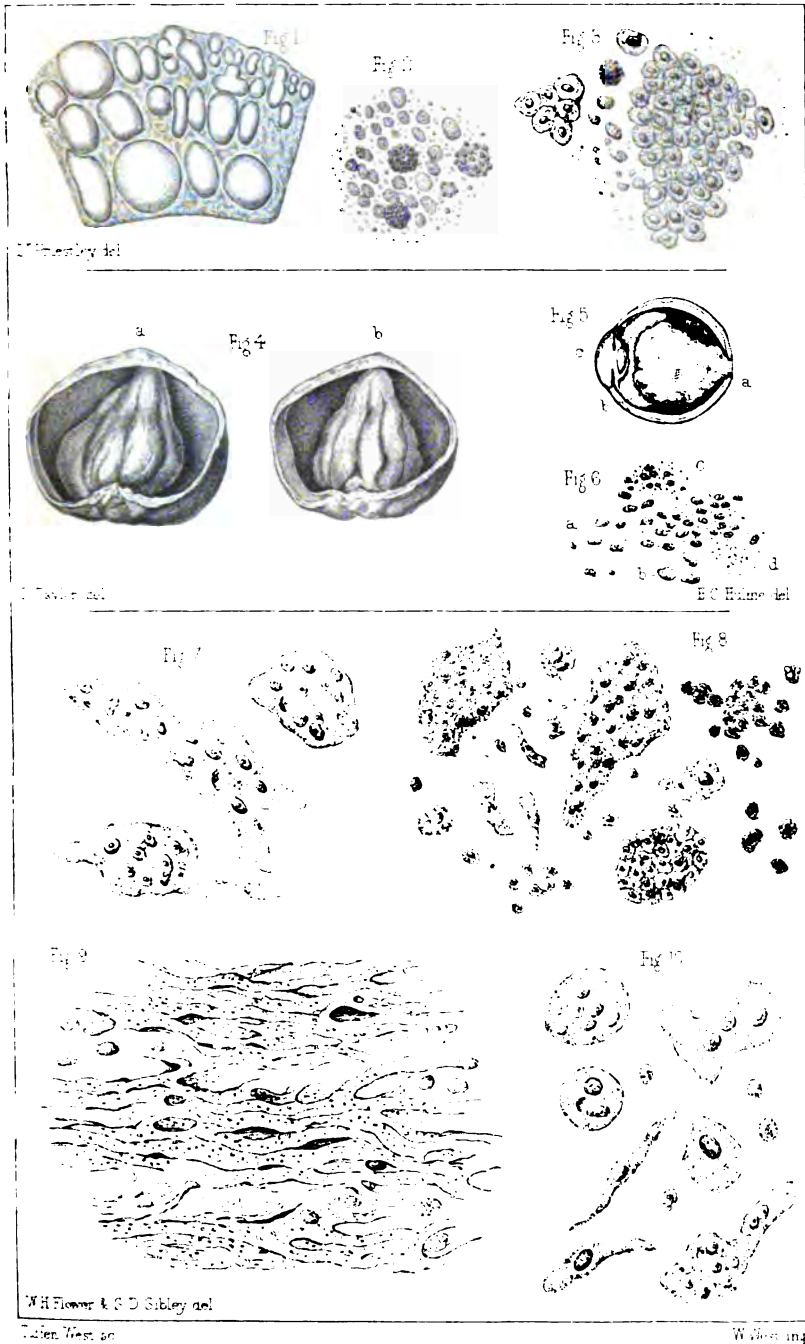

Julien West sc

Wilson imp

admitted into the Samaritan Hospital on the 3rd of March, 1858.

The cervix uteri was very much enlarged, protruding whenever the patient was erect. The mucous membrane covering it was injected in patches and raised by a number of cysts beneath it in the substance of the cervix. Mr. Wells amputated the diseased portion of cervix by means of the écraseur, on the 15th of March. This was done without difficulty, the chain having been passed around the cervix about half an inch above the os. The cervix was nearly cut through when the chain broke. The undivided portion was cut through with the knife, but there was no bleeding of consequence. Two or three ounces of clot came away the next day, and this was the extent of the hæmorrhage. On the fourth and fifth day there was considerable abdominal pain and tenderness, which subsided under the use of linseed-meal poultices and morphine suppositories, and the patient was discharged on the 26th of March, complete cicatrization having taken place. She expressed herself as quite relieved from her sufferings, and rapidly regained strength.*

Dr. Priestley made a careful examination of the tumour, and has supplied the accompanying drawings and description.

Minute examination.—The excised mass (Plate IX. Fig. 2) measured nearly three inches across, and about the same from above downwards. It was flattened antero-posteriorily and had everywhere an irregular and nodular appearace, caused by the projection of cysts on its surface. On its anterior aspect was a deep branched fissure filled with inspissated mucus, and formed by the distortion and dragging down of the cervical canal in the growth of the tumour. This fissure was lined throughout by columnar ciliated epithelium,—the surface of the growth itself having a mucous covering entirely of the scaly kind. A section of the tumour (Plate XI. Fig. 1) shewed it to consist essentially of the development of a large number of cysts, varying from the size of a millet-seed to that of a bean, in the proper fibrous tissue of the uterus. These cysts did not appear to be adven-

* When seen in September, 1858, she remained in good health, menstruating regularly.

titious formations, but merely an abnormal development of the tubular and closed mucous follicles which open into the canal of the cervix, and on its vaginal surface. The glandular tubules, even if not thus abnormally dilated, may be shewn to penetrate deeply into the fibrous tissue of the healthy cervix, by boiling a portion in water, and making thin sections for the microscope.

The cysts were generally filled with a clear viscid mucus, becoming opake in some of the larger ones from the presence of fat granules (Plate XI. Fig. 2). In the smaller cysts a distinct lining of glandular epithelium (Plate XI. Fig. 3) could be demonstrated; in the larger it was less distinct, but epithelial débris mixed with fat particles, was found everywhere among the thickened mucus, constituting their contents. Some of the divided cavities were found to communicate freely with each other, thus representing sections of tubes. Subtending the glandular epithelium where it was demonstrable, was a thin layer of wavy fibrous tissue, the greatest part of the tissue in which the cysts were embedded consisting of true uterine fibres.

The cystic formations were similar to those found in the uterine cystic polypus, and to the forms of cystic disease of the cervix uteri described by M. Huguier—developed, however, to a much greater extent than in any of the cases described by that distinguished observer.

Mr. Spencer Wells, *6th of April*, 1858.

---

21. *Cystic Disease of the Kidney.*

A man, æt. 48, was brought into St. Mary's Hospital insensible, having suddenly fallen down in a fit. He died about two hours afterwards. His wife stated, that he had previously been a healthy man.

On *post-mortem examination*, his body was seen to be that of a fine muscular man, and externally presented no signs of disease. Death was caused by a large extravasation of blood into one of the cerebral hemispheres, which resulted, no doubt, from rupture of a blood-vessel, the cerebral arteries being all of them highly atheromatous. The heart weighed twenty-one ounces, and its hypertrophy was caused by this atheromatous condition of the arteries

at the periphery of the body; its valves were all quite healthy. Both kidneys were studded with innumerable cysts, some of most minute size, others as large as a walnut—between them there was a considerable amount of healthy tissue. The left kidney weighed twenty-one ounces, the right sixteen ounces. The urine found in the bladder was densely albuminous. The other organs were healthy. The kidneys were carefully examined by Dr. George Johnson and myself. The tissue was generally healthy; some few of the tubes were denuded of epithelium, some few were shrunken, and some dilated and thickened.

The case is interesting, as shewing that serious organic disease, and albuminuria may exist in a person who, to all appearance, is in a vigorous state of health.

Dr. MARKHAM, 20*th of April*, 1858.

---

22. *Multi-locular Ovarian Tumour successfully removed by Abdominal Section.*

The patient in this case was a young lady, æt. 22, from the country, whom I saw in consultation with my Hospital colleague, Dr. Ramskill. She was unmarried, and, excepting emaciation consequent on the growth of the tumour, had always enjoyed good health. When I first saw her in November, 1857, the tumour had existed for sixteen months, and was so large as to give her the appearance of being at the full period of pregnancy. It was connected with the left ovary and had a rounded exterior, I performed an exploratory tapping, which confirmed the opinion previously formed that it was multi-locular, and that the contained fluid was very viscid. Only about four pints were removed. The multi-locular character of the tumour put the case beyond hope of relief either from tapping or the injection of iodine, and the risks of extirpation having been placed before our patient in the strongest light, she very quickly made up her mind to encounter them. She possessed heroic self-command and was in every respect an admirable subject for a severe operation.

Early in May, according to our directions, she returned to town. The tumour had, during the interval, increased until the girth was about an inch more than it had been prior to the

tapping. On the 3rd of May, I performed the operation, the patient having been previously seen by Mr. Baker Brown, who agreed with us in thinking that the tumour had no adhesions. An incision from the umbilicus to near the pubes was in the first instance made, but it being found impracticable to diminish the tumour materially by tapping, the section had to be prolonged upwards to midway between the navel and the ensiform cartilage. The tumour, which had no adhesions whatever, was now by a little management drawn out, being still almost of its original bulk. The pedicle was long but broad. I attempted, in the first instance, to secure it by silver ligatures, but in addition to these, it was afterwards deemed safest to use strong hempen cord. Both ligatures transfixed the pedicle, which was tied in two halves. All the ligatures, and the strangulated end of the pedicle, were secured externally in the lowest part of the wound. The incision was united by a series of silver-wire sutures.

The patient made an excellent recovery having scarcely had a single symptom which occasioned anxiety. The ligatures and the sloughy end of the pedicle came away on the fifth day, and the sutures were removed on the eighth. I believe that the whole of the peritoneal incision united by the first intention, at any rate there was never the least discharge from the cavity of the abdomen. She was able to leave her bed at the end of a fortnight, and in little more than a month, returned to her home at Ramsgate in excellent health.

The tumour consisted of a great number of distinct cysts of very various sizes. Some of the larger ones in front contained several pints of fluid, but of those at its posterior part, many were not larger than small oranges. The fluid contained in different cysts varied very much in density, being glutinous in some, and in others of such consistence that it would easily run through a small canula. It was satisfactory to find that our diagnosis had been quite correct, and that it would have been impossible to have benefited our patient by any milder measure.

Mr. Hutchinson, *4th of May*, 1858.

---

23. *Rupture of the Urethra of many years duration, which produced but few Symptoms until shortly before Death.*

J. B., a blacksmith, æt. 62, was admitted into the Middlesex Hospital, under the care of Mr. De Morgan, on the evening of the 20th April, 1858, with retention of urine. He had come on the previous day to the Surgery in the same state, but had been relieved by the passing of a catheter down to an obstruction which was found in the urethra.

The account he gave of himself, and from which he never varied, was, that for seven years he had been troubled with his water; it flowed away constantly when he was at work, and during the night in bed, so that he was obliged always to wear cloths about him to catch it. He could, however, always pass his water if he wanted to do so, as easily and with as full a stream as "any other man," only it frequently happened while it was thus passing, that a sudden stoppage took place, as if—as he described it—something had fallen down and plugged up the opening. He never had any pain, and thought so little of his troubles, that he had not seen a surgeon since seven years ago, when he was in the Hospital with the retention, which had been relieved by the warm-bath. An instrument, he believes, could not at that time be passed into the bladder.

When admitted, the bladder was distended, and he had passed no water since the previous evening. A catheter could not be passed into the bladder, but on passing a moderate sized one down to the obstruction, a quantity of urine flowed by the side and through it, and then the water continued to dribble away for some time, so that more than a pint came away in the course of an hour. The obstruction was situated towards the lower part of the corpus spongiosum. A number three or four catheter could be, at times, passed through it, and then for some distance, but could not be made to enter the bladder. The prostate examined by the rectum, felt large, especially on the right side, and pressure on it gave rise to severe pain. The bladder could not be distinctly felt. The perinæum was soft, but there was great tenderness just below the scrotum. The urine was at first bloody, but this only for the first day after admission, it was always acid and

contained mucus; when cleared from mucus, it was found to contain a considerable amount of albumen.

The man's manner was agitated; he had intense thirst, and the tongue was dry and harsh. He had not had rigors, and was generally sleepy, but easily roused.

The distention of the bladder was greatly relieved from time to time by the partial introduction of the catheter, to so great a degree, indeed, that on the evening of the second day after his admission, it could not be felt above the pubes. On the following day, however (the 23rd), only a small quantity of water could be got away, and the bladder became much distended, and then it was found that a swelling had formed in the perinæum. The constitutional symptoms remained much the same. It was supposed, from the peculiar condition which existed, that there was a stricture of the urethra, with an enlarged prostate, a portion of which formed a pedunculated tumour, which was pressed down on the orifice of the bladder when he passed his water. Between the stricture and the prostate, the urethra was supposed to be dilated so far as to form a sacculus, in which the urine was retained, and which emptied itself when the catheter was passed down so as to press on the stricture.

It was thought best to cut down on the urethra by the perinæum, and this was done on the 23rd. The catheter was introduced as far as it could, and on cutting down on it, an abscess containing thick recent pus was opened. Beyond this the catheter was found lying in a large irregular cavity, in which the continuation of the urethra could not be discovered. The urine flowed freely, however, and the bladder was quite relieved. The attempts to find the urethra had occupied some time, and as the urine flowed freely away, it was not considered advisable unduly to prolong the operation. From this period up to the time of his death, on the 30th, the urine came away copiously. He had a rigor in the afternoon after the operation, and there was no relief to the general symptoms. The tongue remained dry; he had at times wandering. and was genrally drowsy, and seven days afterwards he expired with all the symptoms of urinal poisoning.

Post-mortem examination, twenty-five hours after death.—The

bladder (Lign. 9.) is very much thickened and congested; the prostate somewhat enlarged, with small projections into the

LIGN. 9.

The figure represents the bladder and portion of the urethra.
a. Deficiency of urethra, the seat of an abscess.
b. Layer of recent lymph, lining the cavity.
c. Flap of ruptured urethra, which acting as a valve, stopped the flow of urine, in a similar manner to the so-called third lobe of the prostate, in some old persons.
d. Small abscess in the prostate gland.

urethra, and there is an abscess in the right lobe. The urethra terminates abruptly at about five inches from the orifice of the

bladder, and there opens into a large irregular cavity, lined by old membrane, and with recent lymph adherent to it; at the anterior part of the cavity the urethra is found somewhat dissected up and curling forwards, like the inner coat of a torn artery.

The kidneys were soft and pale, with adherent capsules, and the tubes of the cones were in many parts dilated and filled with lymph, there were one or two cysts on the right kidney, with marks of old cicatrices. No other diseased appearance of importance was discovered.

The following would seem to be the explanation of this singular case. The man must at some former period have had a giving way, perhaps, in fact, a gradual ulceration of the urethra, not followed, however, by general extravasation of urine, but the cavity which was formed becoming lined by a sort of membrane. In this cavity the urine collected when he passed his water, and dribbled away from it when the effort to pass it was over. The sudden stoppage of the water was caused by the free dissected portion of the urethra being thrust forward, so as to act at times like a valve on the tube of the urethra, when the urine was flowing freely. There was no such enlargement of the middle lobe of the prostate as could have accounted for the sudden stoppages in the flow of urine.

Mr. Mitchell Henry, *4th of May*, 1858.

---

24. *Medullary Cystic Disease of the Testicle.*

This specimen was taken from a man æt. 26, who was admitted into Guy's Hospital upon the 17th of April, under the care of Mr. Cock. He had a pale and cachetic appearance, and had experienced but indifferent health. From boyhood, after retaining his urine for some time, his right testicle retracted and disappeared from the scrotum, causing at times great pain; six years ago he had gonorrhœa, and one year ago a chancre upon his penis, but unattended with any secondary symptoms. About one year since, without any blow or known cause, his right testicle began to enlarge, unattended with any pain; since that time it has gradually increased, and upon admission, it was about four inches in its longest diameter; it was quite painless, and could

be manipulated without inconvenience, and squeezed without causing any peculiar sensation. It was of an oval shape, slightly flattened, and in points gave a fluctuating sensation. It was explored with a needle, and only a little bloody serum came away.

The inguinal glands were slightly enlarged, and with the exception of having lost flesh for the last three years, he was comparatively well, although for the last year he had experienced flying pains down the right leg, at times very severe.

Upon the 20th of April, the testicle was excised, and upon examination, the disease was found evidently connected with the body of the testicle, which was smooth, firm, and in parts distinctly fluctuating. The epididymis was much wasted, and beneath its serous covering were developed cysts of different sizes, and from the caput major two may be seen attached to the body by long peduncles, one being nearly an inch long. The few I opened contained clear serum and no spermatozoa.

Upon making a section of the tumour, all signs of the body of the testicle had disappeared, and it was composed entirely of cysts of different sizes (varying from that of a walnut to a millet-seed) some containing others of a smaller growth, and these again containing a third series. Some were filled with a clear serum, and others with a bloody or tenacious fluid, and some were filled with a soft pulpy growth, composed entirely of nuclei, and nucleated cells, and, indeed, presented all the appearances of the medullary cancer.

From the above examination, there can be no doubt that the specimen is a mixed one of the cystic disease, and the medullary cancer, which seems to have been developed in the body of the testicle as well as in the rete testis, the reputed general seat of the cystic disease; the simple cysts developed in the epididymis, and upon it, are apparently examples of the more simple forms of cysts as found upon the testicle.

Upon the whole it would appear that the true cystic degeneration was the chief disease, and that the medullary disease was grafted upon it. The specimen is a good one, illustrating the development of the true cystic disease of the testicle and the medullary. Mr. Thomas Bryant, 18*th of May*, 1858.

---

25. *Calculus, weighing three ounces and three-quarters, which was adherent to the Bladder, removed by Lithotomy, from a Boy.*

J. S., æt. 14, had suffered from symptoms of stone for two years, and was admitted into the Middlesex Hospital on the 20th of April, 1858. His sufferings had latterly become much diminished; but at times he had severe paroxysms of pain. On the 3rd of May, lithotomy was performed by Mr. Henry, by the ordinary lateral incision. There was a good deal of difficulty in extracting the stone, arising partly from its large size, and partly from the fact that it was adherent to the upper part of the bladder. When traction was made upon the stone, and the forceps slipped from off its smooth sides, a hand placed on the abdomen became readily sensible of the rebound of the stone and the bladder into their natural position; moreover, it was only when the forceps were directed upwards and to the right side that the stone could be seized, contrasting, in this respect, with the position usually occupied by a calculus, which by gravitation, sinks to the lowest part of the bladder.

The simple adhesion of a stone to the surface of the bladder has been doubted, but in this instance, the fact was rendered certain, by the circumstance that one end of the calculus was covered with filamentous membrane, which, on microscopical examination, proved to be recently organized lymph. In the sixth volume of the "Transactions," Mr. Shaw has detailed the particulars of a *post-mortem* example of the kind, and has entered at some length into the pathology of the subject.

The boy speedily recovered from the effects of the operation. On chemical examination, the stone which was beautifully laminated, proved to be thus composed: first, a nucleus of pure white lithic acid; second, a layer of lithate of ammonia; third, a layer of oxalate of lime; fourth, a layer of porous lithic acid; fifth, a layer of compact lithic acid; sixth, a layer of fusible calculus, to one end of which was attached the remains of soft membrane.

Mr. Mitchell Henry, 18*th of May*, 1858.

VI. DISEASES, ETC., OF THE OSSEOUS SYSTEM.

1. *Comminuted Fracture of the Lower Extremity of the Femur extending into the Knee-Joint; united with considerable Shortening and Deformity.**

Mr. William Adams remarked that the form of injury might be described as oblique fracture of the shaft of the femur, a little above the condyles; and a split-fracture between the condyles into the joint. The condyles of the femur had been drawn backwards and upwards by the posterior muscles of the thigh, and as a consequence of this, the upper fragment projected forwards and downwards, its fractured extremity lying over the joint. This, Mr. Travers observes, had been mistaken for the upper fragment of a fractured patella. The upper and lower fragments, where they overlapped were not in contact, but were in most parts from half an inch to an inch apart, and connected by strong buttresses of bone passing from one to the other. The split-fracture between the condyles was firmly and directly united by bone, without any callus having been thrown out on the surface, but a sliding displacement had taken place to the extent of nearly half an inch, so that the condyles did not hold quite their normal relation to each other, and an irregularity existed in the joint-surface.

Pathologically, therefore, the specimen exhibited remarkably well, the method of repair of a fracture extending into a joint; and also the mode of indirect union through strong buttresses of bone thrown out between two fragments of bone not directly in contact.

Surgically, it illustrated the difficulty of correct diagnosis in fractures close to and involving the articular extremities of bones; and also, the difficulty of employing the ordinary surgical means to procure apposition in certain cases of severe and complicated injury at an advanced period of life.

History of the Case and Observations by Mr. B. Travers, Jun.—The specimen was taken from the body of a gentleman, æt. 70, who died in December, 1856.

* This specimen is deposited in the Museum of the Royal College of Surgeons.

In April, 1847, he fell down the flight of stone steps leading to the river on the Southwark side of London Bridge. In addition to the injury here displayed, the party sustained a bad contusion of the scalp, and a fracture of both bones of the fore-arm. Two years elapsed before he finally abandoned the use of his crutches. Latterly he walked remarkably well with the aid of a stout stick and a high-heeled shoe. He died eventually from the effects of a severe burn. The exact character of the injury to the knee-joint was never clearly established during life, and the late Mr. Liston, amongst others, thought the patella had undergone fracture and comminution, being misled by the riding and projection of the end of the upper fragment of the femur.

The parts were so much swollen, and the patient otherwise so much disordered after the receipt of this injury, that all that could be done, or rather borne, was the application of a straight splint, which was not removed for many weeks, it being likely that a stiff joint would in any case be the final result of this accident should the patient survive. The preparation is interesting in this point of view, *viz.*, it exhibits the consequence of straight setting,—considerable deformity. Nevertheless, with the exception of a shortened limb, and a somewhat confused action of the knee-joint, this gentleman was but very slightly disfigured during life. It may be stated positively, and for the guidance of others, that flexion and extension could not be borne in this case. The attempt provoked an agony of suffering, and had it been persevered in, would, probably, have proved fatal, from the violent local irritation so induced.

Under these circumstances, a deformed or shortened limb, may be regarded as an inevitable and easy compromise, when it can be obtained, without incurring those farther risks which are inseparable from great activity on the part of the surgeon.

Mr. Adams, for Mr. Travers, Jun., 17*th of November*, 1857.

---

2. *Fracture of the Neck of the Femur.*

A lady, æt. 77, fell on getting out of bed on the 7th of August, 1857, and was unable to get up afterwards or to support any weight upon the right leg. On a careful examination, there was

no appreciable shortening of the limb, no eversion of the foot, and the evidence of crepitation was doubtful. Rotation of the limb caused severe pain.

She was put to bed and the limb placed in a comfortable position on pillows, and in a day or two she was able slightly to draw up the limb.

A few weeks previously she had sustained a fracture of the olecranon which had weakened her considerably. After lying a few days, she gradually sank, and died eleven days after the accident.

Post-mortem examination, twenty hours after death.—The right thigh was very much blackened, especially about the hip, and on dissecting out the head of the femur much blood was found effused in the neighbourhood of the joints.

The specimen shews a fracture through the neck of the femur within the capsule, without displacement, which appears to have been prevented by some of the fibres of the orbicular ligament.

Mr. Part, 17*th of November*, 1858.

---

3. *Necrosis of a large portion of Lower Jaw.*

G. B., a labourer, æt. 31, came under my notice at Guy's Hospital with necrosis of the lower jaw. He had always enjoyed good health till eight years ago, when he had a chancre and was profusely salivated. He remained quite well for three years, when pain first appeared in the lower jaw, upon the left side. This pain continued at intervals till eleven weeks before I saw him. At this time it began to swell, and an abscess formed beneath his chin, for which he went into King's College Hospital, when he had seven teeth removed; he remained there for several weeks, and left upon the 14th of October. Upon the 15th he applied to Guy's Hospital, with his face much swollen, and a fistulous opening beneath his chin. Much new bone had evidently been thrown out; upon examining his mouth internally, a large portion of bone was found to be necrosed and loose; with a pair of forceps this was removed without difficulty, and was found to consist of the whole symphysis and horizontal rami, as far as the molar teeth, the mental foramina upon both sides being included. Sensation in the part was natural.

The interest of this case consists chiefly in the extent of bone

diseased, and ease with which the dead bone was removed. A question occurs in this as in similar cases, regarding the inferior dental nerve, of some importance, *viz.:* What becomes of it? is it destroyed? and, if so, where does the chin receive its nerve of sensation? Mr. Thomas Bryant, 17*th of November*, 1857.

---

4. *Formation of a False-Joint between the Odontöid Process and Body of the Axis.*

The specimen consisted of the occipital portion of a skull, with the atlas adhering to it by anchylosis, and the axis, having its odontöid process detached, as a distinct bone. It was obtained from a dissecting-room subject, and the history of the case was unknown.

The odontöid process was of its normal size and figure; it was separated at its base, on the under surface of which, as well as on the upper surface of the body of the axis, were the appearances of an articulation by a false joint having existed during life.

Lign. 10.

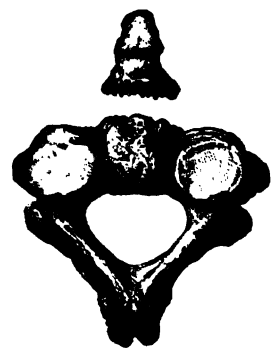

This figure represents the Axis and its separated odontöid process.

Mr. Shaw was of opinion that the separation of the process was not the result of violence; but that it had been caused by disease occurring in early life, when the process was still an epiphysis.

That view was supported by the evidences of disease having existed, at one time, in the joints of the occiput and atlas. These two bones were anchylosed, and the union was so intimate that it amounted to complete fusion of the articular surfaces; there

was also slight distortion, the atlas, in the process of union having been projected somewhat forwards, and turned round at the same time on its centre, so that the right side was more advanced than the left; in this way a perceptible encroachment on the canal for containing the spinal marrow, had been produced. These morbid appearances denoted that the disease, thus affecting parts in close proximity to the odontöid process, had prevailed at a distant period, probably when the individual was young. It is not till about the fourth year that that process ceases to be an epiphysis, and is joined to the body of the axis by bony union. Accordingly, it is reasonable to conclude, that if the disease had been active at that period, the process of ossific union would have been interrupted; and we can readily understand that, afterwards, the junction would take place by the formation of a false-joint. Mr. Shaw, 1*st of December*, 1857.

---

5. *Diseased Knee-joint removed by the Operation of Excision.*

This specimen is chiefly interesting, because it shews, in the first place, the destruction that may ensue to an articulation from disease originating in the ends of one of the bones entering into its formation; and secondly, the value of excision as applied to the treatment of limbs rendered useless and dangerous to life by the existence of so much mischief. The patient was a girl, æt. 16, who for several years had been the subject of disease of the knee-joint. Suffering had reduced her to the lowest ebb, and as it became absolutely necessary to resort to some operative proceeding, removal of the joint by the method of excision was chosen.

From the specimen it appears that the disease arose in the spongy structure of the lower end of the femur, and after breaking down all surrounding normal structure, had worked its way into the joint by perforating the articular cartilage, and thence bursting through the capsule of the articulation. The disease was of that character recognised as strumous or tuberculous affection of the spongy tissue of bone. Although a very considerable portion of the condyle was included in the destruction, still a free use of the gouge removed all traces of existing disease. I believe the patient would have sunk had not the joint or limb been removed. She is now a fine healthy child, and has the advantage

of a highly useful limb, and one apparently free from any trace of disease. To all appearance the cavern that remained in the lower end of the thigh bone, after removal of the disease, has been filled up with new bone or some substantial material; while the binding together of the cut surfaces of the femur and tibia is osseous and quite firm.

I should state that the head of the tibia was found quite free from mischief, and that the patella was removed, although not in the least affected. Mr. Price, 1*st of December*, 1857.

---

6. *Ulceration of the Under Surface of the Patella, occurring after Removal of the Knee-joint.*

Eleven months since, I removed the knee-joint of a woman, æt. 26, for that form of articular disease, known as "Necrosis of the Joint." At the time the operation was performed, the destruction to all the tissues composing the joint was complete, yet the patella to all appearance remained healthy. Being unwilling to remove it, I allowed it to remain undisturbed in the reflected flap. The woman made an admirable recovery, and the cut surfaces of bone became knit together by a firm osseous binding. Within the last few months, however, a succession of obstinate abscesses formed among the soft parts above the seat of the original wound, and as they refused all attempts at healing, it became evident that some foreign body was keeping up constant irritation. The pain, amounting sometimes to agony, was extreme, and as the patient was evidently suffering with great detriment to her permanent recovery, I thought it prudent to ascertain, whether inclusion of the patella was the cause of the mischief.

An examination confirmed the suspicion, and I therefore removed the bone by a very limited semi-lunar incision. It appears that the entire under surface of the bone is destroyed, and in parts deeply ulcerated.

The specimen is unique, and exceedingly interesting, as it illustrates the subsequent harm that may arise from the patella being allowed to remain; while there is a precedent afforded for the propriety of removal of the bone. I would, therefore, as a general rule, advise that the patella be taken away at the time of the operation, as its retention may cause subsequent trouble and

annoyance; while its removal is not fraught with the disadvantages to the utility of the limb which are generally imagined.

Mr. Price, 1*st of December*, 1857.

---

7. *Head of the Femur removed by the operation of Excision.*

The patient from whom this specimen was removed, is a little boy, æt. 8 years. He had suffered for three years with extensive disease of the left hip-joint, which had refused all attempts at treatment. The child had latterly commenced to suffer extremely, so that the general health was fast breaking, and there appeared but slight hopes that he would be enabled to support the depressing effects of the disease for any considerable length of time. It being clearly evident that the articulation was extensively involved, and that allowing the child to remain in his present condition was fraught with extreme danger to life, I determined to remove the head of the femur, and such contiguous parts as might be found included in the disease. The symptoms of ulceration within the joint cavity were well-marked, and therefore there remained but little doubt of the propriety of the operation.

On opening the joint, the synovial membrane was found in a thickened and pulpy condition, and the ligumentum teres entirely gone. The floor of the acetabulum was healthy, except at one or two spots which were removed by the gouge.

The head of the femur, which was taken away by cutting through the shaft immediately below the trochunters, shews extensive mischief to have taken place in its cartilaginous covering, which is almost entirely gone. The substance of the bone appears sound, although, perhaps, somewhat softer than natural. In nine weeks the boy was walking about on crutches, and some few weeks later, possessed a most useful and admirable limb. The operation is in many points interesting, and must be classed among the few cases extant in which the head of the femur and part of the acetabulum have been removed without previous destruction to the capsular ligament and luxation of the head of the bone. It would appear, upon a close examination into the various symptoms, and upon inspection of the specimen, that the primary seat of disease was, in all probability, the ligamentum teres.

Mr. Price, 15*th of December*, 1857.

8. *Cancer of the Spine.*

A man æt. 50, a gardener by trade, a fresh-coloured, healthy-looking man, was admitted into King's College Hospital, under Dr. Todd's care, on the 28th of December, 1857. About six weeks before admission, he had great pain in the calf and back of the thigh on the right side, but did not suffer from cramps. He only lay by for a day or two, and then resumed his work, and continued at it for a fortnight with but little suffering, and at the end of that time the pain shifted from the right to the left leg. At the end of the third week he no longer complained of pain, but it was replaced by a feeling of numbness in both legs and loss of power in the left. A fortnight before his admission into the Hospital, he began to pass his motions under him and soon afterwards became unable to empty his bladder, which state of things continued until his death.

On admission, there was complete loss of voluntary motion in both lower extremities, and paralysis of the extensor muscles of the bladder and of the sphincter ani; there was also loss of sensation in the feet, but considerable reflex action in both, on the application of a hot spoon or the sprinkling of cold water. The muscles of both sides were completely relaxed, but there were occasional twitchings of the legs. There was no tenderness over the spine, nor was there any deformity. The loss of sensation extended as high as the umbilicus.

Dr. Todd diagnosed rapid softening of the antero-lateral columns of the cord in the dorsal region, involving more or less the posterior columns.

The patient continued in much the same condition for some time after his admission, but in spite of the use of the catheter and large doses of dilute-nitric acid, the urine became alkaline, thick and ropy. On the 15th of January, it became evident that the muscles of respiration were becoming involved, breathing being carried on by the diaphragm almost entirely, the lower intercostals being paralyzed, and the sterno-mastöids and pectorals acting convulsively. He sank gradually and died on the afternoon of the 16th of January, 1858.

Post-mortem examination, January 18th.—The spinal canal was first examined, and the cord was found to be softened over a space

extending from the second to the eighth dorsal vertebræ, the antero-lateral columns being more disintegrated than the posterior. The posterior portion of the body of the last dorsal vertebræ was found to be hollowed out almost as if in a carious condition. On opening the chest and abdomen, a large mass of cancerous matter was found deposited on the body of the last dorsal vertebra, and a similar mass opposite the seventh and eighth dorsal vertebræ. The liver contained two large masses of cancer replacing its proper structure, and the bronchial glands were infiltrated with the same material. It is remarkable that the membranes of the cord were perfectly healthy except in close proximity to the softened portion and there were no masses of cancer within the spinal canal. It is necessarily, therefore, a question whether the softening was the result of impaired nutrition or of cancerous infiltration, a point, on which the microscopic appearances gave no reliable information owing to the resemblance between broken-down nerve-cells and those of a cancerous nature.

Microscopic appearances.—The softened portion of cord presented large cells containing oil-globules of varying size. Large mother-cells containing nucleated cells, mixed with nerve fibres and vesicles. In the liver were large compound cells and numerous small cells, but no fibres.

Mr. C. Heath for Dr. Todd, 19*th of January*, 1858.

---

9. *Fibrous Tumour developed within the Lower Jaw, surrounding the Dental Nerve.*

S. G., a healthy looking boy, æt. 9, was admitted into Guy's Hospital, under Mr. Cock, on the 20th of January, 1858.

Two years previously he had received a blow upon the left side of his chin, and the accident was followed by pain and tenderness when the part was touched, but by no swelling. Six months after the accident a tumour appeared over the spot, and this has since gradually increased. The tumour was unattended with pain, except when roughly manipulated. Upon the 25th of January, Mr. Cock excised the growth, and found it emerging from the bone, and embedded in it; the bone over it had become absorbed, as there was no osseous shell, and the margins of the cavity were slightly raised and seemed bevelled off. Upon its removal the

dental nerve was seen divided and lying loose in its bony canal.

The tumour, during its excision, was divided into two parts; it was about the size of a walnut, and firm to the touch, and the dental nerve passed through the centre of the projecting portion, and could easily be dissected off, although a portion of its sheath seemed to be adherent to the growth. The small portion which was embedded in the bone was without nerve, but it had a passage through its centre where the nerve had evidently passed, but which during the operation had been pulled out, and left hanging in the wound. Microscopically, the tumour was seen to have been composed of delicate fibre-tissue; it had evidently been developed in the dental cavity, and surrounded the nerve, absorbing the bone during its growth.

The absence of pain is worthy of note, as from the relative position of the tumour and the nerve, together with the fact of its development in the bone, severe pain might have been expected. Mr. T. Bryant, 16*th of February*, 1858.

---

10. *Necrosis of the Tibia, from a Child twenty-eight days old.*

The subject of this specimen was born, at the full period of utero-gestation, of very sickly parents, and was one of twins, the other being born dead, and in a state of partial decomposition; it was very small and ill-nourished at the time of birth, but nothing peculiar about the diseased leg was then observed. My attention was first directed to it about the third week, when I found, upon making an examination, a large fluctuating tumour occupying the upper part of the leg, the skin over it being not discoloured, and it shewed no tendency to point; the child was at that time suffering from stomatitis, in an ulcerative form, of which it died on the twenty-eighth day after its birth.

The father of the child was suffering from secondary syphilis about the period when the pregnancy commenced; there was no history of external violence.

On examining the limb after death, I found the upper and back part of the leg occupied by large abscesses opening into a cavity in the head of the tibia, in which was contained a sequestrum.

The case is interesting in connection with one reported in the

fifth volume of the Society's "Transactions," by Mr. Heyworth, where the lower part of the femur of a child, eleven days old, formed the internal wall of an abscess, the result of which would probably have been necrosis, had the child lived long enough; there was, however, a distinct history of an injury from external violence in Mr. Heyworth's case.

Dr. SALKELD JOHNSON, *2nd of March*, 1858.

---

11. *Morbus Coxæ. Death from Encephalitis.*

E. R.,—F., æt. 3, first came under my care in the middle of October, 1856. Her mother stated, that six weeks previously the child had fallen from a slab on to which she had climbed, and struck her right hip; she suffered much pain at the time of the accident, but it soon passed off. A few days after, she was observed to limp, complained of pain in the limb, the precise situation of which could not be ascertained, and became very restless at night, moaning and starting in her sleep.

The child was now placed under medical care. She was first treated for a rheumatic affection of the knee-joint without any relief, and subsequently, for a deranged state of the general health only, under the idea that no local affection existed, but with no better result. The symptoms gradually increased in severity, until she could not put her foot to the ground, or move the limb, however slightly, without experiencing acute pain. She had been delicate from her birth, and was born at the eighth month of gestation. On stripping her, I observed that the great trochanter of the right side projected more than usual, the limb was slightly shortened from canting of the pelvis, and rotated inwards, the toes resting on the dorsal aspect of the opposite foot. Gentle percussion over the great trochanter caused the child to scream with pain, and neither flexion or extension of the limb could be borne. These symptoms were accompanied by a good deal of constitutional disturbance, fever, derangement of the hepatic secretions, great debility, etc. She had been subject to attacks of headach for some time past.

The child was ordered to be kept in bed, and strict quietude enjoined. Iodine and iodide of potassium, and poppy fomentations to the joint, were used at intervals, and a linament of cod's liver oil

and opium constantly and freely applied over the articulation. Iodine and iodide of potassium ointment were occasionally substituted for the fomentations. The general treatment consisted in the application of leeches to the epigastrium, careful regulation of the bowels by aperients and alteratives, and the occasional use of enemata. On the subsidence of the febrile symptoms, cod's liver oil and other tonics were given, together with a supporting diet of meat, wine, porter, etc. This treatment was steadily pursued, with very beneficial results, although she suffered from occasional relapses, and I continued to see her at stated intervals up to October 20th, 1857, by which time she had little or no pain in the hip, could nearly bring her foot to the ground, and was able to walk with assistance, or by herself from chair to chair; and this she had done for some months past, all active symptoms having subsided. From this date I saw no more of my patient, until Wednesday, the 20th of January, of this year (a period of three months) when she was brought to me by her mother.

The child was lying in her arms in a state of collapse and stupor from which she could scarcely be roused to momentary consciousness; when told to put out her tongue she did so; but with difficulty could be made to retract it; there was strabismus of both eyes, the mouth was drawn somewhat to the right side, the upper and lower extremities were convulsed at times, and her head drawn backwards towards the right shoulder, and she uttered occasional shrill cries. Pulse rapid and feeble, frequent vomiting, involuntary passage of urine, bowels constipated. Her mother stated that nearly nine weeks since, the child, whilst standing by the dinner-table, had fallen with a steel fork in her hand, one of the prongs of which had inflicted a small wound on the right side of the head (it was situated over the right parietal eminence and was still unhealed), after this time she began to complain of pain in the head and in the hip-joint, she became feverish and flushed, talked incoherently at times, and had occasional attacks of pseudo-blepsis; vomiting had also set in a day or two before she was brought to me, every kind of sustenance being rejected. On examining the hip, I found that an abscess had formed on the upper and anterior aspect of the thigh. I directed the child to be taken home as soon as possible and continued to attend her

there up to the time of her death. She died on the Sunday following (24th of January) at six o'clock in the morning.

Post-mortem examination, thirty-three hours after death.—The body was greatly emaciated, the small punctured wound was in a healthy and healing state, and the subjacent pericranium slightly abraded. On removing the calvarium, and reflecting the dura mater, the whole of the cerebral hemispheres were seen to be of an uniformly vivid red colour, as if from extravasation, but on closer examination, this appearance was found to arise from engorgment of the vessels only, and extended equally to the base of the brain and cerebellum; the vessels of the pia mater between the convolutions, were in a similar state. On slicing the cerebral substance a multitude of red points were observed, and in some places blood oozed out on incision. The grey matter had a reddish hue. The brain was large, somewhat firmer and heavier than usual for a child of four years of age,* which might be occasioned by the increased quantity of blood therein, but I had no opportunity, of verifying the correctness of my conclusion by weighing it. There was no ramollissement of any portion of the brain, and no fluid in the lateral ventricles, which seemed, on the contrary, preternaturally dry. With the exception of unusually firm adhesions of the left lung from summit to base, to the costal pleura, the thoracic viscera, were healthy, as were also the abdominal. There were fibrinous coagula in both the right and left cavities of the heart.

The Hip-joint.—In reflecting the integuments of the hip, the sac of the abscess (which contained about four to six ounces of creamy pus mixed with tubercular matter) was opened, its superior boundary being formed by the integuments only, the posterior by a portion of the rectus femoris, which was hollowed out and partially destroyed. A probe passed between the acetabular origin of this muscle and the insertion of the vastus externus, at the base of the great trochanter, entered the cavity of the joint through a small aperture in the capsular ligament, which was otherwise entire. The ligamentum teres and the

* Presuming the weight of the brain in a child of four years old to be thirty-two ounces, as stated by M. Mauthner. See "British and Foreign Quarterly Review," p. 387, vol. 21, 1846.

synovial membrane were destroyed, as for the most part were the inter-articular cartilages. The acetabulum was in a state of incipient caries, and the head and neck of the femur in a more advanced stage, a portion of the investing cartilage of the former lying detached at its upper and inner aspect.

With regard to the history of this case, it will be observed, that up to the 20th of October, 1857, there was no indication of suppuration about the hip, all active symptoms having subsided, and but for the intercurrence of the cerebral affection (encephalitis) and the further mischief occasioned to the joint by the fall, a favourable termination to the disease might have been expected. This would have been contrary to the usual course of events in morbus coxæ, when it occurs at such an early age, arising partly from the rapidity with which the various tissues of the joints undergo disintegration from scrofulous disease at this period of life, and partly from the difficulties of treatment arising from the same cause, besides the greater degree of mortality noticeable where (as in this instance) the patient is congenitally scrofulous. Fortunately, however, hip-disease is comparatively rare at this age, as may be seen on reference to the accompanying table of one hundred and twenty-nine cases* among females distribed over quinquennial periods. Looking at the morbid appearances of the joint, there seems little doubt that the disease had its origin in caries of the head and neck of the femur, resulting in the further destruction of the articular surfaces. According to the mother's account, the blow inflicted on the child's head by the fork was slight (an assertion fully borne out by the appearance of the punctured wound), and the contusion from the fall by no means severe. Yet so soon did the cerebral symptoms follow on the accident, there could be little question they were occasioned by it.

This case furnishes an additional proof to many which have occurred under my observation, that when once there exists a tendency to scrofulous disease of any organ of the body (*e. g.* of the brain as was evinced in this child by frequent attacks of headach), a very slight and apparently unimportant local injury

* Age.	1-5	5-10	10-15	15-20	20-25	25-30	30-35	35-40	40-45	45-50	50-55	Total.
Cases.	3	41	19	17	17	22	6	1	1	1	1	129.

is sufficient to develop the disorder, and not infrequently to bring about a fatal result.

Mr. OLIVER CHALK, *2nd of March*, 1858.

---

12. *Fracture of the Neck of the Femur within the Capsule.*

C. F., æt. 69, an inmate of the Kent County Lunatic Asylum, upon the 20th of November, 1857, was pulled off the edge of her bed by a child, and fell upon her right hip. There was some pain in the neighbourhood of the hip-joint, but more particularly in the knee. The shortening was very trivial, and there was no eversion of the foot. The woman could partly flex her thigh, though not without pain, and there was no effusion. Some difficulty was experienced in detecting crepitus, which was accomplished at last by an assistant extending, and at the same time, rotating the leg inwards. The long splint was applied and kept on for some weeks, but a bed-sore appeared, and from this she sank exhausted upon the 8th of January, 1858, seven weeks after the the injury.

The specimen it will be seen is a genuine case of fracture of the neck within the capsule; the line of fracture is not direct, and upon one half is not to be seen unless some force is employed to separate the parts. The reparative process seems to have progressed fairly, and if the bed-sore had not proved too much for her feeble powers, there seems every reason to believe that perfect reparation would have taken place.

Mr. THOMAS BRYANT, *6th of April*, 1858.

---

13. *Impacted Fracture of the Neck of the Thigh Bone.*

A woman, æt. 62, an inmate of the Kent County Lunatic Asylum, when walking in the hop-ground upon the 7th of September, fell upon her hip. When taken up there was found to be half an inch shortening of the limb, slight eversion of the foot, and power to flex the thigh; crepitus was only detected after several efforts. A long splint was applied for six weeks, and the patient regained the use of her leg; as she stood, there appeared no perceptible difference between the lower extremities, and the patient would not admit there was any dissimilarity.

Early in August she was seized with a severe attack of bronchitis which terminated her life upon the 12th of November, 1857, fifty-five days after the accident.

The specimen presented is an excellent example of this form of fracture. The neck is completely driven into the trochanter, and the small trochanter is fractured and pushed up; perfect union has taken place. The symptoms presented were those generally existing in such cases.

Both the above specimens were sent to me, with their histories, by my friend Mr. W. Hills, of the Kent County Lunatic Asylum.

Mr. THOMAS BRYANT, *6th of April*, 1858.

---

14. *Base of the Skull attended by Epithelial Cancer.*

B. S., æt. 45, a weaver, a small spare man of steady habits, was admitted into St. Thomas's Hospital, on the 10th of February, 1858, under the care of Dr. Risdon Bennett. He attributed the origin of his illness to having sat in a draught about two months ago, after which he became slightly deaf of the left ear. The deafness subsequently increased, and was attended by noises in the ears, and pain in the region of the left ear, he became weak, low-spirited, lost flesh, and was unable to work. When first examined, he complained much of pain in the left temporal region and behind the ear, had imperfect vision with the corresponding eye, over the motions of which he had not perfect control. Shooting pains extended over the whole of the left side of the face, which was numb, but there was no muscular paralysis. The left pupil was somewhat more contracted than the right, and distant objects were seen double. The tongue which was coated, and when protruded, inclined to the left, felt to him as though greatly swollen and sore. The bowels were confined, and the pulse feeble. There was no febrile disturbance.

Counter irritation, purgatives, Dover's Powder, and calomel, with iodide of potassium and tonics, were the principal remedies employed. Subsequently, the speech became indistinct, and there was dysphagia, the saliva ran out from the left corner of the mouth, and the movements of the left eye were still further impaired. He complained a good deal of nausea, and had in the early part of his illness vomiting after meals. His dysphagia and

feeling of soreness of the mouth and throat increased, and he died exhausted and much emaciated on the 31st of March. Throughout his illness there was no disturbance or impairment of the intellectual faculties.

On examination of the body the day after death, the thoracic contents were found healthy, with the exception, that a considerable quantity of muco-purulent matter was contained in the bronchial tubes. The abdominal viscera were healthy. There was a good deal of serum in the sub-arachnöid tissue and the larger veins on the surface of the brain contained much blood. The brain itself was perfectly healthy throughout. The left side of the pons Varolii, and the left lobe of the cerebellum were somewhat depressed. On examining the base of the skull after removing the brain, the basilar process and the body of the sphenöid bone, were found to be considerably enlarged, and appeared not only to project towards the cavity of the skull, but also to have separated to a greater distance than natural the two petrous bones. Athough this enlargement occupied the whole of the basilar process it was decidedly greater on the left than on the right side, and the entire substance was soft and elastic to the touch. The bones having been removed, a section was made through the mesial line of the occipital and sphenöid bones. It was then found that the whole of the sphenöid and the basilar process of the occipital bones, to within about half an inch of the foramen magnum, constituted a uniformly diseased mass, the thickness of which varied from about one inch to one inch and a half, and which was strictly limited to the parts mentioned, involving neither the greater nor lesser alæ of the sphenöid, nor any portion of the ethmöid, leaving the temporal bones healthy. The diseased mass was tough, solid, and elastic, and presented generally a yellowish hue. On close examination, it was found to be made up of a tough fibröid network, the meshes of which varied from about half a line downwards, and were filled with yellow, opaque, and thick material, which was easily squeezed out in the form of commedones. The dura mater covering the upper surface of the mass, was generally healthy, but here and there appeared to be a little discoloured, soft, and uneven. On the anterior portion of its under surface there was an ulcer of the size of a shilling, *i.e.*, at the upper and back part of the pharynx. All

the cerebral nerves on the right side were healthy, and the first, second, seventh, eighth and ninth of the left side appeared healthy up to the point at which they passed out of the skull, although, probably, they had all been submitted to pressure within the skull, as well as in passing through the sphenoïd bone. The fifth nerve, however, as soon as it reached the upper edge of the petrous bone became much enlarged, and the Gasserian ganglion was fully as large and plump as a small hazel-nut, and there can be no doubt that the third, fourth, and sixth nerves in the cavernous sinus, were in like manner affected. The pituitary body was apparently healthy, though compressed within the enlarged boundaries of the sella turcica.

A microscopic examination of the diseased mass was made by Dr. Bristowe. The inspissated sebaceous matter, which was scraped and squeezed from the cut-surface of the mass, was found to consist almost entirely of thin scab-like cells, which were frequently distinctly arranged in parallel layers. The cells were, for the most part, distinctly epithelial, but generally smaller than is usually the case in epithelial cancer.

Dr. R. Bennett, 20*th of April*, 1858.

---

15. *Edentulous Lower Jaw having no Mental Foramina.*

This bone was taken from a very aged subject in the Dissecting Room of the Westminster Hospital, attention having been first drawn to it by the dissectors being unable to find the mental branches of the fifth nerve. On careful dissection no nerve could be found, nor any foramen through which it might have issued. No branches were found proceeding from the superior maxillary division to supply the place of the absent ones and the seventh nerve was normal. On removing the jaw entire, in a subsequent stage of the dissection, it was found that the inferior dental nerve entered the bone in the usual way, but on dividing the other structures retaining the bone *in situ*, the nerve was pulled out entire from its canal with the slightest possible exercise of force. On maceration, the jaw presented a good specimen of a perfectly edentulous jaw, there not being the slighest indication of any mental foramina, if they ever existed. If the foramina ever

existed, it must be supposed that the obliteration took place by a gradual growth of bone which severed the nerve in its progress. Is it possible that this process may be one cause of tic-doloureux, and that the tic ceases when the division of the nerve has actually taken place? Mr. CHRISTOPHER HEATH, *4th of May*, 1858.

---

16. *Three Cases of Disease of the Hip-joint.*

Two of these were taken from a man, æt. 49, who died in Guy's Hospital under the care of Dr. Wilks. One specimen was of not more than ten weeks' duration, the other of many years.

SPECIMEN No. 1 is but partial, and in it the disease is confined to a spot upon the head of the femur near to the insertion of the ligamentum teres and the corresponding part of the acetabulum: the disease is granular degeneration of the cartilage, the general and microscopical characters affording a good illustration of the process of disease as I have described it in the "Lancet" for the 31st of October, 1857. In one spot the degeneration was complete, as shewn by excavation exposing the bone; in other parts the disease had not progressed so far, and had commenced upon the bony surface, as seen by the cartilage being loosened from the bone and easily peeling off. The cartilage cells in the diseased portions are enlarged to different degrees, and filled with granules, but the disease is confined to the spots indicated, the cartilage in other parts being quite healthy. In the corresponding portion of the acetabulum where the cartilage was involved, the disease had commenced upon the outer surface and had not involved the deeper parts, or exposed the bone.

The bone itself seemed denser than usual, and in the fresh state plainly demonstrated an excess of vascular action where the cartilage was diseased, leading me fairly to infer, that the degeneration of the cartilage was secondary in the order of events, the affection of the bone being the primary disease.

SPECIMEN No. 2, was taken from the same subject, and was of about twenty years' duration. The limb had been a useful one, and since its early disease had never caused any pain. There was no history or external signs of abscess of the joint. The joint is perfectly fixed and anchylosed by ligamentous union, much new

bone has been thrown out upon the lower lip of the acetabulum, and the neck of the femur has been almost all absorbed. The head of the bone has formed a curious hook-like process, and the cartilage has entirely disappeared.

The disease here must surely have commenced in the bone itself, and a chronic inflammatory change of a low type (rightly, perhaps, called strumous) was probably the earliest condition, followed as a consequence by absorption of the cartilage, and of the neck of the bone; the disease could not have commenced in the synovial membrane or cartilage, as other symptoms, such as abscess, etc., would have ensued. In this instance also, like the previous, the bone seems to have been its original seat.

SPECIMEN No. 3, was taken from a boy, æt. 6, who died in Guy's Hospital, under the care of Mr. Cock, from tubercular meningitis. The duration of the disease of the hip could not be well made out, but about two years was the probable period.

It will be seen that the disease in this case depends upon the bone, a portion of dead bone being visible in the under side of the neck; the cartilage has disappeared altogether, and the synovial membrane is thickened from old inflammation; abscesses had existed for some months, and until the sequestrum, the source of all the mischief, had come away or been removed, a recovery could not have taken place.

As far as the local disease goes, it is certainly favourable to that severe operation, excision of the hip. The acetabulum was deprived of its cartilaginous covering, but otherwise did not appear diseased. The disease apparently being confined to the point as represented in the specimen.

Mr. THOMAS BRYANT, 15*th of May*, 1858.

VII.—DISEASES, ETC., OF THE ORGANS OF SPECIAL SENSE.

1. *Adhesion of the Retina to the Cicatrix, following the removal of the Cornea.*

The patient, a gentleman, æt. 25, lost the sight of his left eye when very young, by an explosion of gunpowder. The injured

eye did not cause any inconvenience until a few years ago, when he began to work hard at his profession, that of an artist. It then became inflamed and painful, and the remains of the cornea ulcerated.

Soon after this, the right eye began to suffer sympathetically, and at last became so irritable that he could not read for more than a few minutes at a time, and was quite unable to follow his profession. I therefore removed a small portion of the front of the eye, and evacuated part of the vitreous humour, but the operation did not succeed as I had anticipated, for, as the wound healed, the irritation in the right eye returned, and soon became as bad as formerly. I therefore removed the eyeball altogether by dividing the muscles.

On examination, the cause of failure of the first operation was very evident, and, I think, very unusual. The retina had been detached from the choröid, (Plate XI. Fig. 4), probably long, prior to the operation, and had fallen forwards into the wound where it is firmly fixed and compressed, by being incorporated with the cicatrix, just as occasionally happens to the large nerves after amputation of a limb.

Mr. ROBERT TAYLOR, *3rd of November*, 1857.

---

2. *Pigment in the Tympanum.*

The specimen consisted of the left petrous bone of a man, æt. 50, who died from schirrhus of the stomach. The tympanum contained some thick mucus, which was of very dark colour, and interspersed with black patches, which consisted of pigment granules mixed with shrivelled mucus-cells. The membrana tympani had a dark appearance on its external aspect from the deposit on its inner layer. The right ear was healthy. No excess of pigment was noticed in other parts of the body.

Mr. J. HINTON, *19th of January*, 1858.

---

3. *Hæmorrhage supervening on the operation of Extraction; immediate Excision of the Eyeball; appearances found in the Dissection of the Eyeball.*

The patient, an elderly female, was admitted with cataract of the right eye (the left eye having been lost several years before), into the Moorfields Opthalmic Hospital, under the care of Mr. Bowman, and underwent the operation of extraction in October last. Nothing unusual occurred during the operation; but a few moments afterwards, bleeding into the globe took place, and the vitreous humour, shreds of retina, and blood were ejected through the corneal wound. It was quite evident that the eye was lost as an organ of sight; and, for various reasons, it was deemed preferable to remove it at once, rather than allow it to remain, and subject the patient to the painful and tedious process of suppuration of the globe. When the nature of her case had been explained to her, the patient at once acquiesced in the proposal. She was placed under the influence of chloroform, and the eye was removed. The wound healed rapidly, and she left the Hospital in a few days. Directly after its removal, Mr. Bowman entrusted me with the eyeball for examination. The following appearances were noted:—The globe was partially collapsed, but felt hard rather than flaccid. The greater part of the retina covered with clotted blood, was entangled in the corneal wound. The sclerotic and the choröid were widely separated by a large clot of blood, by which the latter membrane was pushed inwards towards the axis of the globe, and the ciliary nerves were embedded in the outer surface of the clot. The small space which was left in the centre of the globe, was traversed by a slender shred of retina, which connected the entrance of the optic nerve with the rest of the retina sticking in the conical section. These appearances seem to leave no doubt, that the vessels in the outer surface of the choröid are the source of the hæmorrhage, which sometimes supervenes on the operation of extractions; and they also explain the way in which the vitreous humour, and the retina are squeezed out of the eyeball. Almost all writers upon the subject have looked upon the arteria centralis retinæ as the source of the bleeding; and although some have hinted that the

bleeding may occasionally come from the choröid, yet, as far as I am aware, the actual source has not been hitherto demonstrated by dissection. Mr. J. W. HULKE, 19*th of January*, 1858.

---

4. *Malignant Growth within the Eyeball.*

The eye was removed from a healthy-looking child, æt. 2, of healthy parents and grand-parents. On the 5th of May, 1857, the child first applied at the Central London Ophthalmic Hospital for an attack of catarrhal ophthalmia, which yielded to ordinary remedies, and at that time no appearance of anything abnormal was observed in the eye itself. In November, 1857, the child was brought again to the Hospital, presenting all the well-marked symptoms of a morbid growth in the interior of the eye. The cornea and lens were both clear, the iris of a healthy blue-colour, the pupil widely dilated, the sclerotic being thinned around the cornea and of a slightly leaden colour, and the conjunctiva was somewhat congested. The eyeball hard and tense to the touch. A growth, reflecting a bright-yellow metallic colour was seen at the bottom of the eye, across which two or three large vessels were seen passing, even without the aid of the ophthalmoscope which was used, without revealing more than could be made out with the unassisted eye. Iron, cod liver oil, with occasional mercurials, were ordered till January, 1858, when fresh symptoms of irritation shewed themselves, and the growth rapidly increased with a commencing effusion of blood into the anterior chamber. Mr. Hulme removed the globe by Bonnet's operation on the 11th of June, 1858. No hæmorrhage occurred; the child left the Hospital two days after, and in a week had quite recovered from the effects of the operation.

On a vertical section of the globe being made, the humours of the eye escaped, the vitreous being quite fluid, and together with the aqueous, presenting a yellow colour, to which the bright yellow reflection was owing. A mass of a white, soft, cheesy-consistence (Plate XI. Fig. 5*a*) thickly intersected with earthy particles filled the whole of the posterior chamber of the eye, commencing at the entrance of the optic nerve, involving the whole of the retina, pushing forwards the hyalöid membrane and the con-

tained vitreous (Fig. 5*b*) and almost touching the posterior surface of the lens (Fig. 5*c*) which, however, remained perfectly transparent. Between the mass and the choröid, a grumous-looking fluid was effused. The choröid was deficient in pigment and somewhat thickened, and a whitish patch of the same character as the mass itself, was deposited between its layers, and a deposit of lymph was observed in the ciliary muscle; the sclerotic was normal in thickness except anteriorly, where it was slightly thinned.

Microscopic characters.—The mass consisted entirely of numerous ill-developed, irregularly-rounded cells (Fig. 6*a*) somewhat smaller than blood discs, some larger cells of the same character, filled with granular matter (Fig. 6*b*) and much free granular matter (Fig. 6*d*). The earthy particles consisted of phosphate of lime, with a trace of carbonate (Fig. 6*c*). The mass was not vascular, scarcely a trace of blood-vessels being detected. No trace of retinal-structure could be discovered. The optic nerve being divided close to the eyeball, its structure could not well be ascertained. From the above pathological and microscopic characters of the morbid growth, and from the total absence of any structure at all comparable to encephalöid, the growth was referred to that of a strumous or tubercular deposit; the child, however, was carefully watched, but about two months after the removal of the eye, a fresh growth re-appeared from the bottom of the orbit, which rapidly increasing, and the child's health somewhat suffering, Mr. Hulme (April 15th) removed the whole of the contents of the orbit; some slight hæmorrhage occurred which yielded to cold and a compress, and the child rapidly recovered from the effects of the operation.* The removed growth was mainly composed of small cells and nuclei, and it was only after a very prolonged and careful examination, that in one small spot around the common orifice of the orbital muscles, anything of a malignant structure could be determined upon. However, of the nature of this there could be no doubt; large, specific, ovöid, and pus effused cells, with nuclei and nucleoli, rendered distinct by acetic acid, and having all the characters of encephalöid were

* At present (June, 1858) the orbit is filled up with apparently healthy granulations, and the child is gaining flesh daily.

very clean, and a consequent unfavourable prognosis as to the ultimate result is to be feared.

This case is interesting, as shewing that while in the disease of the eyeball itself, no structure of an encephalöid nature was to be found, yet that in the recurrent disease, malignant microscopic characters could be clearly distinguished. It seems also to confirm an opinion given by Mandl (Académie des Sciences, May, 1857) and quoted by Sichel in the "Iconographie Opththalmologique, *viz.*, that "The cells, called cancerous, do not always and everywhere preserve the characters which authors have attributed to them. Cancer of the liver, of the osseous system and of the retina, are often composed of elements which differ essentially from the pretended characteristic type of cancer cells." The disease here described resembles in many points, and especially in its microscopic characters, a form described by M. Sichel in the "Gazette Médicale de Paris" (1857, p. 472) as pseudo-encephalöid of the retina, and figured by him in the "Iconographie Ophthalmologique (plate 65, Figs. 8—15). M. Robin who has reported micrographically on the cases, denies altogether the existence of such a disease, as cancer of the retina.

Mr. E. C. Hulme, *2nd of February*, 1858.

VIII.—TUMOURS, MORBID GROWTHS, CYSTS, ENLARGED GLANDS, ETC.

1. *Fibro-Plastic Tumour of the Humerus; containing Myelöid Cells, for which Amputation of the Shoulder-Joint was performed; recurrence of the Disease; Death three months after the operation. Secondary Tumours in the Lungs.*

M. A. P., æt. 43, the wife of a labouring man, mother of three children, the youngest five years old, was admitted into the Middlesex Hospital on the 8th of September, 1857. Her general health had been good, but for upwards of twenty years she had suffered from rheumatic pains in various parts of the body, which seemed latterly to have settled in the right shoulder.

About twelve months before her admission, she began to com-

plain of a dull heavy pain, apparently deeply-seated, in the right shoulder-joint, which at first was only felt occasionally, but was always increased by continued exertion. After continuing for six months, the pain had assumed a lancinating character, and as she expressed it, "frequently shot down to the tips of her fingers," having, during the last three months, become so severe as to prevent motion of the arm.

About two months since, she first noticed a swelling at the back part of the joint, which has gradually increased in size, and has extended all around, whilst at the same time, the pain has become more acute than ever, so as to deprive her of rest, either by night or by day.

The treatment until of late had, apparently, been directed to "supposed rheumatic inflammation of the joint," but having become an inmate of the London Hospital, she was advised to submit to amputation, which, however, she declined to do.

When received into the Middlesex Hospital, the shoulder was so exquisitely tender as almost to prevent examination, but it was found that the circumference of the right shoulder at the highest point at which it could be measured, was twelve inches, whilst the left was only nine inches; and a vertical measurement passed from the axilla and over the shoulder gave fifteen inches and three quarters on the one side, as against thirteen inches and a half on the other.

This enlargement was not uniform, for on the outer side, in the situation of the greater tuberosity, there was a hard boss or knob which was acutely sensitive. There was no glandular affection, or evidence of internal disease, but the patient's health was much deteriorated by her extreme suffering, and as the affection appeared to be limited to the Humerus, amputation at the joint was proposed, and readily assented to by her.

The operation was performed on the 10th of September, 1857, and presented no feature calling for observation except that there was an unusual facility in passing the knife across the joint for the purpose of forming the inner flap, arising, as was subsequently ascertained, from the fact, that the humerus had undergone spontaneous fracture just below its head, so that the knife had passed between the two surfaces of the fractured bone.

The remaining portion of the head was readily disarticulated, when the glenöid surface of the scapula and all the surrounding parts were found — so far as examination with the finger and by the eye could determine—to be perfectly sound.

Examination of the tumour removed by amputation.—The upper extremity of the shaft of the humerus was occupied by a tumour the size of an orange, nodulated, very firm, smooth, and covered with a layer of dense areolar tissue. A perpendicular section through the tumour and humerus, shewed that much of the growth was composed of dense osseous tissue, and the lower part of firm, whitish, fibröid substance, which shelved off towards the top of the growth. A soft, reddish substance occupied the medullary cavity, and extended into the tumour, but the smooth margin of the proper osseous boundary of the medullary cavity of the humerus, could be traced upwards into the tumour. The head of the humerus was reduced to a mere shell of bone, filled with the soft, reddish substance, through which its connection with the shaft had been broken just at the anatomical neck, but the external part of the head of the humerus was perfectly smooth and sound, and covered with cartilage.

Microscopical examination of ditto.—The external portion of the tumour, is composed almost entirely of fibro-plastic tissue, the major portion being made up of many white fibres, interlacing in all directions as in an ordinary fibrous tumour. Nuclei are very abundant, and are generally arranged lineally. The nuclei themselves are oat-shaped.

A few myelöid bodies are seen in those parts of the external portion of the tumour next to the bone.

The internal or soft portion of the tumour, situated within the head of the humerus, is highly vascular, so that under the microscope an enormous number of blood-corpuscles are seen. The tissue itself is composed almost entirely of myelöid bodies (Plate XI. Fig. 7), some of these being small, and more or less spherical, or ovöid, containing eight to ten nuclei. The majority, however, are much larger, presenting the most irregular shapes, and containing as many as twenty or thirty nuclei. A cell-wall is seen to surround many, but not all of the myelöid bodies.

The remaining portion of the soft tissue is made up of a

their long diameter. Some, however, are as small as one-third of this diameter, and others again are two or three times as large. The smaller nuclei are rather more spherical than the larger ones, which present greater irregularities of form. The smaller bodies (the nuclei) consist of a distinct cell-wall, and contain granular matter, with frequently one or two granules of large size, or perhaps a nucleolus. The larger bodies supported by the matrix are true cells, and consist of a cell-wall, and are irregular and frequently angular in form; and they contain usually a single, but sometimes more than one nucleus similar to those which are free. These nuclei sometimes contain nucleoli.

There are also many "fibro-plastic" cells and other cells, which approach in character to the fibro-plastic cell. These are extremely elongated cells, some being simply fusiform, but the extremities of others being fractured. They mostly contain a single oat-shaped nucleus.

In addition to the above varieties of cells, the "myeloid" bodies or cells are found in nearly all parts of the tumour. They are large masses of granular matter, in most instances surrounded by a distinct cell-wall, but the envelope cannot be demonstrated in all cases. The cells are subject to great varieties in form, the smaller of them being more or less ovöid, whilst the larger are much fractured after sending out long processes in various directions.

In the interior of these myelöid bodies there are numerous nuclei, varying in number from three or four to thirteen or fourteen; the nuclei are rather larger than blood-corpuscles, and are very granular.

Such is the general appearance of the firmer portion of the tumour from the scapula, but, in a few places, the matrix which was first spoken of, has a fibrous appearance, resembling connective tissue in the process of formation. Although the fibrous character is strongly marked in many situations, there is very little of the well-formed wavy tissue that was seen in the original tumour which was removed by operation.

The softer portions of the tumour.—The softer portions are made up of precisely the same elements as the firmer portion, these elements, however, are arranged in somewhat different propor-

tions. There is little, if any, of the fibrous structure, whilst the cells are in great abundance. The myelöid cells especially are numerous in the softer portions of the tumour (Plate XI. Fig. 8).

Ossifying portions.—The portions of the tumour which are the seat of calcification exhibit some little difference of structure, which appears to depend on the amount of fibrillation which has taken place in the matrix. In the places where the fibrous structure is well marked, the calcareous matter is deposited in the fibres, and the tissue has the appearance of being made up of a number of parallel cells of calcareous matter. In other places, which are chiefly composed of cells, the matrix is the seat of calcareous deposit, the cells apparently escaping from this degeneration, and remaining as spaces amid the calcareous material, standing therefore in the same relation to the osseous structure, that lacunal cells do to bone. No portions, however, exhibited any appearance of canaliculi (Plate XI. Fig. 9).

Tumours in the lung.—The tumours from the lung exhibit very little fibrous arrangement in their structure, but are chiefly made up of cells and tubes, similar to that in the shoulder. The "myelöid" cells are not so numerous or so large as those in the larger tumour. The osseous portion is, moreover, similar in structure to the tumour in the shoulder (Plate XI. Figure 10).

Observations.—The foregoing case is of great interest and importance in a surgical and pathological point of view, because it shews that the so-called "myelöid tumour" may run a course, which cannot be distinguished from that of the most malignant cancer. The microscopical examination of the original tumour, left no doubt as to the myelöid nature of the disease, and the surgeons present at the operation of amputation at the shoulder-joint expressed a confident opinion, that the whole tumour had been removed, together with the humerus to which it seemed to be exclusively confined. Notwithstanding this, in the course of eleven weeks, a similar tumour grew from the scapula, and after the patient's death, myelöid tumours were found in the lungs. The result of the case is disappointing to those who were inclined to accept the explanation, that those quasi-malignant tumours of the extremities in which amputation has formed a permanent cure, have in reality been examples of an innocent kind of tumour,

fittingly denominated "myeloid." Such tumours were first clearly described by Lebert, under the title of fibro-plastic growths; and the characteristic myeloid cells were described and figured in his plates, although he does not seem to have been aware that the cells are similar in appearance to the poly-nucleated cells of the marrow and diplöe of bones.

The case just related, as well as the one detailed by Mr. Hutchinson, in the last volume of the Society's "Transactions," shew that Mr. Henry Grey is in error in the conclusion to which he arrives in his paper on Myelöid Tumours, in the "Medico-Chirurgical Transactions," that they "are not malignant, and when entirely removed, never return;" indeed, two of the cases narrated by Mr. Paget, in the chapter in his "Lectures on Surgical Pathology," in which he first proposes the employment of the term "myeloid," would have seemed, *a priori*, to have thrown considerable doubt upon Mr. Grey's statement.

It is remarkable, however, that these myelöid cells should have been found in so many of the cases of amputation of limbs for supposed malignant disease, in which the operation is known to have been successful; but the question now arises, whether they indicate anything more than that ossific changes are occurring in a tumour? in which case they will be found indifferently in malignant and in innocent growths. Subsequent experience may enable us to determine the exact import of myelöid cells, but at present, it seems to me premature, to elevate a characteristic which may after all only be accidental, into the test of a radical difference in the nature of a tumour. For the present, I should prefer to retain the term fibro-plastic as originally employed by Lebert, and to add, if the fact were so, that the fibro-plastic tumour was associated with the existence of "myelöid cells."

I wish to express my sincere acknowledgments to Mr. Sibley for the careful microscopical examination which he kindly made of these tumours, and to Mr. Flower for his drawings of the appearances which they presented. The testimony of two such accurate observers is all that can be required to attest the correctness of the microscopial facts related above.

Mr. Mitchell Henry, 20*th of October*, 1858.

---

2. *Epithelioma* (?) *of the Female-Breast.*

A married woman, æt. 33, was admitted into the Samaritan Hospital, under the care of Mr. Spencer Wells, in November, 1854. She had had one child seven years before, and two miscarriages since. Eighteen months before admission she began to complain of pain in the right breast. It became hard, and the pain increased. When Mr. Wells first saw her in 1854, the breast was converted into a small, hard, moveable, uniform mass, not very sensitive on pressure, but extremely painful. A variety of treatment had proved useless, and Mr. Wells removed the breast at the earnest desire of the woman, on the 23rd of November, 1854. One gland in the axilla was swollen, but not hard. This was not removed. The wound healed by first intention. The swelling of the axillary gland disappeared, and the patient remained well for six months. Then a small tumour appeared near the cicatrix, which soon became painful. Uterine symptoms came on at the same time—namely, lumbar pains, flooding, and leucorrhœal muco-purulent discharge. She was admitted with these symptoms to the Middlesex Hospital, in September, 1855, and discharged relieved early in December. Two days afterwards she was admitted to the Marylebone Infirmary, complaining of cough, debility, and lumbar pain. Soon afterwards she noticed several small tumours, more or less painful, under the integument on the anterior part of the thorax. The number of the sub-cutaneous tubercles continued to increase, and in August, 1856, the cicatrix on the breast began to ulcerate. She believed that no tumour formed in the cicatrix before ulceration commenced. She remained in the Infirmary until re-admitted to the Middlesex Hospital in November, 1856, when she continued gradually to decline in health; the ulceration in the breast extending very slowly without any fungating growth from it, and she died rather suddenly, on the 5th of March, 1857.

Post-mortem examination, March, 7th.—Emaciation; but not extreme. Hard, round, sub-cutaneous tubercles on many parts of the trunk, not of the limbs. Much fluid in the pleural and pericardial cavities. Lungs congested. On surface of both lungs immediately under pleura, small, hard, white deposits, varying in

size from that of the head of a small pin to that of a mustard seed. Some rather larger in lung-substance superficially. In the substance of the liver were some scattered, round, white, opaque, hard, isolated tumours, which could not be enucleated easily from the surrounding liver-substance. On pressure they yielded a turbid white juice. Two or three similar tumours were beneath the mucous membrane of the gall-bladder. There was corrugation, with superficial ulceration of the cervix uteri, but no deposit in the substance of the uterus. Both ovaries enlarged, and hard from deposit. There were three tubercles between the arachnöid and dura-mater, but no deposit in the brain. Several hard nodules in left breast.

Microscopical examination.—Mr. Quekett made a careful examination of the primary tumour on the day it was removed. He foumd the gland-substance uniformly altered. The epithelial cells lining the ducts were altered into every variety of form; they were granular and very abundant, so that they distended the ducts and their closed terminations, and burst them in some places. After prolonged maceration in spirit and water Dr. Aitken reported, that careful microscopic examination, shewed that the alteration consisted in an abnormal condition of the secreting epithelial cells of the ducts, and of the lobules of the gland, involving the gland-substance of the whole organ. The secreting cells were altered from their spheröidal shape, and were seen in almost every variety of form, abundant, granular, and distending the acini. The morbid condition appears to have been entirely confined to the secretion of the ducts and the acini of the lobules. Neither in the mass, nor on section, did the mamma present any of the outward characteristics of a scirrhus tumour. The secondary nodules in the other mammary gland presented characters similar to the primary tumour in the right mamma, and appeared to involve only a few lobules of the gland. The secondary deposits in the other parts of the body presented elements of a granular character combined with minute cells, and sometimes fine filamentous tissue.

This tumour had been thought remarkable, and various views had been taken of the pathology of the disease. The primary tumour had been regarded as an example of the early stage of infiltrating carcinoma, and adopting this explanation, the occur-

rence of secondary deposits was to be expected. A second theory was, that the tumour was innocent, but that cancerous deposit took place in the cicatrix six months after operation, and that this was followed by secondary deposits. A third observer looked upon this case as a proof that mammary glandular tumours, known as a rule to be innocent, may occasionally exhibit a malignant tendency. A fourth pathologist was disposed to class the tumour with the *epitheliomata*, and to explain the distant multiple deposits by one form of putrid infection, which is not an unusual termination of degenerate epithelial disease.

Mr. SPENCER WELLS, *3rd of November*, 1857.

---

3. *Case of Osteoid Cancer combined with Myeloid Disease.*

This was the sequel of a case brought before the Society during the last session, by Mr. C. Forster, in which a lad had his leg removed for a soft, bony tumour growing from the head of the fibula.* G. W., æt. 18, was first admitted under Mr. Birkett's care into Guy's Hospital, on the 4th of March, 1857; he then had a large swelling on the outer side of the left leg, just below the knee; this was covered by numerous veins and had a marked encephalöid appearance. Permission for amputation was refused by the boy's friends, and he left the Hospital, but was re-admitted under Mr. Cock, on the 18th of May, when the limb was removed, the tumour having, in the meantime, become much larger, and presented to a still greater degree a malignant appearance; the lad was almost in a dying state, but rapidly recovered after the operation. The growth was seen to spring from the head of the fibula, and was composed of granular, amorphous bone, mixed with a white, soft material, which had the appearance of true cancer, and presented under the microscope a mass of nucleated cells; interspersed with these, however, were numerous poly-nucleated cells with branching processes, such as are styled myelöid. This fact made the case of especial interest, and its future history of great value as an element which is considered

* "Transactions of the Pathological Society," vol. viii. p. 389.

innocent, was found associated with a disease which could not be regarded otherwise than malignant.

At the end of August, the lad began to feel a numbness in his legs, and after this had continued a few days, he found that one morning he had completely lost the use of them, that is, the right leg and the stump of the left. On admission into the Hospital, on the 30th of September, he was completely paraplegic, he required the daily use of the catheter, and a bed-sore existed on the sacrum. He died on the 16th of October.

The *post-mortem examination* discovered no return of the disease in the stump, and all the organs were healthy excepting the lung and spine. The lower dorsal vertebræ were found infiltrated with cancer, the posterior parts of the bodies of the vertebræ were destroyed, and the same material surrounded the theca of the cord for some distance, and the medulla itself within was softened and broken up. The lungs contained each about twenty nodules, the largest of these being about the size of a marble, whilst others were smaller; they were round, with the exception of having a flattened surface towards the pleura. The composition of these tumours, as well as that of the soft material in the vertebræ, was identical with that of the tumour removed from the leg. They were of a red colour, vascular, and firm, but at the same time not so hard as to resist being crushed between the finger and thumb; they did not consist, as is sometimes seen in osteo-sarcoma of the lung, of fibrous tumours surrounded by true osseous cases, but they appeared as if a soft material, as cancer, had been intimately mixed with bony granules, and a soft, gritty mass produced. The microscope revealed the same structures in the lungs and spine, as it did in the original tumour; that is, there was much bony or earthy matter, which was amorphous, or consisting of tuberose particles, nuclei, and nucleated cells, which might very well stand for cancerous elements, and intermixed with these were myelöid cells. The latter were not numerous, and were only found after a careful examinatian, so that, probably, unless they had been especially looked for, they would have been passed unnoticed; it being, however, important to ascertain with certainty their presence or not, a diligent search was made, and thus undoubted specimens of this class of cell were found.

This case then tends to strengthen the belief that although, with all propriety, one form of growth may be designated innocent and another malignant; yet that between these two extremes there exist many others of different shades of malignancy, and that these may be variously combined.

Dr. S. WILKS, *3rd of November*, 1857.

---

4. *Fibro-plastic Tumour in the Calf of the Leg.*

J. M., æt. 50, a labourer, was admitted into Guy's Hospital, on the 14th of January, 1857, under Mr. Birkett. Two years previously, he was an out-patient under Dr. Hughes with renal dropsy, and perfectly recovered. One year prior to admission he scalded his right foot, with boiling pitch, and was disabled for four months, and at this time he noticed a swelling in the calf of the right leg, accompanied with great pain; this pain gradually subsided, but the tumour increased. When admitted, he presented a cachetic appearance, and complained of being out of health, no symptoms, however, of organic disease were present. In the lower part of the calf of the leg existed a firm oval tumour, firmly bound down to the deep tissues. It was punctured with a small exploring trochar and canula, and a few drops of blood escaped; the small amount of juice that came away in the canula was microscopically examined, and presented the appearances of the fibro-plastic tumour.

The man's health being indifferent, nothing was done, and he left on 16th of June. Upon the 7th of September, he was readmitted with improved health. The tumour had enlarged, and become very painful, the skin was inflamed, and it was thought probable that the tumour would soon slough out. Upon the 22nd of September, I amputated the limb, the chances of benefit, after excision being considered very small, some secondary hæmorrhage followed, and sickness which was subdued; the man, however, never completely rallied; upon the fourth day, he had rigors, and upon the ninth he died from pyæmia.

The tumour was about the size of an ostrich's egg, and to the eye appeared very cancerous, it cut firm, however, and failed to give upon pressure the ordinary cancer juice. It was corded by

dense bands into different lobules, and microscopically gave the cells and fibres which characterizes the fibro-plastic tumour.

Mr. THOMAS BRYANT, *17th of November*, 1857.

---

5. *Double Sub-Pericranial Cephalhæmatoma.*

Mrs. B., æt. 30, the mother of two healthy children, was confined of her third child on the 4th of June, a girl. She was in labour only a quarter of an hour, and the child was born before the midwife arrived, having two tumours on the top of the head. For these the child was brought to me on the 23rd of June, when, on examination, I discovered two soft, elastic, and somewhat fluctuating swellings, situated one on each side of the top of the head, corresponding to the lambdöidal suture. That on the left was the largest, and fully the size of a hen's egg. Neither communicated with one another, and pressure produced no effect on the child, who took the breast well, and was in every other respect healthy.

These tumours were about the same dimensions as at birth, and on careful examination, were found to be now apparently completely encircled by an osseous ridge, which seemed elevated, the tumour, as it were, lying in a sort of depression in the bone. So remarkable was this deception, that pressure was made to see if any influence could be exerted on the cerebral functions of the child, but it did not seem to experience any during the effort. The diagnosis, therefore, was a double sub-pericranial cephalhæmatoma.

These tumours were most carefully watched, and found not to increase further in size. On the 3rd of July they were a little softer, but not diminished in size; a few days later, that on the right side of the head became smaller, and by the 13th entirely disappeared without the slightest trace of it remaining, nor any evidence, such as even a slight elevation of the skull, to show where it had been.

By this time the left tumour was smaller, nearly solid, and with now very indistinct fluctuation. Three weeks later, it also had disappeared, without a vestige remaining of its former situation. The child's health was perfect throughout, and the disap-

pearance of these tumours was entirely spontaneous, no treatment being adopted. The first was completely absorbed in thirty-nine days, and the second in fifty days.

The formation of these tumours at the present day is pretty well understood, although formerly much difference of opinion prevailed regarding them. They are set down to compression of the fœtal skull during labour, by the edges of the os uteri, or sometimes, by pressure of the skull against the pelvic bones. The cause producing it, in the present instance, would appear to be slight, as labour took place in the short space of a quarter of an hour.

In Dr. Churchill's work on diseases of children, wherein this subject is well considered, he speaks of the contents of these tumours being of three kinds, either serous, sanguineo-serous, or purely sanguineous. In this child I think there can be no question but that it was the latter.

The extreme rarity of these tumours on the heads of new-born children may be imagined, when it is stated, that M. Dubois, during a number of years at La Maternité, in Paris (where nearly three thousand children are born annually), saw but six cases. Dr. Doepp, of St. Petersburg, found one instance in one hundred and ninety of the whole number of children in the Foundling Hospital, during eleven years. Velpeau refers to five cases, and Valleix met with four in five months in one thousand nine hundred and thirty-seven children, at the "Hôpital des Enfans Trouvés," in Paris. Three varieties of the tumour are described by writers:—the sub-aponeurotic cephalhæmatoma, the sub-pericranial, and the sub-cranial. The first of these is the simplest, but is said to be not the most common; the third is extremely rare; whilst the second, or sub-pericranial, appears to be the most common, although likewise very rare. I came across an example of the sub-aponeurotic form in 1843. Dr. Simpson, of Edinburgh, has seen a considerable number of these cephalhæmatomata,* and observes, that the only treatment required is time and patience. In watching the process of natural cure, he, several times, found a layer of bone formed on the inner surface of the separated pericranium which he says can sometimes be felt dis-

* "Edin. Month. Journ. of Med.," April, 1848.

tinctly to crackle under the finger like parchment, and as the fluid gets absorbed, the two plates of bone gradually approximate and come together. In relation to the sexes, Burchard mentions, that out of forty-three cases which he had observed at the Breslau Hospital, the child was male in thirty-four, and female in nine. Dr. GIBB, 17*th of November*, 1857.

---

6. *Tumours, probably Enchondromatous, of the Bones of the Hand.*

The forearm was removed by amputation, from an old man in the country, several years ago, and was sent up to St. George's

LIGN. 11.

This figure represents the lower portion of the radius and ulna, along with some of the extensor tendons, and the bones of the hand with attached tumours.
(Reduced not quite one-fourth.)

Hospital Museum. All that is known of the history is that he

had laboured under the disease for many years, but, probably, not since childhood; that it was considered malignant by most of those who saw it, and that the operation was considered by most of them, unadvisable, on account of the patient's advanced age, and the supposed malignancy of the disease. He, however, made a good recovery.

When I dissected the preparation, the hand had been immersed for many years in spirits. All the soft parts seemed healthy and some of the tendons have been left attached, in order to prove that even those parts which lay closest to the diseased tissue, had suffered merely from pressure, and were in no other way affected by the disease. The radius and the bones of the thumb appear healthy, almost all the others are affected by tumours, apparently of the same nature, but in different stages of development (Lign. 11). These tumours, where they are smallest, and apparently most recent, shew no trace of ossification; and resemble in all respects to the eye enchondromatous tumours. Microscopically, however, I failed to discover cartilage cells. The more advanced tumours are extensively ossified, and they have ulcerated on the last two fingers, exposing an extensive surface of porous bone. The joints are remarkably unaffected; even when the neighbouring bones are excessively enlarged, the articulation may still be found perfect. The disease affects principally the metacarpal bones and phalanges of the three outer fingers, but the bones of the wrist are also more slightly affected, and those of the forearm are expanded by deposit within their cancelli.

Mr. T. Holmes, 15*th of December*, 1857.

---

7. *Blood Cyst from the Thigh.*

This preparation exhibits the cyst of a tumour removed from the upper part of the left thigh of a young woman, æt. 25, by Mr. Prescott Hewett, at St. George's Hospital, in August last. She had been under the same gentleman's care four years previously, when a tumour had been removed from the same thigh, just above the popliteal space, which was taken to be of the fibro-plastic variety, and was said to have contained a large quantity of extravasated

blood. The present tumour had been growing for about two years; it was situated below the level of the inguinal glands, was about the size of an orange, and presented evident fluctuation. The history was, that the tumour had been of much smaller size, and apparently solid till a few days before, when it suddenly increased after a long walk, and when next seen was punctured, and bloody fluid evacuated. The patient was in very bad health, and, from her aspect, malignant disease was feared. The tumour soon filled after the puncture, and it was determined to excise it. The cyst was cut into, and a large quantity of sero-sanguineous fluid escaped, followed by clots of blood. The entire cyst-wall was then dissected out, in doing which the sheath of the femoral vessels was exposed. On examination, the membrane appeared to be of the simple fibrous character, and was separated here and there into two layers between which clotted blood was deposited.

The operation was followed by evident phlebitis in the affected limb, and by obscure symptoms of pyæmia, and an abscess formed in the opposite buttock, which, however, after being opened, healed, leaving the patient very weak, but with no distinct disease.

She recovered gradually, and was heard of a few days ago, perfectly well, and much improved in complexion and flesh.

Mr. T. Holmes, *15th of December*, 1857.

---

8. *Two Specimens of Fatty Tumour.*

The one weighing somewhat more than three pounds, was removed from the inner side of the thigh of a lady, æt. 48. It had been growing for seventeen years; five years ago an abscess formed in its centre and discharged its contents through numerous openings. These remained opened for two years, and during the last year the tumour has been the seat of severe pain, and the skin has ulcerated to a small extent on the most prominent part.

On section, the tumour shews the firm cicatrix of a perfectly obliterated abscess cavity.

The other tumour, weighing three pounds, was received from the Winchester County Hospital, it was removed from the shoulder

of a patient where it had existed for twenty years. Some time before its removal there had been a discharge of matter from two openings on the surface. On section, there is seen a large cavity with thick walls, which contained a quantity of purulent fluid, and has now a concretion of considerable size firmly attached to its inner wall.

Mr. Smith observed that these specimens afforded an example of a disease not uncommon in large fatty growths, and of two methods in which an ordinary abscess may terminate.

Mr. T. Smith, *2nd of February*, 1858.

---

9. *Epithelial Tumour of the Breast.*

This specimen occurred in a single lady, æt. 68, who had first noticed a lump in the breast in March, 1856. Mr. Arnott saw her in the beginning of July, and I am indebted to him for the history of the case. Half-way between the nipple and axillary edge of the mamma was an indurated mass the size of a flattened walnut, embedded in the breast and forming as it were part of it. The skin was not adherent to this, and the whole gland moved freely on the pectoral muscle. There was no enlarged gland in the axilla. Occasional uneasiness was felt in the breast, but the pain was not much complained of. The part was ordered to be covered with cotton wool, and the case to be watched. Mr. Arnott, saw the patient again three months afterwards. The swelling had greatly increased in size, namely, to that of an orange, and had become softer. It bulged at two parts, as if about to burst, and the skin over it was red at these places, where the swelling felt as if it contained fluid. Immediate operation was urged, and on the 14th of October, the entire mamma was removed. The patient continues well up to the present time, February, 1858.

On section, the tumour presented a soft pultaceous mass, which was more or less surrounded by an indistinct fibröid capsule. The tumour was about the size of an orange; the soft mass was found to consist almost entirely of large epithelial cells, varying somewhat in shape, but mostly flat and polygonal. There was scarcely any fatty matter mixed with the epithelium.

Remarks.—Epithelial growths are generally said to occur only

on surfaces covered with perfect pavement epithelium, such as the skin and mucous membranes; but, Rokitansky found an epithelial tumour, enclosed in a fibrous capsule, in the substance of the liver, and I am inclined to consider this tumour of the breast as belonging to the same rare class of epithelial growths occurring in the substance of organs. The history of the case, I think, precludes the idea of the tumour having originated in a sebaceous cyst, for it is distinctly noted that the growth was at the first felt in the substance of the breast, and was not connected with the skin; and the contents of the tumour did not exhibit the greasy appearance of sebaceous matter. Dr. Van der Byl, *2nd of March*, 1858.

---

10. *A congeries of very large Cysts containing Milk, developed in the Breast.*

A healthy, married lady, had been the subject of a tumour in the right breast for eight years, when my friend, Mr. Kellock, requested me to meet him in consultation as to the propriety of its removal. I found a very large mass occupying the site of the clavicular half of the gland. The fluctuation of fluid was very distinct on its anterior surface, but solid masses could be felt here and there dispersed over its lateral regions. The history, as given by the patient, was as follows:—About nine or ten years since, she struck the right breast violently against a window-sash which produced considerable ecchymosis. Some time after this injury she accidentally observed, eight years since, a small hard lump which slowly increased, was painless and caused no trouble. She married, and the first child was born about a year after the discovery of the tumour, and was suckled partially with the affected gland. A third child was born in July, 1856, and about a month before this the right breast became suddenly larger within twenty-four hours, and the skin over the upper half became red, painful, and hot, accompanied with pyrexia. This affection subsided in a few days after constitutional and topical treatment, but the increased size of the tumour was persistent.

Mr. Kellock had seen the case six months before this, and then the tumour was globular and hard, but the fluctuation of fluid was distinct in a portion of it. After parturition, milk was

secreted abundantly by the breast, but the infant was not suckled with this gland.

During the fourth month of pregnancy and subsequent lactation for four months, no very marked alteration, except increase of size, took place.

I removed the growth and a very small portion of the clavicular lobes of the breast, to which it was very firmly adherent. Some thick milk still remained in the ducts of that part of the breast which was cut. The new growth consisted of several cysts, a

1st May 1858

LIGN. 12.

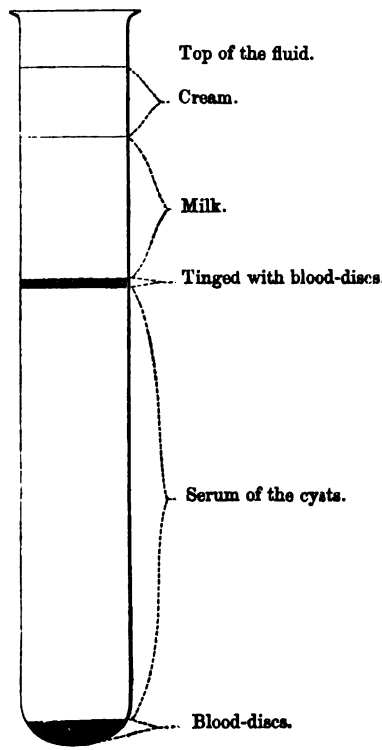

This figure represents a Test Tube, containing some of the fluid contents of the cysts, separated by subsidence into its component parts.

very large one with which all the smaller cysts communicated, and

several small masses of imperfectly developed gland tissue, or adenoceles in the walls of the principal cysts. The cysts contained a fluid composed of milk and the secretion of their lining membrane, in quantity measuring one quart. The fluid, after remaining some days in a large test tube (Lign. 12), separated into cream, the serous portions of milk, and the secretion of the cysts, a thin stratum of blood discs subsiding at the bottom. The cysts had strong, fibrous walls, and were lined with a smooth, glistening membrane, like a mucous membrane. The adenoceles resembled loosely-developed gland tissue, the lobules being very much separated from each other, or rather very loosely joined together by connective tissue. Most of them communicated with the principal cyst and, if they enjoyed the function of secretion, they must have poured their secreted fluid into this reservoir.

The pathology of this disease I believe to be as follows:—

1. A new growth of more or less perfectly-developed gland tissue; being the primary tumour first observed—an ordinary adenocele.

2. A secretion of milk by this growth which, as the fluid could not escape, collected in the spaces between the lobes of the new growth and thus formed the cysts; being the intermediate stage observed by Mr. Kellock, of a hard and solid mass, and a globular portion in which he felt the fluctuation of fluid.

3. The slow secretion of milk distending the cysts, produced the very large tumour I removed, and gave rise to the separation of the lobes of the primary growth to such an extent from each other as to lead to the supposition that they were rather appendages to the walls of the cysts than the cysts or reservoirs for the milk were to them. In this case the serum of the milk had not become absorbed or there would have been, in place of so large a collection of fluid, a mass of white substance, like cream-cheese, contained in a cyst, such as I have described and delineated in the "Guy's Hospital Reports," Vol. I., p. 139, year, 1858.

Mr. Birkett, *4th of May*, 1858.

---

11. *A Case of Carcinoma Fibrosum, or Scirrhous Cancer of the Breast, with Cysts containing Serum mixed with Blood.*

Cysts containing serum of various colours depending upon the

admixture of the colouring-matter of the blood are not uncommonly seen in association with hard or fibrous cancer. There appear to be two distinct varieties.

Firstly. That in which the cysts are central, and the carcinoma infiltrates the peripheral portions of the lobes of the secreting part of the organ.

Secondly. Another in which the central part of the organ is infiltrated, and the cysts are peripheral. This is the most uncommon, and the preparation exhibited, afforded a very good illustration of the disease. In both varieties, more or less fluid can be generally expressed from the nipple, but I never yet met with a case in which the formation of the cysts was so clearly a development secondary to the infiltration of the central part of the gland with cancer.

A healthy-looking woman, the mother of five children, the last born three years and five months since, when, in her thirty-sixth year of age, accidentally observed in the left breast, a small, hard lump. She had just before weaned the last child when she noticed it. I saw the case for the first time when it had been growing one year and seven months. There was infiltration of the axillary and abdominal lobes. The tumour was hard, not very painful, and the integuments over it quite healthy. The nipple was not retracted, but somewhat fixed. I saw the patient from time to time, between August, 1857, and May, 1858, when I removed the disease. During this time, sero-sanguineous fluid oozed from the ducts at the nipple, the entire mass of the organ became infiltrated, and several cysts containing fluid became developed upon the surface and periphery of the gland. At the time of operation, the fluid only came from one duct. Having improved the general health of the patient, and as the disease was quite circumscribed, and the axillary lymphatic glands free from disease, I removed the whole tumour and gland. The integuments were not in the least infiltrated, nor was there any disposition evinced by the growth, to become adherent thereto.

Upon the anterior surface of the breast were several cysts, one or two of which had burst during the operation. They all contained the same sero-sanguineous fluid, which was identical with

that which had been oozing from the nipple. On the posterior surface, and along the borders of the gland, cysts of a similar nature were developed. Nearly the whole of the central part of the breast was infiltrated with cancer, and was converted into a mass of carcinoma fibrosum, or scirrhous cancer, through which the traces of the ducts could be distinguished. These remnants of the ducts were so compressed as to prevent any escape of fluid through them. All the cysts were lined with a smooth, bright membrane, but their internal surfaces were irregular, from the existence of small fossæ and septa extending upon them, something resembling the bands extending across bursæ mucosæ.

It appears to me that in this example we have a very good illustration of the mode in which some of the cysts which exist in association with cancer are developed. At first, the disease was not sufficiently advanced to prevent the escape of fluid from the ducts, but as larger tubes became compressed by the central infiltration of the gland, this secretion not being able to escape, collected in the small tubes, and by gradual dilatation of their walls the cysts became formed.

8/

Mr. Birkett, 1~~8~~th *of May*, 1858.

---

12. *An uncommon variety of Cystic Disease of the Breast.*

The patient from whom I removed the growth, to be described below, was 61 years old, when she first observed a small lump among the clavicular lobes of the right breast. This was punctured about a year and a half after its discovery, when thin, tenacious, blood-tinged fluid escaped through the canula. When I first saw this patient, she was in a most cachectic condition, never having enjoyed good health.

The growth had been in progress of development four years and a half when I was first consulted, and these were its characters. Upon the surface of the right breast, there was a series of cysts, in which fluctuation was distinct. The whole gland was very moveable, pendulous, and heavy. The disease was immediately beneath the skin on the surface of the breast, and did not appear to extend deeply into the gland. The skin over the part was red, thin, but neither adherent to the growth nor infiltrated. No

complaint of pain was made, but the weight of the tumour was annoying, and its very existence created much mental disturbance. In about six months after my first examination, the growth had nearly doubled its size, one cyst had inflamed, the skin over it ulcerated, and it was quite clear that great trouble would speedily ensue. As the axillary lymphatic glands were uninvolved, the constitutional powers of the patient as good as usual, and the practicability of easily enucleating the disease very manifest, I removed it with the assistance of Mr. Richard and Dr. Stocker. Little hæmorrhage occurred, and the disease and breast were detached without in any way interfering with the surrounding parts, indeed, they seemed to be more than usually circumscribed by a well-defined fascial envelope.

The wound healed most favourably, and the patient perfectly recovered within the average period of time, although, judging from her constitutional condition, and especially her aspect, none but the most untoward results might have been prognosticated.

The mass removed consisted of the whole gland, the new growth, and that portion of the integuments which, during the last three months of its growth had become firmly adherent to its anterior surface. Altogether the mass weighed half a pound. The growth occupied the site of the sterno-clavicular lobes of the breast. The abdominal lobes were intact, but formed rather an appendage to the growth, than the growth to them; that is, the gland-tissue was about a fourth of the size of the new growth. The growth and the remaining part of the breast were closely blended together, and the ducts from the nipple ran into the gland-tissue. This gland-tissue resembled the ordinary appearance of the organ at this age. On the surface there was a round hole in the skin, which covering was very thin. The edges of this hole were quite smooth, and very little inflammatory action was observable around them, or in them. It looked as if a piece of the skin had been cut out with a punch. This led into the cyst which had ulcerated three days before the operation. A deep depression indicated the site of the nipple, which was below the ulcer.

The new growth consisted of an assemblage of innumerable independent cysts with delicate membranous walls which varied

in size from an inch and a half in diameter, the largest, and by imperceptible degrees diminished to almost indistinguishable minuteness, at least to the unaided eye. These cysts contained a material which varied in colour and consistence. The largest and the smallest were the most translucent, and contained a yellowish or pinkish gelatinous substance, which projected from the cyst when the cavity was opened, but was firm and tenacious and not easily torn away. The red tint wherever appearing, seemed to depend on an admixture of extravasated blood, which here and there formed little patches. Minute capillary vessels ramified on the walls of the cysts.

The cysts of medium size contained a yellowish, dull, opaque, soft substance, which was not succulent, but moist and of sufficient consistence to resist considerable pressure and tearing.

At the posterior surface of the preparation, the blending together of the new growth and the gland-tissue was most apparent, and here might be traced, step by step, the development of the cysts in the connective-tissue of the gland, and the septa thus formed between them until they became entirely lost in the general mass.

The opaque substance was composed of nucleated cells with long bands of wavy, filamentous-tissue.

The gelatinous substance exhibited scarcely any structure, but here and there were aggregations of oil-globules, and traversing it, without any particularly definite arrangement, a most delicate and sparingly-developed fibre-tissue.

Is this disease carcinoma? I submitted it to the scrutiny of Dr. Wilks, who writes thus:—"I do not see how any growth having such a vascular matrix and simple cell-formation can be called otherwise than medullary cancer. I should think it deserved the name."

Before, however, consigning it to this category, I prefer to watch the progress of the case, and to report the results to the Society at a future meeting.

Mr. Birkett, 18*th of May*, 1858.

---

13. *Five Cases of Tuberous Cancer of the Breast illustrating the Natural History and Progress of the Primary Growth.*

Circumscribed masses or tubers of carcinoma are not so commonly met with in the breast, as that variety of the new growth which infiltrates the connective tissue of this organ. The five cases to be related shew many circumstances in remarkable opposition to each other, whilst in others, there is a very constant similarity; and I propose, therefore, in these observations to contrast the cases with each other. There was a difference of twenty-two years between the extremes of age, the youngest patient being thirty-eight years when the growth was first observed, the oldest sixty years. The intermediate ages were forty-five, forty-seven, and fifty-six. With one exception, the social condition of these parties was good. Two of them were single, three married, and of these two were prolific, one sterile. All had enjoyed very good health except one, and none of them had observed, nor could they recall any deviation from their usual state of health before they noticed the primary growth. The catamenia were persistent in three of the cases at the time of the development of the growth, and in one only this function was always attended with very great constitutional disturbance; in two, the catamenia had ceased several years before, but had been always normal. In two patients the mammary glands were well-developed and had very little fat interspersed between the lobes; in two, they were very large and the adipose tissue had been developed at the expense of the glandular structure, of which there was scarcely any remaining. Lactation had been perfectly performed with the affected organ in two persons. No previous disease or injury had affected the breast in either of the cases, but in one, unusual pain in these glands preceded the catamenia. By four, the primary growth was observed accidentally, and in one, pain drew attention to the part. The growth was developed among the abdominal lobes of the breast in two instances, among the axillary in two, and between the clavicular in one. The ages of the growths varied considerably at the time they were excised; they were as follows:—nine years, four years, one year and six months, nine months, and five months. The skin became involved in the

disease at very different periods; in the nine years' growth in eight years and a half; in that of four years' growth in three years and a half; in the eighteen months' growth in a year; in the nine months' growth in eight months; and in the five months' growth in three months. In no case was the nipple involved in any way. The development of the growth was attended with more or less pain in proportion to the susceptibilities of the individuals, but in the two firmest, shooting and darting pains were experienced. In only one case an axillary lymphatic gland was enlarged. At the time of the operation the general health of the patients was very good. In only one case was there a history of hereditary predisposition to cancer. In all the cases the sufferers were unable to assign any cause for the development. Although the growths were all of them tubers or circumscribed masses of carcinoma, yet they differed widely in their degree of firmness. Their capability of resisting laceration by pressure seemed to depend upon the amount of fibres or connected tissue developed in the mass. In one, a collection of dark brown fluid had formed between the growth and the skin which structure being thin, a bluish or purplish appearance over the seat of the disease was produced. In two, the tuber had advanced to the integument and produced ulceration of this structure. Continuing to grow, a large, sprouting, fungating, bleeding-mass was developed from which a very offensive, sanious discharge continually poured forth. The surface of this mass was superficially gangrenous, and was not divisible into lobes and lobules. Its root or pedicle was attached to the borders of the ulcerated opening in the skin.

Lastly, I may add that four of the patients inhaled chloroform, and that the wounds in these healed favourably without an untoward symptom.

Case 1.—The patient was 45 years old, when she accidentally observed a small hard lump in the left breast. She had given birth to two children and suckled with the affected breast. The catamenia were persistent and always normal. Her social position was good and comfortable, and her temperament calm, patient, resigned, and cheerful. The constitutional powers were good, and the general health unimpaired.

The growth which was observed four years before its removal, commenced as a small hard lump, slowly increased, became adherent to the skin which was red from congestion of its vessels, and slightly in relief. The nipple was never affected.

None of the lymphatic glands in either the axilla or above the clavicle were infiltrated. Shooting pains were occasionally felt, but they were never severe.

The mass of carcinoma which I removed, measured about three inches in its longest diameter, and was about one inch and a half deep. It was developed between the lobes of the gland which were pushed aside by it. The skin over the growth for about an inch was infiltrated. A little contraction had taken place in the centre of the tumour, and posteriorly it was slightly adherent to the pectoralis major muscle.

Case 2.—The patient, was 47 years old, when she accidentally observed a hard lump among the axillary lobes of the left breast. She was single, had always enjoyed good health and the catamenia were persistent. In a social position of great comfort, she had not any mental anxieties to impair her constitutional powers which were very good. Although rather nervous, she had considerable command of feeling, and much fortitude.

The growth which was observed one year and six months before its removal, began as a well-defined, hard lump among the axillary lobes. It increased rather rapidly after a few months, approached the skin which ulcerated, and then a pedunculated, sprouting, fungating growth was developed, which projected in relief nearly two inches and measured three inches in diameter. A serous fluid escaped profusely from its surface occasionally tinged with blood. The nipple was not affected by the growth. Before the development of the fungus an axillary lymphatic gland was distinctly enlarged, but it subsequently diminished.

No pain was experienced in this case. Her mother was said to have died of cancer of the uterus.

The disease which I removed was pedunculated, and grew out of the breast, without infiltrating the lobes of that organ. Slight contraction had taken place posteriorly and the tumour was adherent to the pectoralis major muscle.

CASE 3.—The patient, was 60 years old ,when she first observed, accidentally, a small, moveable lump, deeply-seated among the clavicular lobes of the right breast. With the exception of a slight disposition to the development of senile fat, she was healthy-looking, fresh-coloured, and in the enjoyment of good health. Although married young, she was sterile. The catamenia had ceased several years, but they had been always normal. Actively employed during a considerable part of life, she was in the enjoyment of great social ease and comfort. Her health was always good, and her disposition cheerful, calm, and hopeful.

The growth was observed nine months before its removal, and from the substance of the breast it seemed to grow towards the skin. It was soft in the centre, but its base and circumference were firm and hard. The vessels of the skin over it were congested. With a trocar and canula, I punctured the centre, and withdrew sufficient of the growth to establish the fact that it was carcinoma by means of the microscope.

The nipple was small, but not affected by the growth. The lymphatic system of the breast was not affected. Occasionally, an intermittent aching, and latterly, darting pains were felt.

The disease which I removed consisted of a circumscribed growth of soft carcinoma, which was developed between the lobes of the gland and surrounded by a well-defined, although delicate envelope. The skin was not diseased.

CASE 4.—The patient was 56 years old, when she first accidentally observed a small hard nodule immediately beneath the skin on the axillary lobes of the left breast. She had given birth to several children and suckled them with the affected breast. Her general health had been always good, but she was now very obese, and constitutionally not very strong. Of a cheerful and happy disposition, her mind had been latterly much harassed, but she was in comfortable circumstances. The catamenia had ceased several years and they were always normal.

The growth was observed five months before its removal. From being at first hard, it had become of late soft in the centre, with induration at the base and circumference. Fluctuation was

distinctly perceptible beneath the centre of the thinned and red integument.

The nipple was not affected. The lymphatic glands were free from disease. No pain was felt, but a sensation of heat and heaviness.

The disease which I removed was a growth of soft carcinoma, developed upon, rather than between, the lobes of the breast. There was a very delicate fibrous envelope. An effusion of serum mixed with blood existed between the anterior surface of the tumour and the skin, which last structure was very thin and nearly disorganized. In a very short time it would have ulcerated and allowed the escape of the fluid.

Case 5.—The patient was 38 years old, when she felt a lump in the right breast; her attention being attracted to the part by pain. She was single, the catamenia persistent, regular, but its return attended with great constitutional disturbance. Her occupation was that of a governess, and she was nervous, excitable, and undecided. The constitutional powers were good and the general health unimpaired.

The growth which was observed nine years before its removal, commenced as a small hard lump, increased very slowly, and became adherent to the skin, which was then red and raised. About fourteen days before its removal the skin ulcerated, and a bleeding fungus grew out of the opening, became very offensive and discharged freely. The nipple was never retracted during the course of the growth of the disease.

The lymphatic system was free from disease. Great pain had attended the progress of the growth—more than usual.

The disease was removed, but I had not the opportunity of examining it. Its nature was, however, sufficiently characteristic whilst upon the sufferer.

Mr. Birkett, 18*th of May*, 1858.

---

14. *Chondro-Osteoïd Growth among the Muscles of the Posterior Femoral region; Excision; Cure.*

A healthy, married woman, æt. 30, had a tumour growing in

the posterior region of the inferior third of the left thigh, about two years and three months. It was clearly beneath the fascia, was not attached to the femur, and measured about five inches long by three inches broad. It gave very little pain, but was becoming inconvenient from its size. It seemed to occupy the region of the short head of the biceps and to be identified with it. The growth was cut out on the 16th of February, 1858, by a single vertical incision, and its enucleation was effected without difficulty. It measured, in its length and breadth, four and a half inches, by three inches. The surface was slightly irregular from small elevations, in low relief, and its colour throughout, about half an inch of the circumference, was a greyish-pearl tint. It was so hard in the centre that a saw was required to make a section. About two-thirds of the central part of the mass consisted of bone, densely compact in some parts, somewhat cancellated in others. The remainder was composed of cartilage, but the union of these two tissues was not well defined. A delicate envelope of fibre-tissue surrounded the whole mass.

In Aug. 1/60 to return.

The wound healed, and the patient left the Hospital well. The preparation is in the Museum of Guy's Hospital.

Mr. Birkett, 18*th of May*, 1858.

---

15. *A large Fibro-plastic Tumour, connected with the upper extremity of the Humerus.*

J. W., æt. 30, a short, rather cachetic-looking man, was admitted into Westminster Hospital, in February, 1858, under the care of Mr. Holthouse, for a hard solid tumour, which was situated beneath the left deltöid muscle. It was accompanied with a constant throbbing, darting pain, which varied in intensity and sometimes extended to the whole limb; it was painful on pressure, and the patient was unable to raise the arm, partly, perhaps, from paralysis of the deltöid muscle, and partly because the attempt to do so increased the pain. The shoulder-joint was unaffected, and the head of the Humerus could be rotated in the glenöid cavity, or pressed into it without causing pain. The patient stated that last August he began to experience pain in the limb when using it; a few weeks after which he fell down a

cellar, and struck the same arm, but said, he did not hurt himself, and only felt a little shaken. In the beginning of October the pain became more constant and severe, and obliged him to give up his work. He was then admitted into one of the Borough Hospitals, where it was surmised he had aneurysm, no swelling of the arm or shoulder having at this time made its appearance. He remained in the Hospital five weeks, and left it much improved, being able to raise his arm, which he was unable to do on his admission. A fortnight after his discharge he again fell down, striking his arm in the same place, and was again admitted into the same Hospital where he remained eight weeks and was then discharged without benefit. Some time after this the swelling began to take place, and he then became an out-patient of the Westminster Hospital, but as the swelling rapidly increased in size, he was made an in-patient, and on the 23rd of February, the arm was removed at the shoulder-joint. He went on well for some days after the operation, and then sloughing of the stump took place, followed by an attack of acute pleurisy, which carried him off on the evening of the 30th.

The *post-mortem examination* revealed no other disease than that just mentioned; no aneurysm was found, and no secondary deposits existed in any of the viscera, which were healthy.

Description of the tumour.—The tumour occupied the two upper fifths of the humerus, and extended slightly into the shoulder-joint. It was oval or roundish in form, slightly nodulated on its surface, and the exact structure in which it originated, could not be satisfactorily determined. On making a vertical section of the bone, the disease was seen to occupy the medullary cavity, where its characters were modified by the situation, and it extended lower down this cavity than externally, so as to occupy its upper three-fifths. On tracing the edges of the sawn bone upwards through the tumour, we arrived at a point near the centre of the mass where a fracture or breach of continuity existed, and a short distance above this point the bone could no longer be distinguished from the surrounding diseased structure, into which it was either converted, or by which it was replaced.

Mr. Paget, who examined a section of the tumour, pronounced

it to be of the recurring fibröid kind, both in its microscopic, and larger characters, and he found no structure characteristic of cancer. Mr. Christopher Heath, 18*th of May*, 1858.

IX. DUCTLESS GLANDS.

SUPRA-RENAL CAPSULES.

1. *Cancerous Deposit in the Right Supra-Renal Capsule. Left one normal. No Bronzed Skin.*

A female, æt. 62, died in King's College Hospital, on the 7th of October, 1857, from the effects of cancer in various parts of the body. There were extensive cancerous deposits in the liver and right lung; and there was also a tumour, the size of a large orange, in the posterior and inferior triangle of the right side of the neck, which involved the vessels of the arm, and also the brachial plexus of the nerves, and which, during life, had produced intense shooting-pains along the course of the nerves, and great œdema of the corresponding arm.

The right supra-renal capsule was about four times the normal size. This was partly owing to an increase of the pulp; but principally, to a cancerous mass, the size of a large Spanish chestnut, presenting the usual structure of medullary cancerous tissue, and involving about two-thirds of the organ. The left supra-renal capsule was of normal size, and apparently healthy. On microscopic examination, an immense quantity of free oily-matter was observed in the cortical portion, and the cortical cells were also loaded with oil.

There was nothing abnormal as to the colour of this woman's skin, except that it was pale and anæmic.

Dr. Murchison, 3*rd of November*, 1857.

---

2. *Living Specimen of a Rat from which both the Supra-renal Capsules and the Spleen had been removed.**

Dr. Harley shewed to the Society a living, and apparently healthy, white rat from which he had extirpated the supra-renal capsules and spleen, when it was only a month old, and not much larger than a good sized mouse. The animal is now upwards of four months old, and notwithstanding the absence of the above-named organs, it has grown big, and is to all appearance quite healthy. Its functions seem to be well performed. The hair and skin too, retain their white colour. Dr. Harley in the presence of the Society, opened another rat from which he had removed the spleen, and the left supra-renal capsule, six weeks ago, and the right supra-renal capsule within the last fourteen days. The latter animal met with its death accidentally.

Dr. Harley, *3rd November*, 1857.

---

3. *Diseased Supra-renal Capsule, Removal by Operation from an apparently healthy Animal.*

Having procured in the latter part of February, three grey and white (piebald) rats, I selected the largest and strongest for operation. After the animal had been rendered insensible by æther, I cut down on the right supra-renal capsule, and was much surprised at its unusual size, and it was removed with some difficulty, in consequence of its close attachments to the kidney. On examination after removal, it was found to be at least four times its normal bulk, it weighed 4·247 grains. On section and microscopic examination, it proved to be the seat of very extensive tubercular deposit. The day following the operation, the animal's respirations were very laboured, and about 70 in the minute.

It gradually got worse, and at length the breathing became almost entirely abdominal. From the third day after the operation, each respiration was accompanied by a harsh sound. The

* This case and the following one, (although this would otherwise have been introduced amongst the Specimens from the Lower Animals), have been introduced here as bearing upon the interesting question of the effects of Disease of the Supra-renal Capsules upon the animal economy.—Ed.

animal did not appear to suffer any pain, except what arose from the difficult breathing. On the sixth day (that on which he died) it was exceedingly restless, and seemed, every now and then, to be in a state of impending suffocation. Once or twice it was observed to have slight convulsive twitchings all over its body. Notwithstanding, that it had symptoms of some grave pulmonary affection, on *post-mortem* examination, the lungs and air-passages were found perfectly healthy; the lungs were collapsed in the chest, but floated freely in water. Both sides of the heart were full of blood. All the abdominal organs were engorged. The left supra-renal capsule shared the congestion, but was otherwise healthy. The urine contained albumen. No marks of disease were anywhere to be found, except in the neighbourhood of the solar plexus. This point seemed to be the seat of tubercular deposit, in the middle of which was a harder mass, of similar constitution, of about the size of a split-pea, probably a lumbar gland. The right semi-lunar ganglion was completely covered by the diseased mass. Now comes the important question. What was the cause of the animal's death? Was it the absence of the diseased capsule, or the injury done to the semi-lunar ganglion? Most probably the latter. I have elsewhere* shewn that animals may live and thrive after removal of both supra-renal capsules, and even the spleen too; and that when they die after extirpation of these organs, it is in the majority of cases in consequence of the injury done to the neighbouring parts, more especially to the ganglionic system of nerves.

Dr. George Harley, 17*th of November*, 1857.

---

4. *Scrofulous Disease of the Supra-renal Capsules.*

Both capsules were greatly enlarged, especially the left one, which measured transversely, nearly three inches and a half, while it was about an inch in thickness throughout its whole extent. Although the right was scarcely more than half the size of the left capsule, it was, nevertheless, much larger than natural, and on section, was seen to have entirely lost its normal colour and consistence. Its substance, which was unusually firm, and of a

* "British and Foreign Med. Chir. Review," January and April, 1858.

uniform dirty-white hue, presented a somewhat lobulated aspect, without the slightest trace of any normal, medullary, or cortical substance being distinguishable. The left supra-renal body was of a quadrilateral shape, and very much less dense than its fellow. On section, it presented the ordinary yellowish-white colour and consistence of "crude tubercle." Towards the middle and lower margin of the organ, the substance was much softer than elsewhere, and on gentle pressure being applied, a white, milky-looking fluid escaped from the cut surfaces. None of the dark, medullary, or yellow cortical tissue could be detected by the naked eye. The fibrous capsules of each of the glands were considerably thickened, and especially that of the left, which was, in some places, three or four times thicker than usual.

Microscopical examination.—After the glands had been hardened in strong spirit, scrapings and thin sections from various parts of them were examined with the microscope, and it was found that the normal, medullary tissue had totally disappeared from both capsules, its place being occupied by the ordinary elements of tubercular deposit. A similar remark is applicable to the cortical substance with the single exception, that at one or two points there were a few broken-down cells, which, from their size and colour, might be regarded as the remnants of the normal secreting structure. These cells, however, were so few in number and so fragmentary, that they scarcely deserve even this passing notice, and it might be affirmed without any hesitation, that there was entire destruction of the proper texture of the organs.

For the above-mentioned specimens, I am indebted to Drs. Mackenzie and Sanderson. The case from which they were taken occurred in the practice of the former, and the *post-mortem examination* was made by the latter of these gentlemen.

Dr. Mackenzie has kindly furnished me with the following notes:—"The patient was a poor woman, æt. 33, of a strumous constitution, and although married for many years, had never had children. About eight years ago, she consulted me on account of general ill-health, anæmic dyspepsia, and slight uterine derangement. The liver was enlarged and tender. Under a course of mild alteratives and tonics, she perfectly recovered. For many years she continued in good health, but about five months ago,

she again applied for medical advice, on account of excessive anæmia, weakness, and emaciation. The liver was found to be again enlarged. She was again treated with alteratives and tonics, but without deriving any benefit. The patient was, therefore, sent to the country to try the effect of change of air, but after a fortnight's absence she returned, worse than when she went. Looking to the peculiar sallowness of the skin, which I had previously imputed to hepatic derangement, I was led to suspect the existence of disease of the supra-renal capsules. On applying galvanism to the spine, the patient complained of very marked pain when the positive pole of the battery was placed over that part corresponding with the seat of the supra-renal capsules. The patient gradually got worse, and died."

Post-mortem examination, from notes kindly furnished by Dr. Sanderson. "General surface of skin opaque. Rather of the tint called dusky or freckled brown, than of a bronze colour. This, although not marked, was sufficiently so by comparison with the former complexion which was remarkably clear and colourless, as to attract her own attention and that of her friends. Several irregular dark patches existed on the chest, one much darker than the rest at the lower portion of the sternum.

"Thorax and head not opened.

"*Abdomen.*—All the organs adherent to each other, and to the abdominal walls by strong bands of lymph. Liver large, highly congested, soft, and easily broken down. One or two miliary masses of tubercle found on its anterior surface. Spleen large. Lymphatic glands somewhat large and congested. Uterus adherent to peritoneum. Right ovary bound down by strong adhesions to the posterior walls of the uterus, and attached to a cyst containing a pultaceous material similar to that found in the supra-renal capsules."

Remarks.—This case is of considerable interest on account of the length of time the patient was under observation, and of the very advanced state of disease of the supra-renal capsules. It is not improbable that the affection of the latter organ began about the time when the patient first applied to Dr. Mackenzie for advice, namely, eight years ago. From the microscopical appear-

ances of the organs, it cannot be doubted that they must have ceased to perform their normal function for a long period before death, and consequently, one cannot help feeling surprised, *if the theory of bronzing of the skin from suppression of the supra-renal capsular function be correct* (?) that the discoloration of the skin was in this case so slight as to have been for a long time attributed to hepatic derangement.

Dr. George Harley, 17*th of November*, 1857.

---

5. *Scrofulous Deposit in the Supra-renal Capsules.*

The patient, a man, æt. 43, was admitted into St. George's Hospital, on the 5th of August, 1857, he had had an abscess connected with diseased sternum for seventeen years, but with this exception, his health had been good till last Christmas, when he began to complain of pain in making water, aching pain across the loins, and retraction of the testicles. When admitted, he complained of pain in the region of the kidneys and along the course of the uretus. The urine was healthy. He had no cough or expectoration, but was low and depressed, with feeble pulse and loss of sleep. He was ordered wine and sedatives. No particular change was noticed in him till the evening of the 9th, when he was noticed to be purple in the face and short of breath. He gradually sank, without any complaint of pain or distress, and died early next morning.

On *post-mortem examination*, the sternum was found perforated by disease, but there was no pus in the anterior mediastinum. There was extensive tubercular deposit in both lungs, and a vomica in each apex, the larger of which would contain a walnut. No disease was detected in any part of the urinary system. Both supra-renal glands were enlarged, the left was the size of the right. Their natural tissue seemed quite gone, and was replaced by a white, firm parenchyma, in which was a copious deposit of crude tubercle, softened in places.

The skin was of a dark, dingy colour, especially on the hands, face, and legs. In the latter parts the colour was of a yellowish-brown colour, more resembling bronze in the parts exposed to the light, but this was thought to be merely an effect of exposure to the

sun. The skin was not examined microscopically. The abnormal colour of the skin had attracted notice during life.

Mr. T. Holmes, 1*st of December*, 1857.

---

6. *Two Supra-renal Capsules of a remarkably unusual form, and occupying a very unusual position. Substance of these Organs healthy.*

These specimens shewed the two kidneys and their supra-renal capsules *in situ*. The latter were very closely adherent to the kidneys, and were with difficulty separated from them, being

Lign. 13.

This figure represents the kidney of the right side, with its attached supra-renal capsule; the extremely flattened condition and misplacement of the latter are well shewn.

united by a quantity of firm, dense, connective-tissue. Instead of being, however, above, and, as it were, capping the kidneys, they were placed in apposition with the upper portion of the anterior

surface of the respective kidneys, their upper margins scarcely appearing above the upper tips of those organs, and their lower margins reaching to the hilus of the kidneys. But in addition to this alteration in position, the capsules were exceedingly flattened, and so thinned, that in parts their edges were not thicker than a piece of pasteboard. They were also very firm, as if from compression (Lign. 13).

Microscopical examination shewed that the tissue of the organs was, however, not altered.

History.—The specimens were removed from the body of a boy, H. S., æt. 15, who died in St. George's Hospital from pyæmia, abscesses in the lung and liver, etc., in connection with disease of the bone. The kidneys were of a very pale-yellow colour and coarse character. There was nothing unusual as regards the vessels of the kidneys, ureters, etc. There was no bronzing of the skin.* Dr. JOHN W. OGLE, 1*st of December*, 1857.

---

7. *Extensively Cirrhosed and Fatty condition of the Supra-renal Capsules. Absence of any Bronzing of the Skin. Softening of the Left Cerebral Hemisphere. Hemiplegia of the Right Side.*

The specimens consisted of two supra-renal capsules, removed from the same patient. They were very unusually large, and greatly thickened, and of a pale gamboge colour. Their outer surfaces were very roughened and nodulated, the colour between the elevations being paler than other parts, and in some places almost quite white. The investing areolar tissue, which was remarkably abundant and firm, was very adherent to the surfaces of the organ. On section, the capsules proved to be, throughout, very unusually indurated and consolidated, and there was a total absence of any central space or of any obvious distinction between a lighter-coloured cortical, and a darker-coloured medullary part; indeed, throughout their entire thickness, these viscera presented one uniform character as to colour and consistence, the sectional surface being everywhere of the same yellow colour as the outer surface, and shewing a mottled and granular appearance. One of

* A preparation consisting of one of the kidneys and its supra-renal capsule is now in St. George's Hospital Museum.

the capsules, which were very nearly equal in size, weighed as much as two drachms and thirty-six grains.*

Microscopical examination of the supra-renal capsules.—The substance of these organs was seen to be extensively affected by fatty deposit. This existed in a granular and molecular form in almost every part of the tissue, as well as in the form of drops of various dimensions, in the large oval cells of the organ; scarcely any of the cell-structure could be found free from the presence of much fat. But, besides the fatty matter, almost every part of the organ shewed the presence of a considerable quantity of opaque fibröid material, obscuring considerably the ordinary and natural minute characteristics of the organ, which did exist, for the most part, if not entirely, although in a shrunken and contracted condition, and the general matrix of the organ seemed greatly increased. Here and there, very unusually large, round, and oval, opaque bodies were seen, which appeared to consist of some of the ordinary cells bloated and distended with granular fatty molecular material. In some places, the cells retaining their parallel arrangements, were seen to contain large lustrous yellowish-coloured drops of oil-like matter. In but few cases could I discover anything like a nucleus in the cells. I did not observe that the blood-vessels of the organ presented any unnatural appearance.

History.—These organs were removed by me from the body of a man, æt. 62, who was brought into St. George's Hospital, having, eight days previously, had a "fit," attended by loss of consciousness and followed by hemiplegia of the right side, and incomplete power of articulation. A slight degree of power in the leg was regained, but facial paralysis and loss of speech still remained. After a time the patient became affected by severe attacks, in which both arms moved convulsively, and he fell into a half comatose state, which was interrupted by attacks of noisy delirium. Before death very extensive bed-sores were formed.

Post-mortem examination shewed very considerable softening of a large part of the left cerebral hemisphere, extending from the surface deeply to the lower part of the optic thalamus and corpus stria-

* I have generally found that the weight of the supra-renal capsule in the healthy adult varies from about sixty-five to ninety grains.

tum. There was also extensive disease of the kidneys, and a collection of matter behind one kidney, which appeared, from the sinuous passages and sloughing existing in the neighbourhood, to be owing to extensive bed-sores, from which the inflammation had spread into the parts within the abdomen. No diseased bone in the neighbourhood was met with. The heart was natural, excepting some atheromatous deposit in the coronary arteries, and the substance of the mitral valve flaps.

Microscopical examination of the softened brain shewed a vast number of so-called compound exudation capsules, besides the other ordinary appearances met within brain broken down by inflammatory processes.

Remarks.—Two points there are of special interest in this case. *Firstly*, the entire absence of any bronzing of the skin, although the supra-renal capsules were so very far from being in a natural healthy condition; and *secondly*, the peculiar condition of these organs.

I have ventured to apply to the affection of the capsules, the term cirrhosis, not only from their general appearance, their colour, induration, and nodulated state, etc.; but also, from the minute microscopical characters presented by them. If I am not much mistaken, their condition was one much allied to that of the liver, as it is frequently found when about to become contracted and hob-nailed, and no doubt exists that the supra-renal apsules had been in this state for some time. I am inclined on the whole to suppose, that the extensive fatty state had preceded the disposition of the granular and fibröid matter, although it might be, that in some degree the fat was formed by secondary changes in the exuded fibrinous material.* As far as I know, this peculiar form of disease has hitherto not been noticed in the supra-renal capsules, but its existence is rendered very probable, when we remember the gland-like histological nature of the organ. Hitherto, for the most part, we have heard of merely fatty states of the organ, deposits of scrofulous and cancerous matter, and calcareous degenerations, most probably of effused products. There is obviously no reason why these capsules

* This change of fibrinous into fatty material was well seen in the case of a supra-renal capsule which I exhibited to this Society on a previous occasion, see vol. vii., p. 177, of the "Transactions."—J. W. O.

should not be affected by any of the various diseases to which the viscera in general are obnoxious.

As regards the extensive lesion of the brain causing death, and other circumstances connected with the case, I will not here discuss them, inasmuch as my object is merely to draw attention to the peculiar condition of the supra-renal capsules and the absence of any attendant skin bronzing.

Dr. JOHN W. OGLE, 1*st of December*, 1857.

---

8. *Extensive Scrofulous Deposit in the Supra-renal Capsules; Death by Acute Pulmonary Phthisis; Absence of Bronzed Skin.*

The specimens of diseased supra-renal capsules were removed from the body of a man, æt. 35, who was admitted into University College Hospital, under the care of Professor Walshe. The general history of the patient presented nothing peculiar. He died very shortly after his admission, from acute miliary tuberculization of the lungs. Both supra-renal capsules were greatly hypertrophied. The measurements of the one were three inches broad, two inches high, and one inch and a quarter thick; and of the other, one inch and a half broad, two inches high, and three quarters of an inch thick. Both organs were very firm to the touch, and on being cut into, presented the ordinary appearances of a mass of crude tubercle. No trace of any normal structure was visible to the naked eye.

Microscopical appearances.—The medullary substances in both of the capsules was *entirely* replaced by tuberculous deposit, and the central sinuses were completely obliterated. The cortical was almost in the same condition as the medullary substance; only here and there could any trace of the characteristic columnar cell-masses be detected. The minute fragments of cell-masses were chiefly found towards the circumference of the organ, and were very imperfect, in consequence of the tuberculous deposit having encroached upon them. Judging from the extent of the diseased condition in the different parts of the organ, one might be led to suppose that the medullary substance was the part first attacked by the tuberculous deposit, and that afterwards the disease extended into the stroma of the cortical substance, and gradually advanced upon the columnar cell-masses, pushing them

outwards, and separating them from each other, and lastly, that as the deposit of foreign matter increased, the walls of the cell-masses were broken down, the loculi by degrees filled with tubercle, and that at length the proper secreting cells of the organ almost totally disappeared.

The chief points of interest in this case are the absence of all signs of bronzing of the skin notwithstanding the diseased condition of the supra-renal capsules; and the fact that, though the patient was an adult, those capsules must have been tuberculized for a considerable length of time before any similar deposit was laid down in the lungs. Dr. Harley, *5th of January*, 1858.

---

9. *Bronzed Skin; one Supra-renal Capsule Diseased.*

M. V., a woman, æt. 81, was admitted into the St. Marylebone Infirmary, in the beginning of February, 1858, with chronic bronchitis, recently aggravated. This gave way to treatment in about a fortnight, and she then appeared to be exempt from any particular symptom of disease for a week or thereabout. She was then rather suddenly attacked with partial coma, and some little return of bronchitis, and died in about twenty-four or thirty-six hours after the onset of the attack on the 28th of February. For the last year of her life, the skin of the entire body, that of the face and hands only being excepted, had exhibited a bronze tint, which is now very deep. The colour is darkest on the lower part of the trunk, where it is indeed a deep brown.

Post-mortem examination.—The organs are all tolerably healthy in appearance, excepting that the kidneys are somewhat congested, and that the supra-renal capsule of the right side is obviously much changed from the natural appearance; the left appears healthy. The capsule in question is yellow in colour, and scarcely distinguishable by the naked eye, in tint or consistence, from the surrounding fat. On making a section of it, the same yellow, greasy appearance pervades the whole of the organ. Under the microscope a portion of its structure exhibits highly refracting globules in great abundance, undoubtedly oil, some granular matter, and a little fibro-cellular tissue.

A piece of the integument exhibited, is a specimen of the

mean tint, and shews the colouring-matter permeating the substance of the true skin.

Mr. Henry Thompson, *2nd of March*, 1858.

---

10. *Limited Disease of the Supra-renal Capsules in a Lunatic. Bronzing of the Skin.*

A. H., a semptress, æt. 45, single, was admitted into the South Devon Asylum, on the 4th of May, 1857. She had been insane previously to admission, during five months.

On admission, she was excited and inclined to be violent, she had many delusions, saying she was bewitched and the like. She was of middle stature; her countenance was pale, with a slightly sallow tinge. Tongue clean, pale, and flabby. Head hot, lower extremities cold. Appetite good. She was very restless at night. The subsequent notes of her case were as follows:—

May 17th.—She is to day observed for the first time to have convulsive movements of the body and lower extremities.

June 4th.—Her mind is weak and childish. The skin on her face and hands have become very dark. She has not menstruated since her admission. Her appetite is voracious.

20th.—Appetite not so ravenous. She is weaker, and is becoming emaciated. Her skin is now of a brownish-yellow colour, darker below each clavicle, and at the bend of the arms. She continued to become more emaciated and weaker until July the 11th, when she had a marked attack of apoplexy with much convulsive movement, and she remained insensible for three days. The power of deglutition being much impaired. She slowly rallied and gained strength. Her skin continued of the same dark colour. She went on improving until September the 20th, when she had another attack of apoplexy. She was insensible for three hours. Her head was hot, and her face flushed. Six leeches were ordered to be applied to the temples.

The skin over her body, face, arms, and hands, is now as dark as that of a mulatto, but having a decidedly yellow tinge. Conjunctiva very clear.

February 17th.—She has become very much emaciated, her hands are tremulous; and when she speaks she jerks her head

backwards and forwards. To-day she has had another apoplectic attack; she is quite insensible and motionless.

24th.—She has remained insensible and died to-day.

Post mortem examination, thirty hours after death.—The body was much emaciated and bloodless. The skin which during life was observed to be of a dark brown colour is now much lighter, in some places of a natural hue. The calvarium of normal thickness, but discoloured with vascular congestion, is very unsymmetrical in shape, the right parietal protuberance being much more prominent than the left. The left side of the skull is longer than the right, so that the occipital region on the left side projects half an inch beyond that on the right. The dura mater discoloured with yellowish-brown discolorations in the vertical region and base, but more especially about the foramen magnum. The arachnöid translucent and healthy; a small amount of subarachnöid fluid. The pia mater greatly congested, its larger vessels gorged with blood, its smaller ones displaying ramiform congestion. The grey matter is redder than usual. The white matter presents brownish-pink discolorations and numerous red points on section. The lateral ventricles are normal. Soft commissure very firm. The vessels at the base healthy. Cerebellum congested like the cerebrum.

Weight of brain 48 ounces.

Specific gravity of the white substance	. . .	1040
,, ,, ,, grey matter	. . . .	1038
,, ,, ,, cerebellum	. . . .	1040

The heart and lungs healthy.

The liver is healthy but small; the gall-bladder full.

The spleen small and contracted, and of firmer consistence than natural.

The stomach and bowels are healthy. The kidneys healthy.

The parietes of one of the supra-renal capsules presented, on section, several yellowish granules in size from a pin's head to a hemp-seed. These granules had somewhat the appearance of tubercles. The microscope shewed them to be composed of fragments of softened fibre and of fatty particles. The corresponding capsule presented similar appearances but in a less degree. Dr. QUAIN for Dr. BUCKNILL, 16*th of March*, 1858.

11. *Two Supra-renal Capsules affected by Scrofulous Matter, and taken from a patient who had died of Phthisis and Pneumothorax.*

The supra-renal capsules are the seat of a very extensive deposit of crude tubercle, which, however, has not entirely absorbed their natural structure, a small part at the top being still unaffected.

The skin was covered in several places with small roundish blotches of a dark-brown hue, which affected the epithelium only, and after a little maceration became hardly perceptible. Microscopical examination shewed no alteration in the structure of the deeper parts of the skin.

The cartilages of the knee-joint were also ulcerated. The right kidney was healthy; the left contained a large strumous abscess, and two small calculi were fixed in one of the infundibula. No deposit was found in any of the lymphatic glands.

Mr. T. Holmes, 16*th of May*, 1858.

---

12. *Disease of the Supra-renal Capsules, without Bronzed Skin.*

The specimen consisted of the supra-renal capsule of a man, æt. 51, who died of dropsy and desquamative nephritis, after an illness of many months' duration. The skin exhibited the extreme pallor often seen in Bright's disease. The medullary substance of the capsule had disappeared, leaving a cavity which contained some small fatty, and *calcareous* masses. Here and there the cortical substance was so thinned, so as to leave little more than a delicate lamina covered by the investing fibrous tissue of the gland. Both supra-renal capsules were in the same condition, and equally affected. Dr. Brinton, 4*th of May*, 1858.

---

13. *Bronzing of the Skin, in a Boy, with old Disorganization of both Supra-renal Capsules.*

A boy, æt. 11, tall, thin, and emaciated, was taken by his father to Dr. Risdon Bennett's out-patients'-room at the Victoria Park Hospital, on Thursday, April 15th, 1858. He was stated

to have been losing flesh for some time, and getting weak, but he had had no acute symptoms nor any indications of pulmonary mischief. He had walked to the Hospital, a distance of more than two miles, and after having been prescribed for he walked home again, without making any complaint of unusual fatigue. Dr. Bennett, and Mr. Couzens (the House-Surgeon), both recognized at once, from the lad's complexion, the nature of his disease. His face presented a most marked condition of bronzing, the colour being diffused over the whole surface, but darker in some parts than others. In the centre of the forehead was a patch, of very dark tint indeed, about the size of a halfpenny, and the edges of which gradually shaded into the surrounding and less deeply-tinged integument. The whole surface of the body and extremities were discoloured, but not so dark as the face, excepting on the backs of the hands, and on the sides of the knees. On the sides of the knees especially the skin was very dark. There were a few faintly-marked, but indelible streaks on the mucous membrane of the lips, as if caused by light touches with Indian Ink. The conjunctivæ were pale, and, on careful examination, no indications of disease within the thorax could be detected. As to the duration of the bronzing, the lad's father stated that it had become very much more marked within the last few weeks, but for some time his neighbours had been suggesting that the boy must have the jaundice, and he thought some of these remarks had been made nearly as much as six months ago. He had not considered the lad ill until quite lately, and even up to the present time the boy had been accustomed to play about almost as usual with other children.

Whether from having been over-done by his long walk, or from other cause, is not clear, but on the day following his attendance at the Hospital the boy was taken seriously ill. He had some slight diarrhœa, with sickness, and afterwards a series of convulsive seizures. After being confined to bed for about a week, he died on the 27th of April, 1858. During the last week of his life, he had been attended at his home by Mr. Edmund Bletchley, of the City-road, who at once recognized the true nature of the case, and to whose kindness I was indebted for an opportunity of seeing the corpse, and for an account of the post-mortem.

On *post-mortem examination*, the brown colour of the skin was still exceedingly well-marked. There was but little fat in the sub-cutaneous tissue, or in any other parts. A careful examination of the thoracic and abdominal viscera was made, but, excepting in the mesenteric glands and in the supra-renal capsules, no morbid conditions were discovered. Many of the mesenteric glands were enlarged to the size of marbles, and contained cheesy-matter, encapsuled in very dense or even osseous parietes. These deposits resembled in every respect tubercle which had softened, and was now undergoing absorption. In none of the glands was tubercle in a recent stage of progress found. Both supra-renal bodies were totally disorganized, containing chalk, cheesy-matter, and firm fibrous structure, binding together these elements. No trace of their normal tissues was discoverable, nor was there any softening, or evidence of recent inflammation. The disease was evidently in process of spontaneous cure, and had existed for a very long time.

The above case appears to me to be an exceedingly important one. In the first place, because the patient is, I believe, one of the youngest on record, as having died of the supra-renal cachexia, and in the second, because three medical men had separately, guided by the tint of the skin, diagnosed the lesion found at the post-mortem examination. Its chief value is, however, in proving that disorganization of the capsules may be complete, with but very little of either constitutional disturbance, or cutaneous discoloration. Eventually, however, the stage of debility does ensue, and if life have been sufficiently prolonged the bronzing also. No pathologist could doubt, but that the supra-renal capsules had been disorganized for a very long period. All active processes of disease had ceased, and there remained only the masses of dry cretaceous deposit, which evidenced the absorption of what, in all probability, had been fibröid or tubercular infiltration. To judge from analogy, a year at least must have been expended in bringing about those changes, and for that period the lad must have lived on without any discharge of their functions on the part of these organs. Yet, what had been his state of health during that period? His father averred that he had been quite well until within a few weeks of his death, and in support of this assertion,

was the fact, that he had throughout been accustomed to play about as other boys do, and that only ten days before death he walked a distance of four miles. As to the discoloration of the skin, a very confused account was given. It was clear, however, that it had only been noticed a few months; to one questioner, the father stated only a few weeks. Now, let us suppose, that at the period at which the organs were first destroyed by disease, they had instead been extirpated by a physiological investigator. At the end of six months, the case would have been vaunted as proof that the capsules are not vital organs, that good health may be preserved without them, and that bronzing of the skin does not follow their loss. Does not the case prove that much more patience is requisite in arriving at trust-worthy conclusions on these points from experiments on the lower animals, than has yet been exercised? I have at present under my care, a woman in whom the bronzing has been marked for at least three years, yet she still lives on, and her constitutional symptoms are not of such marked character, but that a biased observer might declare her to be in fair health. Were she a rat, whose capsules had been extirpated, I have no doubt she would rank as healthy. Should the post-mortem examination prove, what I have no doubt that it will, we shall have an instance of life with tolerable health, prolonged for a period of at least three years after total disorganization of the capsules. Three years out of the life of a human subject, is, probably, at least equivalent to the longest period that any of the lower animals have survived the extirpation of those bodies. Mr. Jonathan Hutchinson, *4th of May*, 1858.

SPECIAL REPORT

Upon the various Specimens of Disease of the Supra-renal Capsules, exhibited to the Society during the last Session.

A Committee having been appointed at the commencement of the Session for the purpose of examining and reporting upon the various specimens exhibited to the Society, illustrative of diseases

of the supra-renal capsules, the following Report was drawn up by that Committee.

"In carrying out the wishes of the Society, we have to state that we have carefully examined all the specimens which during the past session were brought before the notice of the Society. Taking each specimen separately into consideration, and in order according to the date of its exhibition, the result of our investigation, which had reference to the actual pathological condition of the organ was as follows:—

CASE 1.—Account of a white rat from which the supra-renal capsule had been removed; also of another rat, from which the supra-renal capsule and the spleen had been removed during life, etc. Dr. HARLEY, *3rd of November*, 1857.

Description of Specimen confirmed.

CASE 2.—Cancerous deposit in the right supra-renal capsule. Dr. MURCHISON, *3rd of November*.

Description of Specimen confirmed.

CASE 3.—Diseased supra-renal capsule removed by operation from an apparently healthy animal. Dr. HARLEY, *17th of November*. *Description of the Specimen confirmed.*

CASE 4.—Scrofulous disease of the supra-renal capsules. Dr. HARLEY, *17th of November*.

Description of the Specimen confirmed.

CASE 5.—Scrofulous deposit in the supra-renal capsules. Mr. HOLMES, *1st of December*.

Description of the Specimen confirmed.

CASE 6.—Excessive fatty condition and induration of the supra-renal capsules. Dr. JOHN W. OGLE, *1st of December*.

Description of the Specimen confirmed.

CASE 7.—Scrofulous deposit in the supra-renal capsules. Dr. HARLEY, *5th of January*.

Description of the Specimen confirmed.

CASE 8.—One supra-renal capsule diseased. Mr. HENRY THOMPSON, *2nd of March*.

With regard to this Specimen the Committee regrets to say, that they could not report with any satisfaction to themselves, as it was so very decomposed. On immersing it in spirit, there appeared to be, what might be termed, degeneration of the

various parts of the organ as the columnar-looking portions of the cortex were narrowed and shrunken, and seemed to contain much granular and fatty matter. More than this could not be made out.

CASE 9.—Two supra-renal capsules affected by scrofulous deposits. Mr. HOLMES, *16th of March.*

General description of the specimen confirmed; but on submitting parts of the discoloured spots of the skin to microscopical examination, portions were seen in which the lower layers of the epidermis contained a brownish-coloured pigment.

CASE 10.—Limited disease of the supra-renal capsules. Dr. QUAIN, for Dr. BUCKNILL, *16th of March.*

The Committee did not look upon the supra-renal capsule in this case as diseased. A very slight degree of fat was found in part of its texture, but, probably, such an amount is seldom or perhaps never absent from the supra-renal capsules, especially in those who have lived long in towns.*

CASE 11.—Disease of the supra-renal capsules. Dr. BRINTON, *4th of May.* *Description of the Specimen confirmed.*

CASE 12.—Old disorganization of both supra-renal capsules. Mr. HUTCHINSON, *4th of May.*

Description of the Specimen confirmed.

The Committee have to state, that after examining the individual specimens, they passed on to the full consideration of the various histories connected with them. This was entered upon with especial reference to the question of the presence or absence of that very peculiar colour of the skin, which has received the name of "bronzing," and which has been supposed to be owing to some disease of the supra-renal capsules. The following classifications of the ten cases above-examined, arranged in a tabular form (the cases of the lower animals being excepted), will indicate the conclusions respecting them, at which the Committee arrived regarding the coincidence of bronzing of the skin with organic changes in the texture of the supra-renal capsules.

The under-mentioned four cases, were those in which disorganization of one or both capsules was associated with some bronzing of the skin.

* This supposition is grounded on the results of the examination of a number of supra-renal capsules in healthy people by Dr. John W. Ogle.

TABLE A.

No.	Date of Exhibition.	Name of the Exhibitor.	Age Sex of the Patient.	Colour of the skin.	General state of the affected Capsule.	Whether both Capsules were involved or not?	Were the affected Capsules wholly destroyed?	General Condition of other Organs.	No. in foregoing Report.
1	Nov. 17.	Dr. Harley.	Woman aged 35.	"Peculiar sallowness of the skin." "General surface of the skin opaque; rather dusky or freckled brown." Several irregular dark patches on the chest; one much larger than the rest at the lower portion of the sternum.	Capsules greatly enlarged and diseased; one containing much scrofulous material.	Both capsules involved.	No natural medullary structure left; and only very slight traces of any of the cortical parts.	Disease of the liver. Results of Peritonitis.	4
2	March 2.	Mr. Henry Thompson.	Woman aged 81.	The skin of the entire body, except the face and hands, exhibited a bronze tint, which, on the lower part of the trunk, was a deep brown colour.	One Capsule much changed and scarcely distinguishable from the surrounding fat as to its colour or consistence; shewing great degeneration of the various parts, the columnal portions being shrunken and containing much fat and granular matter.	Only one of the capsules affected, the other being healthy.	The natural structure of affected capsule was quite destroyed.	Kidneys congested.	8
3	March 16.	Mr. Holmes.	Man aged 40.	The skin was covered in several places with roundish small blotches of a dark brown hue, becoming hardly perceptible after a little maceration.	Capsules almost entirely destroyed by scrofulous deposit.	Both capsules were equally involved.	The whole of the organs destroyed except a small	Strumous abscess of the kidney. Calculus of the kidney.	9

No.	Date of Exhibition.	Name of the Exhibitor.	Age. Sex of the Patient.	Colour of the skin.	General state of the affected Capsule.	Whether both Capsules were involved or not?	Were the affected Capsules wholly destroyed?	General Condition of other Organs.	No. in foregoing Report.
4	May 4.	Mr. Hutchinson.	Boy aged 11.	Skin affected by the most marked condition of bronzing; darker in some places than others. The whole surface of the body and limbs discoloured.	Capsules containing chalk, cheesy-matter, &c.	Both capsules equally involved.	part at the apex of each end, which was still unaffected The whole of both organs totally disorganized.	Many of the mesenteric glands were large and contained cheesy-matter surrounded by an osseous shell.	12

In the following five cases in Table B there was more or less extensive disease of one or both of the supra-renal capsules; but, during life, bronzing of the skin had been noticed as *absent*.

TABLE B.

No.	Date of Exhibition.	Name of the Exhibitor.	Age. Sex of the Patient.	Colour of the skin.	General state of the affected Capsule.	Whether both Capsules were involved or not?	Were the affected Capsules wholly destroyed?	General Condition of other Organs.	No. in foregoing Report.
1	Dec. 1.	Mr. Holmes.	Man aged 43.	The skin was of a dark, dingy colour, especially of the face and hands and legs, where it most resembled bronze; but this was thought to be merely an effect of exposure to the sun.	The capsules were enlarged and occupied by scrofulous matter.	Both capsules were affected.	All the natural tissue of both capsules was gone.	Scrofulous deposit in the lungs and vomicæ.	5
2	Dec. 1.	Dr. John W. Ogle.		The skin was normal as to colour.	The capsules were of a light gamboge colour, and very large and heavy. Their structure was very indurated, and found to contain a large quantity of fat, granular matter and fibröid material (Cirrhosis).	Both capsules were equally affected.	In both capsules, in some parts, the natural tissue could be made out, but it was much shrunken and occupied by fatty matter.	Softening of the brain. Disease of the kidney.	6
3	Nov. 3.	Dr. Murchison.	Woman aged 62.	The skin was devoid of any unnatural colour.	The capsule was very greatly enlarged, and considerably affected by cancerous material.	Only one capsule was affected. The other was healthy.	Not wholly destroyed.	Cancer of the lung and liver.	2

No.	Date of Exhibition.	Name of the Exhibitor.	Age. Sex of the Patient.	Colour of the skin.	General state of the affected Capsule.	Whether both Capsules were involved, or not?	Were the affected Capsules wholly destroyed?	General Condition of other Organs.	No. in foregoing Report.
4	Jan. 5.	Dr. Harley.	Man aged 35.	There was an absence of all bronzing of the skin.	The capsules contained a quantity of scrofulous matter.	Both capsules were equally affected.	To the naked eye there was no trace of normal structure in either organ.	Scrofulous deposit in the lungs.	7
5	May 4.	Dr. Brinton.	Man aged 51.	Skin shewed only the pallor of the skin often met with in Bright's disease.	Medullary substance gone, leaving a cavity containing some small friable calcareous masses. The cortical substance was here and there so thinned as to leave little more than a delicate lamina, other parts being of good thickness.	Both capsules were equally affected.	Much of the cortical parts gone in both capsules.	Disease of the kidney.	11

The following case in Table C afforded an instance of bronzing of the skin, which had been *un*accompanied by any important disease of the supra-renal capsules.

TABLE C.

No.	Date of Exhibition.	Name of Exhibitor.	Age. Sex of the Patient.	Colour of the skin.	General state of the affected Capsule.	Whether both Capsules were involved or not?	Were the affected Capsules wholly destroyed?	General Condition of other Organs.	No. in foregoing Report.
1	May 16.	Dr. Quain.	Woman aged 45.	The Skin of the entire body was as dark as that of a mulatto, but having a decidedly yellow tinge.	The capsules were healthy, excepting the presence of a slight amount of fatty matter in some parts.	Both capsules in the same condition.	Natural structure of the organs remaining in all parts.	Diseased Brain.	10

POSTSCRIPT.—Those instances of disease, or absence of disease, of the supra-renal capsules in the lower animals exhibited to this Society, although reported upon by the Committee, as to their validity, etc., are intentionally excluded from the above Tables.

(Signed),

J. S. BRISTOWE,
JONATHAN HUTCHINSON,
GEORGE HARLEY,
JOHN W. OGLE,
SEPTIMUS W. SIBLEY,
SAMUEL WILKS.

Members of Committee appointed to Report.

II. THE SPLEEN.

14. *Extensive Tubercular disease of the Spleen from a Child suffering from Purpura.*

As all instances in which blood-disease is associated with alterations of the structure of the spleen must be deemed of interest, the following case was submitted to the Society. In this example it will be observed, that although there was tubercle in nearly all the internal viscera, the spleen was more extensively diseased than any other organ.

E. M., æt. 4, was admitted into the Middlesex Hospital, on the 16th of April, 1858, under the care of Dr. Hawkins. The mother stated that the child had never been strong, and that a week before admission, numerous red spots appeared on various parts of the body, the debility at the same time greatly increasing. The father was at this time suffering from phthisis in an advanced stage, and being, therefore, unable to follow his employment, his family had been most wretchedly fed. This child had been living chiefly on bread and butter, with potatoes occasionally.

When admitted, she was pale and somewhat emaciated, there were petechial spots of various sizes scattered all over the surface of the body. Subsequently, fresh spots made their appearance on the legs and on the face, much hæmorrhage took place both from the mouth and from the nostrils, and in spite of proper nourishing diet and lemon juice, she gradually sank and died on the 25th of April.

At the *post-mortem examination*, the body was of fair size and proportions, although somewhat emaciated. There was extreme pallor of the surface, interspersed with the petechial spots on the face, neck, and extremities. In the right pleural cavity there was rather more than an ounce of clear, pale, straw-coloured serum; on the left side, there were a few drops of similar fluid. There were numerous bright petechial spots beneath the pleural on both sides. Minute tubercles were scattered over the surfaces of both lungs. On making sections of the lungs, tubercles were found in all parts, a few of these were of the semi-transparent grey variety, but the majority were opaque, and some had all the

usual characters of crude tubercles. They were all of small size, except one in the lower lobe of the left lung, which was as large as a pea. The tubercles in the lungs were all firm, and exhibited very little tendency to softening. Neither the pericardium nor the heart presented unusual appearances. In the cavities on each side of the heart, there was a soft, partly coloured clot of blood, with some slightly tinged serum. A microscopical examination of this blood shewed, that the proportion of white corpuscles was increased, but not to a remarkable extent.

Beneath the peritoneum there were petechial spots, similar to those beneath the pleura. Small tubercles were also scattered over its surface. The liver was somewhat large, and exhibited a well-marked instance of the "waxy" disease; numerous opaque tubercles the size of pins' heads were, moreover, scattered over the surface, and throughout the substance of the organ. The kidneys were quite natural in their structure, with the exception of a few small tubercles in their interior.

The lining membranes of the stomach presented several dark chocolate-coloured spots. There was also a small quantity of altered blood in the intestines. In other repects both the stomach and intestines were healthy.

The lymphatic system was much affected by the disease. The bronchial glands were converted into masses of soft, cheesy, yellow tubercle. The glands in the gastro-hepatic omentum were in like condition, but the mesenteric were simply somewhat larger than natural, but did not appear to be all affected with tubercular disease.

The spleen was somewhat larger than usual, weighing three ounces and a half; it was firm, the surface being covered with small tubercles. On section, the surface was thickly interspersed with tubercles of various sizes, and in all conditions. The largest were about the size of peas, the majority, however, being much smaller than this; nearly all the larger ones were softened in the centre, and in some, a portion was quite fluid. The smaller tubercles were firm, but opaque and yellowish. The intervening spleen-tissue was firm and rather dark in colour, but did not present any appearance of disease. The fibrous structure of the organ appeared to be somewhat increased in amount.

Mr. Septimus W. Sibley, 18*th of May*, 1858.

X. MISCELLANEOUS SPECIMENS.

STATES OF THE BLOOD, MALFORMATION OF OUTWARD PARTS, SPINA BIFIDA, ENTOZOA, TEETH, SKIN, EFFECTS OF POISONS, ETC.

1. *Drawing of a Case of Congenital Deficiency of the Latissimus Dorsi, and of the lower portion of the Pectoralis Major Muscles, the Pectoralis being wanting below the second rib.*

The subject of the malformation is a young gentleman, æt. 19, strongly developed in all other respects. No deformity resulted in consequence of the malformation beyond a marked hypertrophy of the teres major, and a general fulness of the other scapular muscles, causing the hollow left by the absence of the latissimus to be more obvious. No interference with the proper movements of the arm could be discovered. The young man stated, however, that he could not lift so heavy a weight with the right as with the left arm. The malformation was not hereditary.

Mr. T. W. Nunn, 20*th of October* 1857.

---

2. *Case of Polydactylism, in which nine Toes existed on one Foot.*

The specimen exhibited, consists of four supernumerary toes

Lign. 14.

This figure represents the foot previous to operation; the drawing was made from a cast.

which I removed, a few days back, at the Hospital for Sick

Children, from the left foot of a female child. It will be seen from the cast of the foot as well as from the drawing (Lign. 14), that the four smaller toes appear natural; the one, however, which occupies the place of the big toe, though quite distinct from the others, is smaller than the one on the opposite side, and rather resembles a *third* toe; it also articulates, not with the first metatarsal bone, but with the second.

Standing out from the inner side of the foot are the four extra toes. Of these, the two which may be called the *first* and *second* are soldered as it were together, but present two distinct nails on their dorsal surface, with a groove indicating their division. These toes are separate and distinct from the two other extra toes which are united even more closely than the first pair, their division in fact being only marked by a cleft at their extremity.

The little patient was a girl, æt. 6, well-grown, and healthy, and presenting no deformity in the other foot, or in any other part of the body. No similar malformation can be traced in the family. The father and mother, as well as the grandfathers and grandmothers, were free from any such blemish, as is likewise the only other child, a girl, seven years older than the one in question. No cause whatever is assigned by the mother, nothing unusual having happened during her pregnancy, to which she could attribute the peculiar formation.

For the following account of a careful dissection of the part removed, I am indebted to Mr. Ernest Hart, one of the Demonstrators at St. George's Hospital.

Skin-markings.—Externally this specimen appears to consist of two double toes, of which the inner and larger resemble respectively the first and second toes of the left foot. The inner pair appear to have coalesced. The nails are of normal structure and growth, and are united by their contiguous borders; the skin beyond presenting no trace of division. The outer piece terminates by a rounded extremity, presenting a superficially bifid appearance due to a furrow in the skin. It is devoid of nail, or of any cavity for the implantation of a nail.

Bones, etc.—On dissection, the specimen appears to devoid of muscles, and to present only the terminations of the flexor and extensor tendons having their normal manner of insertion. The

two inner toes are supplied by the same flexor tendon, which bifurcates and passes to be inserted into the ultimate phalanx of each by a separate slip. The vinculum by which it is attached is common to the two bones.

There are altogether six phalanges. The two inner toes consist each of two phalanges, in each case modelled after the type of the great toe, having an osseous fusion at their proximal extremities, and presenting one bony mass with a single articular surface, which articulated with the head of the first metatarsal bone, whilst at the other end they separate from one another, presenting two extremities of normal character, articulating with corresponding surfaces of the ungual phalanges, but included in the same synovial cavity, and forming one double joint. The outer toes also consisted of two phalanges, the proximal extremity of the first which has been removed in the amputation, articulating with the second metatarsal bone, its distal extremity having normal articulations. It is connected with the inner toes throughout by transverse tendinous fibres. The indication of bifidity is confined to the soft parts, the fissure in which corresponds to the middle of the end of the phalanx, which is somewhat broader than natural, but not bifurcated.

Remarks.—I have ventured to give a somewhat minute description of this specimen, as *polydactylism* (a term very anciently employed in science) though more common than a diminution in number, presents itself usually in the form of six fingers or toes. This number is frequently met with; in fact, amongst the Romans, men with six fingers were sufficiently common to have a special name (*sedigiti*) assigned to them.

The fact of the existence of seven, eight, nine, and even ten toes, though the cases become more rare as the numbers increase, has been recorded, and in Kerkringius' "*Spicilegium Anatomicum*," I found the description of a monster, which appears to have been drowned by its parents, at Amsterdam, in which, besides many other malformations, there were eight toes on the right foot, whilst "the left displays the hitherto unheard of fecundity of nine" (*dexter enim octo, sinister novem inauditâ hactenus ostendit fecunditatê*).

It may be remarked, that besides the coincidence of its being the *left* foot which displays the nine toes, on referring to the plate which accompanies Kerkringius' description, it will be noticed, that the supernumerary toes are also on the great toe side, and that they are likewise partially united in pairs, presenting apparently seven metatarsal bones.

Mr. Athol A. Johnson, *20th of October*, 1857.

---

3. *Hydatids formed and discharged, subsequent to injury to the Tibia.*

Mrs. G., æt. 28, her parents both suffered from asthma, but were otherwise tolerably healthy; her mother when about thirty years of age, had a tumour removed from the upper eyelid. Mrs. G. who has always enjoyed good health, was married at twenty, and has one boy now seven years old, who appears strong and healthy. She states that the present disease in her right leg arose in consequence of a severe kick she received from her brother about eight years ago, which produced a bruise, but did not break the skin; the injured part, however, remained tender and painful for five months, when it was again struck accidentally, and shortly after this she noticed a tumour, which gave much pain at times, but was not of so severe a character as to induce her to lay up or seek medical advice. The swelling continued to increase slowly for five years, when she became an out-patient at Guy's Hospital for six weeks, under Mr. Poland, after which time she became an in-patient under Mr. Hilton, who, as she states, kept her in bed, with splints, to insure perfect rest, and applied blistering liquid several times, but without any apparent benefit; after a month's trial of this treatment she left the Hospital and returned home.

The tumour soon began to increase more rapidly than before, but she was able to attend to her household duties, and did not seek further medical advice until about six weeks ago (20th of September), when the pain became very severe, and the tumour much more inflamed, and a small ulcerated opening speedily formed, through which was discharged, by gentle pressure, a large bunch of hydatids, with some pus and blood. At this time I first saw her,

when the tumour was of an oblong form, extending from about two inches below the patella, to about four inches lower down the tibia, and projecting on the inner side of the leg; a second ulcerated opening soon formed; the accompanying sketch (Lign. 15), was then

LIGN. 15.

This figure shews the seat of the swelling on the leg and the ulcerated opening.

taken; through both apertures numerous hydatids of various sizes were discharged, and some minute portions of bone came away. The tibia was quite denuded of periosteum.

The tumour felt very hard in some parts, as if from bony enlargement, and in others, soft and elastic, as if containing pus and cysts. The patient's general health did not seem materially affected, her appetite being good, and she slept usually well.

On the 19th of October, more openings had formed, and the same kind of discharges continued. I then procured her admission into St. Mary's Hospital, under the care of Mr. Coulson, who excised the whole of the diseased bone, and the patient perfectly recovered.* Dr. H. DAUBENY, *3rd of November*, 1857.

* The case was also brought before the "Medico-Chirurg. Society," in the present session, by Mr. Coulson.

4. *Femur and Hip-joint taken from a patient who had been affected by Talipes Equinus Paralyticus.*

The head of the femur was flattened, the shaft not larger than that of a child of seven or eight years old, presented a firmly united oblique fracture at the lower third, although the subject had reached manhood.

The cotylöid cavity was very shallow, with some thickening at its outer and lower margin, the tuber ischii was in a great measure undeveloped.

Both the femur and innominate bone were abnormally light. The femur was in the recent state partially fixed in the position of semi-flexion, and was partly adducted.

The thickness of the outer and lower part of the acetabulum mentioned, was probably due to this position of the limb.

Mr. NUNN, *19th of January*, 1857.*

---

5. *Fatal Jaundice (?) without discoverable Structural Disease of the Liver.*

J. G., a clerk, æt. 26, came under my care as an out-patient at St. Thomas's Hospital, on the 16th of October, 1857, labouring under an attack of jaundice.

The following history of his case was obtained, partly from himself and partly from his parents. He was born in Dublin, was brought, when five years of age, to London, and continued to reside in one or other of these cities up to 1843; since which time he has lived entirely in London, on the Surrey side of the water, but never in an aguish district. He has always been remarkably temperate and well-conducted, and indeed of a very serious and religious turn of mind. When five years of age he had a rather severe attack of "worm" (typhöid?) fever. He suffered slightly from scarlet fever, without subsequent dropsy, at ten, and experienced a severe attack of measles at twenty-two years of age. He never contracted the venereal disease, never had ague, nor indeed any serious illness except those above-mentioned and those about to be described. During

* The case of talipes equinus to which the above specimens had belonged, was described by Mr. Lonsdale, at p. 405 of vol. viii. of the Society's "Transactions."

the last five or six years he has been somewhat dyspeptic and fanciful; and during the last two, his temper, naturally placid, has been getting irritable and peevish. In 1852 he had (what he calls) a stomach attack, which lasted two or three months, and was followed by some impairment of vision. A few months afterwards he had a similar but slighter attack; and during the next three or four years he suffered two or three relapses, in the last two of which he states he was slightly jaundiced.

His present illness came on gradually about six months ago, with depression of spirits, vertigo, loss of appetite, trembling in the knees, and pains in the jaws and face. Slight jaundice was added to the other symptoms about four months ago, and latterly, occasional matutinal vomiting of bilious fluid. There has been no epigastric uneasiness and no vomiting after food; the bowels have been somewhat variable, but generally constipated.

At the time he first came under observation, he was remarked to be of middle stature, spare, of a somewhat anxious expression of countenance, and universally, though not deeply, jaundiced. There was neither general dropsy, nor ascites, no fulness or increased dulness in the region of the liver, and no uneasiness or tenderness in that situation. The heart's sounds were normal, the pulse rapid, small, and weak; and the functions of the lungs were healthily performed. He was evidently very anxious about himself, and entered into a minute statement of all his symptoms, but added nothing to the account above given, beyond the facts that his urine was exceedingly dark-coloured, and his fæces unusually pale.

He continued attending as an out-patient until the 19th of January; and although, during this time, slight fluctuations occurred, there was on the whole no improvement whatever in any one of his symptoms. The degree of jaundice was much the same at the end of this time as at the beginning; the vertigo, attended by occasional headach, continued; the morning bilious vomiting, accompanied often by a feeling like that attending sea-sickness, persisted; and the condition of his appetite, of his evacuations, and of his physical powers remained unaltered. On two or three occasions, however, he complained of weight at the chest after food, and during one week of a dull pain to the right of the umbilicus.

On the 19th of January, he was admitted into the Hospital under my care, with no appreciable change in his condition; and he remained in much the same state, sometimes a little better, sometimes a little worse, up to the 1st of February. He was exceedingly weak, and somewhat emaciated, with a rapid and feeble pulse. He complained generally of a feeling of giddiness and pain around the eyes, especially when he moved. His tongue, usually pale, was sometimes furred; his appetite was variable, but commonly bad, and occasionally he felt a wish for bitters. He suffered much from thirst, and frequently vomited bilious fluid. The bowels were generally constipated, and the motions pale, though not wholly untinged by bile; and his urine was high-coloured. The skin was inclined to be dry, and both it and the conjunctivæ continued very decidedly jaundiced. He complained occasionally of dimness of sight and deafness, but his sleep was generally undisturbed.

On the 2nd of February, he suffered more than usually from the deafness and dimness of sight, and occasionally rambled. During the ensuing night and the next day, these symptoms, and especially those of delirium, increased so that sometimes he was violent; and, although when addressed, he understood what was said to him, and answered pretty rationally, he soon returned to his original condition. He appeared to know where he was, and what was going on, but suffered under manifest delusions, as to the past and future, and as to the object of all the proceedings that passed before his eyes. He continued in this state, gradually sinking, till four A.M. of the 4th, when he died, the other symptoms of his malady having undergone no change.

Various plans of treatment were adopted during the several months that he was under observation, and, although one or two appeared to be attended for a time with benefit, none effected any permanent good. At one time he was treated with nitric acid and decoction of cinchona; at another, with iodide of potassium and gentian; at another, with the iodide of mercury; and at another with alkalies. During the whole period, the bowels had to be regulated by purgatives of various kinds, and of different degrees of strength

Post-mortem examination.—The body was spare, the skin uni-

versally jaundiced, though not deeply so, and the lips were exceedingly pale.

Calvaria and membranes of brain perfectly healthy. There was very little sub-arachnoid fluid; and the vessels on the surface contained a small quantity of very pale and watery blood. The substance of the brain was pale and slightly yellow, but otherwise healthy.

The pericardium contained an ounce or two of serum. The heart looked large, and weighed thirteen ounces and a half. The walls of the left ventricle were of usual thickness, their muscular tissue was pale and soft, and those portions of it immediately beneath the endocardium presented universally a pale mottled aspect. The ventricle was empty, and its valves were perfectly healthy. The walls of the right ventricle were rather thick, and their muscular tissue presented the same characters as that of the opposite side. The cavity contained a small, soft, brick-red coloured coagulum, and the pulmonic and tricuspid valves were normal. The lungs were unadherent, voluminous, pale-yellow, crepitant throughout, and in the posterior parts œdematous. Several of the smaller branches of the pulmonary artery contained firm, fibrinous coagula, which filled them, but were unadherent to the parietes, and measured in some instances an inch or two in length. The bronchial tubes were pale, and contained a large quantity of thin, frothy mucus. Bronchial glands healthy.

Peritoneum healthy. The liver appeared to be rather larger than usual, and weighed three pounds six ounces and a half. Its shape was natural, and its capsule unthickened. The substance of the organ was of normal consistence, presented a nearly uniform yellowish-brown tint, and yielded a smooth and natural-looking sectional surface. The gall-bladder was small, but healthy, and contained about half an ounce of rather thick, but healthy-looking greenish-brown bile. The hepatic ducts were traced from their termination in the intestine to a considerable distance into the substance of the liver, and were found to be of normal dimensions, and perfectly healthy throughout. Their lining membrane was bile-stained; and their contents consisted almost solely of occasional small masses of soft, pulpy, brown material. The spleen was large and weighed one pound; its

capsule was thin, its substance firm, yet pulpy. Pancreas and supra-renal capsules perfectly healthy. Kidneys pale, but apparently healthy. Stomach and intestines pale and jaundiced, but healthy. Aorta healthy. Mesenteric and other abdominal glands healthy.

The blood throughout the entire body was remarkably pale, watery, and destitute of coagulum. All the organs, tissues and fluids of the body were stained slightly, but decidedly, by bile.

Microscopic examination.—Under the microscope, those portions of the muscular tissue of the heart which were mottled were found to consist of fibres, in which all appearance of transverse striation and of longitudinal marking was absent, and of which the entire substance was studded with molecules and distinct oil-globules of various sizes, the fibres being in some instances so thickly studded as to be rendered perfectly opaque. The fibres constituting the unmottled portion of the heart's parietes, presented, for the most part, tolerably distinct striæ, but many were granular and studded with oil, yet none were degenerated to an equal degree with most of those which were situated towards the inner surface. Some fibres from the diaphragm were examined in order to compare their condition with that of those belonging to the heart; and their transverse striæ were found to be, not only universally present, but universally well marked and distinct.

The substance of the *liver*, under the microscope, had a nearly healthy appearance. The cells were perfect and distinct, but most of them contained a considerable number of small oil-globules, which were sufficiently numerous in many cases to render the nuclei indistinct. Some of them were bile-stained. The pulpy material from the gall-ducts, consisted almost entirely of columnar epithelium, and large numbers of free nuclei, which had probably escaped from disintegrated epithelial cells, together with a small quantity of bile. A few similar bodies were found floating in the bile of the gall-bladder.

The *spleen* presented under the microscope little beyond the ordinary spleen-corpuscles and blood, and exhibited nothing abnormal.

The minute structure of the *kidneys* was perfectly natural.

The *blood* certainly did not present a preponderance of white cells—indeed, if there were any disproportion, it was in consequence of the red corpuscles being in comparative excess.

Remarks.—The case above recorded interested me a good deal during its progress, and my interest in it was much increased when the condition of the different organs was revealed after death. During its progress, the presence of jaundice, and its persistence over a lengthened period, led me naturally to regard the liver as the organ at fault; and I fully believed, notwithstanding the absence of uneasiness or tumour in its neighbourhood, and the non-occurrence of ascites, that the patient had been labouring under some organic hepatic disease, the nature of which would be revealed by post-mortem examination. It would be useless now to state the precise diagnosis at which I arrived, or to enter upon those considerations on which my diagnosis was based; for the post-mortem examination shewed that the liver was structurally healthy, and moreover, that there was no essential disease of any other organ. The patient died, jaundiced, yet no pathological condition was discovered, to account for either the symptoms or the event!

Was the case an example of that mysterious form of fatal jaundice which Dr. Alison first described, and of which Dr. Budd has collected numerous examples? There may be some reasons for answering this question in the affirmative; but there is at least one important fact against it; the case under consideration was essentially chronic, while all the others were markedly acute. But was the case really one of fatal jaundice at all? I must confess that on reviewing and comparing the history of the patient during life, and the results of the post-mortem examination, there seems greater reason to believe that his death was due to severe and progressive anæmia, than to any affection of the liver; that the case was, in point of fact, one of anæmia, attended or followed by jaundice. I found this opinion, partly on the fact that the patient was ailing and probably anæmic before the jaundice made its appearance; partly on the symptoms which manifested themselves while he was under observation, and which, with the exception of the jaun-

dice, were precisely those of anæmia; and partly on the state of the organs as revealed after death—none of them being positively diseased, but several being in such a condition as one ordinarily finds them to be after long continued deterioration of the blood. If the view here suggested be correct, the case is allied to those examples of anæmia to which Dr. Addison alludes in the commencement of his work on "Diseases of the Supra-renal Capsules." May it not even be allied to the so-called supra-renal capsular disease itself? Is it not possible that there may be, in all these cases, some deeper-seated systemic mischief, producing the general debility, and other symptoms of failing vitality; and concurrently, but less uniformly, imparing the functions, or altering the structure, of one or more of the organs or tissues of the body?

Dr. J. S. Bristowe, 16*th of February*, 1858.

Report on the above specimen.—We have examined the liver, and, excepting a slightly fatty condition of its cells in places, find nothing unusual in its texture, vessels or ducts.

Drs. W. S. Kirkes and John W. Ogle, 2*nd of March*, 1858.

---

6. *Case of Death from Anæmia. Fibrinous Clots in the Heart.*

A girl, æt. 11, was admitted under my care into the Great Northern Hospital, on the 16th of November, 1857. She was stated by her parents, who were themselves robust-looking, to have enjoyed good health until about six months previously. She then began to complain of erratic pains in the limbs and to lose flesh and strength. She became for some time an out-patient at the Hospital for sick children, went subsequently to the country, and returned in somewhat improved health, but soon afterwards she fell into the same debilitated condition as at first. There was no apparent cause for this, she has had good food, is warmly clad and resides in a neighbourhood not known as unhealthy. Her appearance on admission was that of great emaciation and debility, and of the utmost anæmia. The skin of the entire body was of a dead-white colour, while the lips, the tongue, the mucous membrane lining the gums and fauces were of a yellowish-

white hue. There was a listless look about the patient, but she replied to questions with quickness and intelligence. Respiration was hurried and difficult, but no affection of the chest could be discovered. The pulse was rapid, feeble, and compressible, and there was a faint murmur with the first sound of the heart. The stomach was so irritable that vomiting occurred immediately on taking food. The temperature of the body was low; her only complaints were of feeling cold and of the difficulty of breathing, which she attributed to want of air. The fauces were of dark-colour, the urine being pale and scanty. Notwithstanding the efforts made to support the patient by nutriment and stimulants given by the mouth and rectum, and the constant application of artificial heat, she died on the evening of the following day.

On *post-mortem examination*, forty hours after death, the muscles appeared of a delicate rose tint. A considerable amount of serous effusion was observed in both pleural cavities. The lungs were slightly emphysematous, very pale in colour, but otherwise healthy.

The heart was flabby and anæmic, and presented evidence by the microscope of fatty degeneration. A large fibrinous concretion was found in the left ventricle. This concretion, closely engaged in the musculi pectinati and the mitral valve, had a prolongation to the extent of three inches into the aorta. A similar, but smaller clot, existed in the right side of the heart. Very fluid blood was found in the cavities and great vessels of the organ. The spleen was of moderate size, firm, and of a light-puce colour. The gall-bladder was distended with bile. The supra-renal capsules, the kidneys, and other principal organs were carefully examined, but presented nothing remarkable except extreme paleness. The brain was in the same condition. but in the sinuses there was more blood than elsewhere. No considerable organic change was detected in any organ. What appeared most worth notice was the formation of fibrinous clots in the heart, while the blood was elsewhere characterized by not merely absence of coagulation, but remarkable fluidity. Some of this fluid, placed in a test tube, had a close resemblance to infusion of roses. Examined under the microscope, the blood discs presented the peculiarity of being very variable in size,

many of them being of an oval shape, whilst others had the ordinary numulated appearance.

Dr. LEARED, 10*th of March*, 1858.

---

7. *Spina-bifida in the Lumbo-sacral Region, which had Ruptured in Uterô, associated with Talipes Varus in both Feet. The child lived four days.*

This case occurred in the practice of Mr. I. I. Coghlan, of Notting Hill, who has supplied the following history.

"The mother had had several children well-formed. In the present case, the labour commenced at six P.M., on the 29th of January, 1858, with slight pains at long intervals. The pains became stronger at eleven A.M., on the 30th of January, and now for the first time, the mother believed herself to be in labour. I was sent for, and arrived at a quarter past one o'clock. There was a breech presentation high up, and the membranes had been ruptured half an hour previously. I felt a flaccid mass, which I supposed to be the scrotum, but it was much larger than usual. Labour progressed favourably, and terminated at three P.M., on the same day. The child, a boy, had been well nourished *in uterô*, but it would neither suck, nor receive food, and died on the fourth day. After birth, the flaccid mass, which during labour had been supposed to be the scrotum, was seen to be the ruptured tumour of a spina bifida, in the lumbo-sacral region. The parietes of the tumour had a dark purple and green colour, and a fœtid gangrenous odour, and a rent about an inch long, with irregular and attenuated edges, existed in its posterior part."

On dissection, it was found that the fluid had occupied its most frequent position, *viz.*,—the sub-arachnöid space; and that, as a consequence of adhesions between the two layers of arachnöid at the posterior part, the lash of nerves forming the cauda-equina passed directly across the cavity of the sac to its posterior part, intersecting it, and forming an imperfect septum in the mesial line. The posterior nerves were lost in the walls of the sac, and the anterior branches returned from the posterior part, re-crossing the cavity of the sac in the imperfect septum above adverted to, and reached the inter-vertebral foramina, through which they

emerged and were distributed in a normal manner. This distribution of the cauda equina in spina bifida occupying the lumbo-sacral region, is said to be constant by Cruveilhier, and out of twenty specimens in various collections, examined by Mr. Prescott Hewett, only one exception to this rule was found. Mr. P. Hewett's investigations are recorded in the "Medical Gazette," vol. xxxiv. page 459. The present specimen illustrates the value of the rules of practice laid down by Mr. Hewett, *vis*:—1st. "Never puncture in the mesial line, especially in the lumbo-sacral region. Puncture at one side and at the lowest part to avoid cord and nerves."—2nd. "Use a needle or trocar to avoid section of the nerves."

In the present case, talipes varus of the most severe form existed in both feet, and Mr. Adams remarked that this usually, if not invariably, co-existed with spina bifida in the lumbo-sacral region, and was probably dependant upon the deviation and, perhaps, also, the irritation of the cauda equina.

Mr. Adams also mentioned, that by a singular coincidence, another case of spina bifida, had recently occurred in the practice of Mr. Coghlan, in which the tumour had ruptured during labour, and the child lived nineteen days. In this case, Mr. Coghlan remarks, "the child was born on the 18th of February, 1858, and died on the 9th of March. Labour doubtful during night, certain at nine A.M. Head presentation. Delivered at half-past one, P.M. A spina bifida tumour, of small size, existed in the lumbar region, and was ruptured, I think, during labour. It was not putrid as in the former case. The child was premature, about the eighth month. It was not suckled, but fed. The tumour, from which a constant oozing of fluid took place, became fœtid in a few days, and the child gradually wasted and died on the 9th of March."

The feet were not clubbed in this case, but appeared as if compressed laterally, and more pliant from side to side than natural."

Mr. W. ADAMS, 16*th of March*, 1858.

---

8. *Neuralgia and Paraplegia, supposed to be due to the long continued use of arsenic, of which a trace was found in the Liver and Bones.*

Mrs. K., æt. 52, a lady of delicate constitution, was the mother of seven children, all of whom died in infancy excepting one boy, who lived to be fourteen years of age. She had suffered for some years from an affection of the skin between two of her toes, under the chin, and in the bend of the right arm; the last, which I saw several times, was chronic eczema. Up to two years and a half ago, she was troubled a good deal with chronic sore-throat, and was cured by the topical application of nitrate of silver. The catamenia ceased in June, 1857. The eruption about the toes and the bend of the arm continued to give her much annoyance, and to obtain relief she has been in the habit of taking preparations of arsenic for many years, more or less constantly. The eruptions would improve for a time and then become troublesome; that under the chin disappeared. The arsenical remedies were continued, even without her friends knowledge, up to the beginning of September, 1857, when, for the first time, she had a violent attack of rheumatism of the right shoulder, arm, and scapula. This subsided under treatment, and although there were no inflammatory symptoms, the attack was remarkable for the agonizing nature of the pains.

On the 18th of November, she had an attack of acute neuralgia of the right groin, which suddenly shifted to the left groin, and the left shoulder and side. This varied very much, being sometimes quite relieved, and at other times suddenly returning, and now and then shifting in its character. About the end of January the abdomen became tympanitic, and the right groin very tender, the inguinal glands of this side began to enlarge also. There was no actual indication of disease of the lungs, heart or uterus, and no abdominal tumour could be felt.

The severe pains, which partook of the character of true neuralgia were looked upon as depending upon irritation resulting from the long continued use of arsenic, an opinion in which I was supported by Sir James Clarke, Dr. Robert Lee, and, more recently, Dr. Copland. Latterly, the pains seemed to be centered

in the left hip and groin, together with the left shoulder and side. On the 25th of March, pain was felt along the lumbar spine, and on the 4th of April, she had numbness of her lower limbs and left hip; the pains were now easier from the constant use of morphine, and the abdomen became greatly distended. I succeeded in getting up the long tube on the 7th, but not afterwards, the bowels were with difficulty moved, and only in small quantity, and that generally by enemata. On the 12th, she lost all power of moving the lower limbs, which felt quite numb, although sensibility was perfect; this numbness gradually crept up the back, the abdominal distension became enormous, the urine small in quantity, and scalding, and the enlarged right inguinal glands entirely diminished in a couple of days. Her feet now swelled, and assumed a mottled colour, the powers of life began to flag, she became utterly helpless, and died quietly on the morning of the 23rd of April.

This brief detail gives but an imperfect account of the extent of suffering which was endured for seven months.

Post-mortem examination, twenty-three hours after death.—The body was extremely emaciated; the hips and back generally were covered with dark patches, some of them ulcerated, forming bed-sores. Rigor mortis absent. The chest was narrow, but bulged a little at the outlet from the great abdominal distension. The abdomen was distended directly forwards, and tympanitic throughout; it measured round the body thirty-seven inches. The form and course of the large bowel were distinctly visible through the integuments.

Abdomen.—On opening this cavity, the colon which at once protruded, was distended to its utmost with gas, and filled the anterior area of this space, taking a course upwards towards the pit of the stomach, then downwards, then upwards and again downwards, then towards the left side, and finally terminating in an enormous sigmöid flexure. The small bowel possessed its natural calibre, partly filled with fæculent matter, and pressed backwards by the distended colon. The termination of the ileum was small, and bound down closely to the deep fascia by a broad band of fibrous tissue, which materially prevented the free passage of matters along the canal, although the ileo-cæcal valve was intact; at

the commencement of the cæcum were three or four masses resembling enlarged glands, the size of beans, of a deep purple and an ivory colour, which seemed on the eve of ulceration; otherwise the entire intestinal track was normal. The stomach was pushed directly upwards, very small in size, seven inches long, and in width varying from one inch and a half to four inches; it contained a few ounces of fluid. The mesentery appeared normal, but here and there were isolated enlarged glands, varying in dimensions, the largest about the size of a couple of Barcelona nuts joined together; but along the entire lumbar spine, numerous flat glandular bodies were present, of a black colour. At the inner side of the left abdominal ring, and pressing upon the external iliac artery, and the crural branch of the genito-crural nerve, was a mass of enlarged glands, the size of a small peach, which explained the severe pain in the left groin during life. Two or three smaller glands were present in the right side, in a corresponding position, but not of dimensions to cause pressure there.

The bladder contained twelve ounces of clear urine, of a peculiarly offensive smell, not ammoniacal, and possessing the following characters: its specific gravity was 1017, feebly alkaline, contained a little sugar; after standing for some time, a slight deposit occurred, which consisted of oxalate of lime, vibriones, and a very few pus corpuscles. There were no casts of tubes.

The kidneys were somewhat gorged with blood; the right was larger than the left; in general structure they were hard and firmer than usual, contained much fat, as evidenced by boiling, which permitted numerous small oil globules to float on the surface of the liquid. The uriniferous tubes seemed to be loaded with epithelium.

The supra-renal capsules appeared quite healthy, but the two surfaces of the left were studded with minute yellowish-white tubercles, the size of the heads of pins, which are still apparent in the preparations.

The liver was small and firm, and was pale and waxy on section: its dimensions were five inches wide, and eight inches and a half long, its anterior border was of a yellowish-white colour as if carnified. Its thickness was in proportion to its

size; its upper and posterior surface was partly adherent to the diaphragm from old inflammation, and could only be removed by detachment of its capsule. Its cells were filled with small fat granules and globules, and there were numerous fat globules free, some of which were as large as the cells themselves. It contained a moderate amount of sugar, and on very careful analysis a trace of arsenic was detected.

The gall-bladder was distended with bile. The spleen was normal in structure and colour.

The bodies of the lumbar vertebræ were infiltrated with a pinkish-coloured fluid, which presented nothing unusual under the microscope; the osseous substance was not as firm as is generally met with.

The enlarged mesenteric and lymphatic glands, were simply hypertrophied, but the mass of glands over the external iliac artery was undergoing degeneration, and filled with a pulpy cream-like fluid, containing broken-up cells.

Thorax.—The lungs did not collapse on opening the chest, because pleuritic adhesions not of great extent, but about two inches and a half in diameter, were present on the anterior surface of each; those on the left side partly involved the left margin of the pericardium. In general structure they were quite healthy; at the apex of each was a distinct cicatrix shewing former disease in those parts. That on the right was two inches and a quarter long, and one inch and a quarter wide, and was pyriform in shape; whilst that on the left was smaller, and at the same time a little more puckered; a hard, circular, calcareous nodule, two lines in diameter, with a few little hard bodies were present in the latter. The posterior surfaces of both lungs were in a state of muco-sanguineous engorgement, but actual disintegration of tissue had not occurred. On each side of the bronchi, and running into the lungs, were numerous enlarged bronchial glands of a black colour, which were likewise present in both sides of the chest running up along the spine; some of these on being cut into poured out a fluid like thick ink. One large mass, the size of a turkey's egg, was situated immediately below and between the bifurcation; it projected forwards, and pressed against the upper part of

the heart. It was divided into four or five lobules, varying in colour from a deep bluish-black to a pale-salmon. The black portions, as well as all the other similarly-affected glands throughout the chest and abdomen, were infiltrated with granules of black pigment, partaking of the character of true melanösis, from their becoming bleached by nitric acid and chlorine. Some of the lobules of the mass of affected glands beneath the bifurcation, contained a creamy fluid, which consisted of disorganized gland-tissue, compound granular cells, and black pigment. The right pneumogastric nerve coursed directly over the tumour at its posterior part.

The heart was small for an adult, and weighed five ounces and a half. All of its cavities and valves were normal, its structure was fatty, and on boiling a little piece of it, numerous globules of fat floated on the surface of the liquid; under the microscope, fat molecules were seen between the muscular fibres. Both the thoracic and abdominal aortæ, were studded with numerous patches of atheroma, not yet in a state of ulceration. This condition pervaded many of the smaller trunks. All the arteries were found empty, and the veins contained very little blood; both ventricles of the heart contained a firm clot of fibrine, which ran up into the pulmonary artery and aorta.

All the organs and tissues were submitted to the most rigid and careful chemical analysis for arsenic. The kidneys, spleen, and lungs; heart, bowels, muscle, and nerve; pancreas, diseased glands, and blood, were separately examined, and no arsenic was found. Some of the bones, especially a portion of the spinal column, were dissolved in dilute hydrochloric acid, and then examined, and a distinct trace was found in the bodies of the lumbar vertebræ. The liver was examined three separate times, and a trace of arsenic was detected in it also. Thus the liver and the lumbar spinal column contained traces of this mineral.

Remarks.—This case is brought forward to shew that a form of neuralgia will arise from the irritation produced by the long-continued use of arsenic, and although it may after awhile pass out of the system, it still leaves behind it a latent excitability of the nervous system, which will manifest itself on the first favour-

able opportunity. I did believe, however, that some trace of the mineral would be found in the tissues of the body, and devoted great care to ascertain the point, and as just mentioned, the liver and spinal column contained a trace of it, a little over seven months after cessation of its use. The forms of arsenic used, were principally the iodide and Fowler's solution. Its deleterious influence would appear to be exerted chiefly upon the abdominal and thoracic glandular system, especially the former.

If the Society agree with me in the correctness of my conclusions, I would be disposed to give the name of *arsenical neuralgia* to this affection, in a similar sense to the employment of the term of lead palsy or lead colic affecting painters.

Dr. Gibb, *4th of May*, 1858.

---

9. *Sugar in the Tears from a Case of Diabetes.*

In diabetes every fluid secretion has been examined for sugar, so far as I am aware, excepting the tears, and having a favourable opportunity for doing so, on the 30th of April, I examined some tears in a small tube, shed by Mrs. W., a lady, æt. 21, who has been affected with diabetes mellitus for two years, ever since she weaned her only child. A drop or two of Barreswill's solution of copper were added, the fluid was boiled over a spirit lamp, and at once gave an abundant precipitate of the yellow sub-oxide of copper. The same experiment with an equal bulk of the urine; shewed that there was a much larger proportion of sugar present in the tears. The specific gravity of the urine was 1043. A drop of each fluid was evaporated on a piece of glass, when that from the tears shewed a much thicker and more opaque crust than was yielded by the urine. On the 9th of April, when she first came under my care, her urine was passed in quantities, varying from twelve to fifteen pints a day, and she drank at least eight pints of fluid in the twenty-four hours. Now, the quantity is perfectly natural, her thirst is diminished, and she takes her usual allowance of food and drink. The urine is still highly saccharine.

Dr. Gibb, *4th of May*, 1858.

---

10. *Congenital, Supernumerary and Imperfectly Developed Auricles on the sides of the Neck.*

L. P., a healthy female infant was brought to me in 1851, within a month after birth, on account of two projecting growths about the middle of the lateral cervical regions. At that time I advised the parents not to have them cut off, but to wait until the child was strong. In February, 1858, they brought the girl to me again. She was very healthy, the growths had increased slightly, and were situated over about the centre of the sterno-cleido mastöidei muscles (Lign. 16). To the touch they re-

LIGN. 16.

This figure shews the supernumerary auricles on the sides of the Neck.

sembled the tissue of the lobe of the auricle, and they contained within them a firm resisting nucleus like the cartilage of the same organ. They were also covered with the peculiar delicate, soft, downy hairs, like the lobe of the ear.

I excised them without difficulty. Each was supplied with a

small artery. They appeared to be intimately associated with the fibres of the platysma myöides, not dipping deeper than this structure, and to be entirely cutaneous appendages.

A vertical section was made in the long axis of each growth, and the tissues of the lobe and of the fibro-cartilage of the auricle were clearly distinguished. The shape of the fibro-cartilage resembled more or less closely in parts, the outline of that of the proper auricle, and its tissues were the same.

The accompanying sketch was made by Mr. Hurst, draughtsman, at Guy's Hospital.

Mr. J. BIRKETT, *4th of May*, 1858.

---

11. *Report on the Effects of Infantile Syphilis in Marring the Development of the Teeth.*

For a considerable time past, I have been in the habit of recognising in a certain very peculiar development of the permanent teeth an indication that their possessor had in infancy suffered from hereditary syphilis. A remark to this effect, which I made at a meeting of the Pathological Society early in its past session, being received with expressions of incredulity, it occurred to me, that it might be well to make public such evidence as I possessed on the subject. With that view, the facts which are the basis of the following report were collected. My friend, Mr. Coleman, our dentist at the Metropolitan Free Hospital, entered with zeal into the subject, and readily agreed to take casts of the teeth of any patients I should send him. (*See Mr. Coleman's statement*, page 453). Most of the cases taken, were those of patients attending at the Royal Ophthalmic Hospital, on account of chronic interstitial keratitis, an affection which is, I believe, almost always a result of inherited syphilis. Their ages varied from twenty-eight years to five years. In all a clear history of syphilis was established, either by the free confession of the patient's parents, or by the account given of symptoms of undoubted character during infancy. With this statement as to the diagnosis I must here content myself, as space will not permit of a recapitulation of the facts, on which, in each case, it was founded. The number of casts

taken was thirteen,* and in all instances, a stereographic portrait of the patient was also secured, which in many instances, illustrates very well the peculiar physiognomy impressed by the disease. During the six months in which we were especially engaged in this inquiry, at least double the number of cases mentioned passed under our observation, but it was not deemed needful to take casts in all. I may here remark, that cases in which young adults display indubitable marks of having suffered from infantile syphilis, and in which also a clear history is obtainable, are very infrequent in the practice of general surgery. Had it not been for the field offered by the Ophthalmic Hospital in connection with the form of keratitis above adverted to, I should not have been able to collect in the alloted time a tenth of the cases. With these remarks as to the nature of the evidence, I will now pass to the conclusions arrived at.

That there is a peculiar condition of the teeth, which results from the influence of hereditary syphilis, and that the most frequent features of this condition are the following:—a. Smallness.—The teeth stand apart with interspaces, and are rounded and peggy in form instead of flat. *b. Notching.*—They usually exhibit in their border a broad shallow notch, or at times, two or three (serrated). Owing to their softness; these teeth rapidly wear away, and this notching is thus often obliterated, but when markedly present, it is one of the most decisive conditions. *d. Colour.*—Instead of the clear, smooth, white exterior of good teeth, they present a dirty greyish surface, totally destitute of polish and rarely smooth. No amount of cleaning will materially alter this feature which owes its existence, I believe to the great deficiency of enamel. *e. Wearing down.*—As before observed their softness from deficiency of enamel renders them liable to premature wearing down. The teeth of a syphilitic patient not twenty, will often be ground down as much as those of a very old person should be, and this in cases in which there is no peculiarity as to position, such as the front teeth meeting in the bite. An unusual degree of wearing down if co-existent with other peculiarities is then a

* Twelve casts and fifteen stereographs were brought before the Society. Plate xii. represents a well-marked example of malformed teeth from a photograph.

Portrait (from Stereograph) showing the dwarfed & notched condition of the permanent teeth in
Hereditary Syphilis

suspicious condition. *f.* The signs mentioned apply almost exclusively to the incisors and canines, and in fact the grinders are usually altered in a very much less degree. Their surfaces are often more uneven than those of healthy teeth, and now and then they present tubercular projections of very peculiar character.

These conditions are totally distinct from those produced by the ravages of caries. Very often the mouth of an hereditarily-syphilitic patient will present a full set of teeth, quite free from decay, but all of them marked with features of unmistakable peculiarity. As a general rule, however, they are very liable to caries. Of course, it is only when several of the conditions enumerated exist together, that a confident opinion can be given, and then it is the regularity of the type, and the fact that it marks all the front teeth in both jaws, which offers the best means of distinguishing it from other forms of disease or irregularity.

The above remarks apply only to the permanent set. The milk-teeth of syphilitic-infants, are liable to exfoliate before being cut, and after having been cut, are often of small size, bad colour, and very liable to decay, but the notching and the peg-like form are rarely noticed. I have no doubt that the explanation of the fact that they suffer less uniformly than the permanent set, and in a somewhat different way, is to be found in the fact, that at the time of the original stomatitis, they were already well-formed, whilst the others existed only as soft pulps. It is, I am convinced, to the occurrence of syphilitic stomatitis during the first few weeks of life, and its complication with alveolar periostitis, that the marring of the teeth is to be attributed. A patient may be syphilitic, but if in infancy he escape stomatitis, his teeth will not be damaged.

In demonstration that during the syphilitic stomatitis, so common in the infantile form of the disease, inflammation of the alveolar periosteum, and the tooth-pulps does actually occur, I may here mention the particulars of two cases, specimens from which were brought before the Society at a former meeting.

In the first of these, an infant aged one month, came under my care at the Metropolitan Free Hospital, in November, 1856, on account of sore mouth. I observed the edge of a central incisor,

projecting from the spongy and swollen gum. On touching it with a probe, it fell out, a mere tooth crown, without any fang whatever, and a few drops of thick pus followed. During the next three months, four other teeth exfoliated from the same side, all fangless, and finally a considerable portion of the alveolar process and outer lamella of the jaw came away (Lign. 17). The

LIGN. 17.

These figures represent the exfoliated portion of jaw and the fangless crowns of four teeth.

gum then became sound. The mother in this case was known to have had syphilis. I have frequently, since the teeth came away, seen the infant for relapses of syphilitic eruption.

The subject of the second case, was a female infant, æt. 7, who came under my observation at the Royal Ophthalmic Hospital, being a patient of Mr. Critchett. Her cachexia was extreme, she had severe snuffles, and double purulent ophthalmia. The history given was, that she had been quite healthy at the time of birth, and that the symptoms had set in on the fifth day. Her mother had sores at the corners of the mouth, which were of an unmistakably syphilitic character. In this case, four teeth came away, all of them, as in the former case, mere crowns, and of a dirty colour. Suppuration attended the process of exfoliation.

These cases, it must be borne in mind, are quite distinct from examples of premature decay of teeth. The teeth had never been cut, and were thrown off by inflammation beneath them, no caries whatever existing. They are, I believe, of very infrequent occurrence; the alveolar periostitis of hereditary syphilis rarely proceeding so far as to cause either suppuration or death of the tooth crowns. They are of much interest, however, as examples of the extreme effects of the same morbid process by

which, I believe, that the malformation of the permanent set, to which I have alluded, is caused.

Mr. Coleman was good enough, at my request, to preserve notes of his examination of the cases which I sent him, and as these were taken quite independently of my own, I may here suitably introduce his summary of them. It will be seen that we coincide in all important particulars.

Mr. Coleman states as follows:—"The following appears to be the most important peculiarities in the teeth of the patients I examined:—

1. "*The period of the first dentition.*—Although the time of cutting the first teeth varies considerably, yet from the calculations of writers upon the subject, it appears that the central incisors may be looked for about seven months after birth. In eleven of these cases where information could be obtained; two had their teeth at birth; one when a few weeks old; two about two months after birth; two about the usual time; the remainder very late.

2. "*The form of the teeth.*—They are universally small, for although the alveolar arches are decidedly below the average size, there are in most considerable spaces between the teeth; they are also more round in form, resembling little pegs, projecting from the gum. The central incisors of most have a deep notch in their cutting edges, giving this portion of the tooth a tuberculated appearance. In many cases the teeth are much worn from mastication, the enamel being very soft, and probably containing a smaller proportion of calcareous salts than the normal quantity; from this circumstance the notch is not so marked in some cases, though its commencement may be observed.

"In nearly every case there is a deficiency in the superior alveolar arch, at the anterior portion, so great in some patients, that the upper and lower incisors are a considerable distance from each other when the mouth is shut. The notched appearance in these being well marked, and the teeth not having been worn by mastication.

"Teeth (incisors) having a notched appearance, are not very uncommon, but they are rarely so marked as with these patients. The upper central incisors also, instead of having their internal or mesial borders slightly everted, as in every well-developed arch, have them slightly inverted towards the palate.

3. "*Colour.*—This is very characteristic, being of a dirty, translucent shade, not, perhaps, unlike the size frequently seen in the oil shops, and therefore somewhat difficult to describe, but when once seen readily recognised again."

There remains two or three questions to which it may be well to attempt as explicit answers as the subject permits of before closing these observations.

1. *May not the condition of the teeth described, result from other influences beside syphilis?*—I have no doubt that any form of stomatitis in infancy in which the periosteum and investing membrane of the teeth became involved, could produce the same imperfections of development. Very probably many of the irregularities in the form, etc., of the teeth are due to the administration of mercurial courses in early infancy. As, far, however, as my own observation has gone, I believe it is very rare for any other form of stomatitis to produce such a regular type of deviation from what is normal in size, form, and colour, as is seen in good examples of that due to syphilis. In not a few cases where the characters were well-marked, I have formed, from the teeth only, a very decided opinion as to the antecedents of the patient, and inquiry has hitherto always confirmed it. In a large majority of instances, of course such certainty is not warranted, the peculiarities not being so characteristic, and being calculated rather to excite suspicion than to remove all doubt.

2. *In the cases of syphilitic patients in which this peculiar type of malformed teeth is observed, may it not be more reasonably attributed to the influence of mercury given to counteract the disease than to the disease itself.*—Undoubtedly in a majority of the cases upon which this report is founded, the nature of the disease had been correctly diagnosed by the medical men who had had charge of the patients in infancy. It is but fair, therefore, in these to suppose that mercurial treatment had been adopted, and as regards the teeth, it is impossible to discriminate between what may have been caused by the remedy and what by the disease. I have notes, however, of several cases in which no such diagnosis had ever been formed, and in which, as far as could be learned from the mother, no mercury had ever been given, and in these the state of the teeth was as marked as in any. No one will doubt

that a severe form of inflammation of the mouth does occur in syphilitic infants who have never taken a particle of mercury, and it is well known that this condition will usually rapidly subside under the use of that drug. In neither of the cases of exfoliation of the teeth above quoted, had any mercury been given. I am disposed, therefore, to think that this drug instead of causing, tends to diminish the dental malformation under notice, a conclusion which is strengthened by the circumstance that I have never yet seen the teeth in a condition which resembled at all closely the syphilitic type in which the history was that mercury had been given for non-specific disease in infancy.

3. *Do the subjects of inherited syphilis always present dwarfed and ill-formed teeth?*—Undoubtedly not. I fear that those who do so are only a small minority of the class. As already observed, it is, I believe, essential to this condition, that the patients shall not merely have inherited a taint, but that they shall have suffered severely in infancy from consequent inflammation of the mouth. The infants who do so suffer are, we know, but a small proportion of those whose fluids are yet in greater or less degree tainted by specific disease. In many cases I have noticed the almost entire exemption from symptoms of several infants in a family, whilst one of them had a most violent outbreak, and in two or three cases of especial interest in this respect, one twin suffered whilst its fellow escaped.

In conclusion, I may remark that the state of the teeth is often of great use in enabling us to decide whether certain other symptoms presented by adult patients are the results of hereditary or of acquired syphilis. It is of course impossible for acquired disease in any way to alter the form or size of the teeth. In two or three instances in which patients between the ages of twenty and thirty came under care, presenting the sunken nose, fissured lips and earthy complexion characteristic of syphilis, I was enabled by a glance at the teeth to determine at once that these were in all probability due to congenital, and not to acquired disease. Mr. JONATHAN HUTCHINSON, 18*th of May*, 1858.

A Committee was appointed to examine Mr. Hutchinson's cases and reported as follows:—

"Mr. Hutchinson afforded the Committee an opportunity of carefully examining six patients, whose teeth presented certain marked structural and other peculiarities enumerated by Mr. Hutchinson at the last meeting of the Pathological Society, in May, 1858.

"The Committee consider that the previous existence of syphilis was substantiated in five out of the six cases examined by them, and that the sixth case was probably of the same character.

"The Committee are disposed to conclude that the relation of cause and effect sought to be made out by Mr. Hutchinson is sustained by a careful examination of the cases referred to, but they hesitate to express a more decided opinion on the number of cases submitted to them. Mr. Hutchinson desires to offer further cases for examination, and the Committee, feeling the importance of the subject, have determined to meet again, and obtain this additional evidence on the subject."

GRAILY HEWITT,
HENRY LEE,
HENRY THOMPSON, 14*th of July*, 1858.

XI.—SPECIMENS FROM THE LOWER ANIMALS.

1. *Pulmonary Entozoic Disease of Sheep.*

Entozoa of the order Nematöidea are by no means of rare occurrence in the lungs of animals. Rudolphi, already fifty years ago, in his "Entozoorum Historia Naturalis," counted up twenty-one species of animals in whose respiratory organs worms of the above-named order had been found, and this number could at the present day at least be doubled. The Strongylus Filaria of Rudolphi which inhabits the lungs of sheep, goats, camels, and dromedaries,* is perhaps, the commonest representative of this class of entozoa, and it becomes of some practical importance, as it occasionally congregates in the bronchi of sheep and goats in such numbers as to cause the death of these animals.

* Dujardin, "Histoire Naturelle des Helminthes," p. 122.

Much, however, as has been known of this worm in its developed state, I am not aware that the process of its development has received sufficient attention.* And as the morbid appearances of the lungs, caused by the presence of the brood of this entozoon, resemble somewhat, and have often been mistaken for miliary tubercle, it may be interesting to bring the disease under the notice of the Pathological Society, and perhaps still more so, as a well-authenticated case is on record, of a similar entozoon having been found in the bronchial glands of a man.†

At the present time the lungs of almost all the sheep, that are brought to the London markets, contain the strongylus filaria in smaller or larger numbers.‡ The lungs are studded with a great number of small roundish nodules of about the size of a pin's head or a little larger. Many of these nodules are of a yellowish-grey colour and semi-transparent, others shew an opaque, white point in the centre, and others again are nearly black, resembling small shot.

Besides these small nodules, the lungs generally contain one or more larger bodies of irregular outline, and varying in size from that of a pea to that of a large bean. The latter are always opaque and of a dirty-yellowish colour. Consistence of both classes of bodies varying, sometimes soft, sometimes almost cartilaginous, and occasionally hard and chalky. Pulmonary tissue between these bodies perfectly permeable to air. The most frequent seat of these bodies is on the anterior margins of the lower lobes, where they lie immediately beneath the pleural covering, but they may be found in all parts of the lungs, on the surface, and occasionally

* The ova and young worms in their earliest stage have been well described by John Gray Sandie, and M. David George Padley, Esqs., in the "Annals and Magazine of Natural History," 1849, vol. iv., second series, p. 102; and also by Dr. Radclyffe Hall, in the "British and Foreign Med.-Chir. Review," vol. xvii. p. 449. But the authors of both papers seem to have entirely overlooked the further development of the worms, and Dr. Radclyffe Hall even suggests that these minute worms might stand in some relation to the larval condition of the liver flake (p. 450, note).

† The Hamularia Sub-compressa of Rudolphi found in the year 1789 by Treutler. "Rudolphi Entoz. Hist. Nat.," ii. p. 82.

‡ This fact might appear rather alarming, but Dr. Radclyffe Hall informs us that for the last seventeen years the disease has been as common as it is now. The "Brit. and Foreign Med.-Chir. Review," vol. xvii. p. 449.

some little distance beneath the pleura, embedded in the pulmonary tissue. When situated immediately beneath the pleura they are felt as hard and slightly prominent nodules.

All these bodies contain the brood of strongylus filaria in different stages of development.

The large irregular patches contain countless ova and young worms in their earliest stage, and fragments of the old female worm; these are all embedded in exudation matter, consisting of compound granular cells, cells resembling pus corpuscles and granular matter. These contents of the large bodies are entirely distinct from those of the small, roundish nodules; for the latter form a kind of cyst filled with exudation matter, and contain coiled up in this matter *one* single young worm attaining here to maturity.

The large bodies, therefore, must be viewed as the nests in which the old female worm has deposited its ova, while it must be supposed that the young worms soon leave this nest, and creeping into the finest ramifications of the bronchi, there encyst themselves separately, and give rise to the small round nodules. After the young worms have in these latter places attained their full growth, they again break into the bronchi, where they occasionally congregate in such numbers as to induce a most harassing cough, and, as mentioned above, even to cause the death of the sheep.

In the nests the ova may be seen in every stage of development (Plate XIII. Figs. 1, 2, 3, 4, 5, 6), some with uniformly granular contents, some in which the yolk is undergoing the different stages of cleavage, and others in which the fully-developed embryo is seen moving. The average longitudinal diameter of the ova is $\frac{1}{238}$th of an inch, the transverse $\frac{1}{454}$th of an inch. The embryos, when they have just broken through their envelopes (Figs. 7-8) measure on an average, $\frac{1}{1000}$th of an inch in breadth, and $\frac{1}{100}$th of an inch in length. They show very active movements, and are often found alive in lungs, which have been hanging up in the butchers' shops for three or four days. The fragments of the old female worm, which I have observed in these nests, invariably consisted of the oviduct, containing a variable number of ova (Fig. 9).

The solitary young worms, as has already been mentioned, are

DESCRIPTION OF PLATE XIII.

The Figures illustrate Dr. Ranke's communication on Entozoa in the Lungs of Sheep, p. 458.

Figs. 1 to 6. Ova in various stages of development.

Figs. 7 and 8. Young embryos just after having broken through their envelopes.

Fig. 9. Fragment of a female (?) worm, consisting of part of the oviduct, with ova in variable number.

Figs. 10 and 11. Head and tail of strongylus filaria (Duj.) male, taken from a dark cyst.

a. The double penis, between

b. The membranous appendages of the tail.

Fig. 12. One of the cysts, the wall of which is composed of condensed exudation-matter, the more fluid portions having been absorbed by the contained worm.

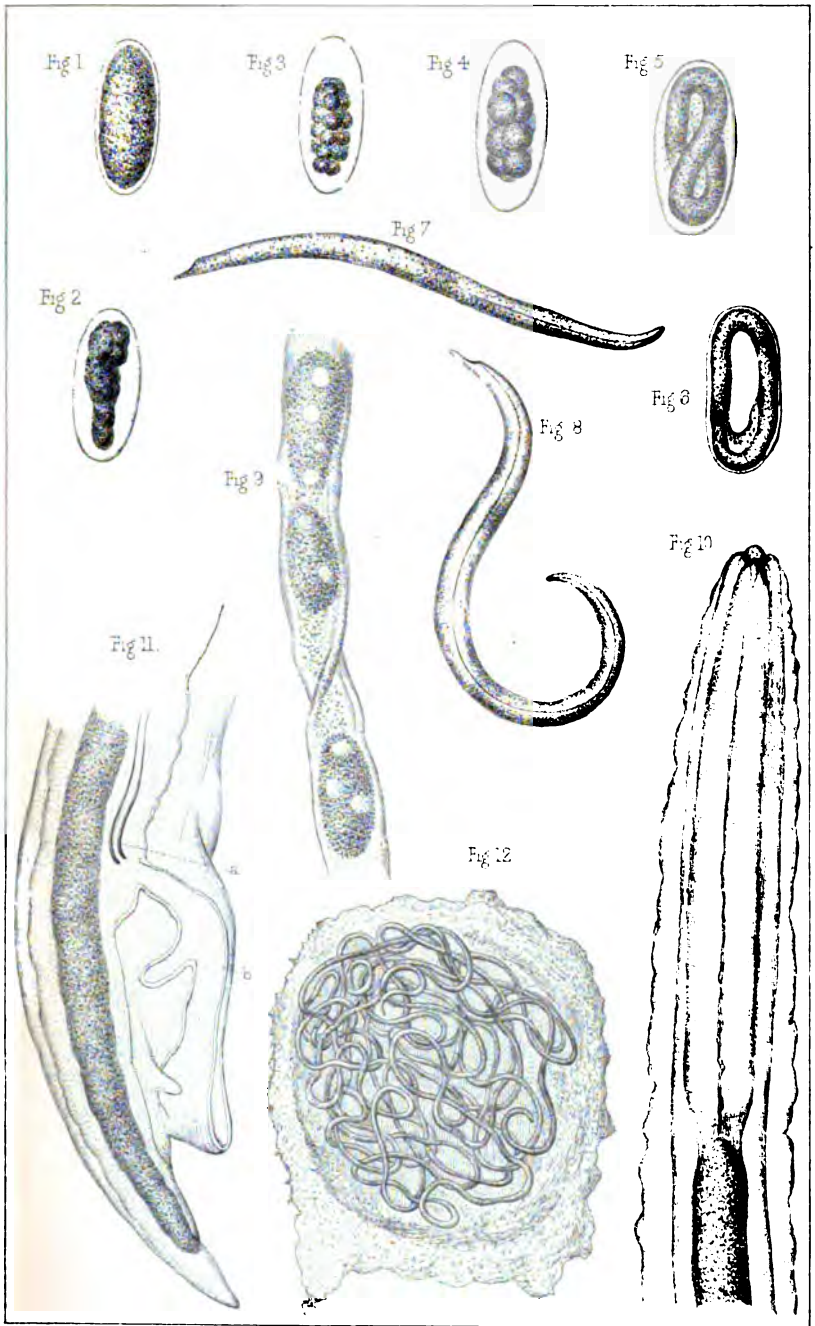

C Becker del. Tuffen West sc

W West imp.

encysted. These cysts do not properly belong to the worm, but seem rather to be the result of the inflammation set up by the presence of the entozoon, analogous to encapsuled tubercle, or the capsules formed around foreign bodies. If one of these cysts be squeezed between two pieces of glass, it easily breaks, and in general the worm may be seen at once protruding with the contents of the cyst. The breadth of these solitary worms varies according to the degree of development, from $\frac{1}{760}$th to $\frac{1}{166}$th of an inch, and the length, from a very small fraction of an inch to three inches; the smallest are found in the semi-transparent cyst, and the largest in the dark ones. In these dark cysts (Fig. 12), the exudation matter, which forms the bulk of the semi-transparent ones, has almost all disappeared, shewing that it forms the food of the worm. The structure of the largest encysted animals in every point agrees with the description of the strongylus filaria as given by Dujardin.* I therefore content myself with referring to Figs. 10 and 11, which represent the head and tail of a male worm taken out of one of the dark cysts. The two spicula (*a*) between the membranous appendages of the tail, (*b*) are the two penes. It is a rather interesting fact, that these worms have their genital organs developed whilst they are encysted, and they thereby differ in a material point from the cestodes, which invariably remain without genital organs as long as they are encysted. Another fact, which, perhaps, deserves being noticed, is, that by far the greater number of the encysted worms which I examined were males.

Sometimes it happens, that the encysted worms die, and then they may be found in a state of fatty degeneration in their cyst, and after a time every trace of the worm disappears, the only sign of its once having been there being a calcareous concretion of about the size of the original cyst.

I have also watched the changes which the nests undergo after they have discharged their contents. They contract considerably, and, instead of occupying the surface, they are drawn more into the substance of the lungs. At a comparatively early period they form a kind of capsule with irregular cavity and thick walls, but at a later period they also undergo calcification.

* "Histoire Naturelle des Helminthes," p. 122.

In conclusion, I may add, that I have fed two cats on lungs containing the entozoa, one for a fortnight and the other for two months, in order to determine whether the worms could be communicated. In both cases the results were negative; not only had no transmission of the entozoa been affected, but the cats had remained in perfect health up to the time when they were killed.

Dr. H. Ranke, *3rd of November*, 1857.

---

2. *Absence of the Left Foot in a Cat.*

In this preparation there was complete absence of the radius, ulna, and all the bones of the foot, except that in a tuft of hair, about the middle of the humerus, there was a single claw with rudimentary phalanges, and three minute palmar "cushions." On dissection, the upper muscles of the humerus were almost as well-developed as on the opposite limb, but below they all terminated in a tendinous expansion, covering the lower end of the bone. The ulnar nerve passed down the back of the humerus in its ordinary position, and then running over the end of the bone between the condyles, proceeded upwards to be distributed to two small muscles, acting as a flexor and extensor of the claw, to which they were attached.

Dr. T. Ogier Ward, *2nd of November*, 1857.

---

3. *Multi-locular Cystic Tumour, with Villous Intra-cystic Growths, from the Breast of a Bitch.*

This tumour was removed from the breast of a bitch, and was sent up to the Museum of the Middlesex Hospital, by Mr. Amble, of Hemel Hempstead. The entire mass is somewhat globular in general form, and about five inches in diameter. The nipple is on the centre of one side of the tumour, and appeared natural in structure, but the rest of the mammary gland is flattened out by the enormous cystic growth, so that very little of its tissue can be detected. Near the nipple, there is an abraded patch the size of a crown-piece, from which the cuticle is removed, the exposed surface having a not unhealthy appearance.

This abrasion was, no doubt, caused by the rubbing of the surface of the tumour on the ground as the animal had moved about.

On section, the tumour is found to consist of one large cyst, with which many smaller cysts communicate. The great sac contains about a pint and a half of tenacious, brown-coloured serum. All the other cysts are much smaller, and some are minute; many of them communicate with the great sac, but others are quite distinct. The fluid contained in these smaller cysts is mostly clear and pale.

Numerous growths project into these cavities, growing from the inner surface of the cyst-walls, both of the large and of the smaller cysts. These growths are all of small size, the largest in the great cyst not projecting more than a third of an inch into the cavity of the sack, and being about the diameter of a florin. They all present a very distinct and delicate villous appearance, their character being most distinct when the part is placed in water, as all the villi then separate and float out, being supported by the fluid. The colour of these small growths is a pale reddish-yellow; not, however, greatly different from the tint of the lining membrane of the cyst. Some of the very small cysts are nearly, but not perfectly, filled with these villous growths.

The microscopic characters of the growth are rendered obvious by cutting off portions of the villi, and separating them with the points of needles. The structure is essentially the same as that of villous growth in other situations.* The villi appear like a number of glove-like processes projecting from the rather more solid material which forms the base of the tumour. The amount of budding and branching which is observed, varies much in different portions of the growths, but it is nowhere so luxuriant as in similar growths in some other situations. The villi themselves present the same variations in size and length that is observed elsewhere.

In a few of the villi, a distinct and regular columnar epithelium, covers their surface, but in the majority, the epithelium is less definite and distinct in structure. The walls between the epithelial cells appear, in many cases, to have been absorbed, and

* "Trans. Path. Soc.," vol. vii. p. 256 and 212, and vol. viii. p. 18.

the nuclei alone remains visible. This explains how it is that some of the villi appear like simple glove-like dilatations of a homogeneous membrane, filled with granular material, and a few scattered cell-nuclei. The amount of granular material contained in the villi, is also subject to considerable variations, in some cases the granules are accumulated together, of large size, and probably of a fatty nature.

The solid material which forms the basis of each of these growths is composed of delicate connective tissue, with cell-nuclei, and considerable amount of granular blastema. Very little of the connective tissue passes up into the villi.

The vessels are numerous and large in all parts, they extend up in the form of capillary loops into most of the villi.

The tumour is interesting, as illustrating the nature of this form of disease, and more especially as affording an example of the great similarity in structure of "villous disease," as seen in various parts of the body. In the present instance, and in the other cases quoted in the foregoing description, there can be little doubt of the non-malignant nature of the disease. Moreover, this class of growths should be carefully distinguished from the genuine cases of cancer, which sometimes take on the villous or dendritic mode of growth, and are characterized by the presence of the usual structure of cancer, and do not possess the definite and regular structure of simple villous disease here described.

Mr. Septimus W. Sibley, *15th of December*, 1857.

---

4. *Diseased Spleen of a Pig.*

The specimen consisted of the hypertrophied spleen of a pig, in which a low form of fibrous deposit had taken place to an enormous extent. The spleen was six feet long, and weighed fifteen pounds, whilst the normal weight of the healthy pig's spleen is only about half a pound. The diseased mass was of a bright scarlet colour, firmer than usual, and studded on the surface with numerous greyish-white deposits resembling tubercle, and not elevated above the surface. In size they varied from that of a split-pea, to that of half a hazel-nut, and on section, this arrangement gave the spleen the appearance of a huge German sausage. Under the

microscope the tissue of the spleen was found to be hypertrophied, but apparently unaltered, the greyish deposit consisted entirely of imperfect fibrous tissue mixed up with granular matter, and not a single distinct cell could be discovered. The pig had never exhibited any symptom of ague, or in fact of disease of any kind, but had lived with its fellows at a farm-yard, and was believed to be perfectly healthy until it was killed. There was no positive disease of any other organ in the body, but it is probable that some of the fibrous deposit had taken place in the lungs, for the persons who killed the pig cast them away as being "queer-like."

In "Bailey's English Dictionary," under the word "milt," is inserted "milt-pain," "a disease in hogs," from which it may be inferred that the spleen is liable to become diseased in this class of animals, but inquiry has failed to elicit any further information on the subject.

Mr. Mitchell Henry, 15*th of February*, 1858.

---

5. *Mulberry Calculi studded with Crystals, from the Kidney of the Horse.*

These are large specimens of renal calculi taken from the kidney of three different horses, dying of chronic disease; thus (as informed by Mr. Curran, House-Surgeon to the Royal Free Hospital, to whom I am indebted for them), one died from pulmonary phthisis, another from abscess of the liver, and a third from renal abscess associated with pyelitis. All, however, had been pining away for some months before death; their ages were not known.

The respective weights of the calculi are three quarters of an ounce, three ounces and a quarter, and three ounces and a half, the composition of each is oxalate of lime, and they constitute very remarkable examples of the mulberry calculus. The shape of each is somewhat foliaceous and mamillated, the projections giving rise to the latter appearance, springing from distinct bases. In their colour they are a dark brown and are covered with minute crystals, quite visible to the naked eye, especially in the largest specimen, and resemble, in a truly wonderful manner, fine

crystals of ferruginous quartz, in fact, if placed in a collection of minerals, the true distinction would not be noticed unless the the observer was acquainted with calculi. If examined with a good pocket-lens, these delicate crystals are found to be perfect examples of the octahedral crystals of the oxalate of lime, and are seldom seen so large. One surface only is principally noticed throughout, but some of the crystals spring from an apex and thus shew the octahedral form; others, again, lay on their sides, and all of them possess a hardness, I should say almost equal to quartz.

I have reason to believe that the presence of crystals on the surface of calculi is not common, although I find that Dr. Golding Bird and Dr. Owen Rees have described human mulberry calculi, whose surfaces were studded with opaque and transparent octahedral crystals of oxalate of lime. Marcet, Yelloly, and Searling have met with calculi entirely composed of a mass of crystals of oxalate of lime, and the last named author gives an illustration of the kind in his work on "Vesical Calculi,* wherein the nucleus and body of the calculus consist of crystals of oxalate of lime embedded in dried blood, the surface being covered with white crystals of triple phosphate. I may add, that when a calculus contains a central cavity, it will almost invariably be found lined with very beautiful and perfect crystals, which have not inaptly been compared to the crystals of quartz, found lining the cavities in flints, which must be familiar to everyone.

DR. GIBB, 16*th of February*, 1858.

* Translated by Dr. Hoskins, figure 36.

INDEX.

Abdominal section, multi-locular ovarian tumour successfully removed by - - 335
Abscess of the liver, 222, 264, 268, 283
„ — description of the various stages of - - 277
„ — modes in which formed in connection with disease of the tubes of the liver - 273
„ — connection of, with gastro-intestinal ulceration - 241
„ — punctured externally, opening through the lung 252, 258
„ — hydatid - - - 290
„ — secondary - 258, 283
„ — secondary due to obstruction of one of the ducts - 290
„ in the pericardium - 88
„ remains of a pleural - 51
„ secondary, from pyæmia within the walls of the heart - 164
„ pyæmic, in the liver - 278
„ tuberculous, of the anterio-mediastinal glands - - 38
Adams (Mr. W.) spina-bifida in the lumbo-sacral region, ruptured in uterô, associated with talipes varus in both feet (*Case in Mr. Coghlan's practice*) - - - 440
„ — *see* Travers.
Alison (Dr. S. Scott) ossific deposit at the left auriculo-ventricular orifice—concentric hypertrophy—cyst of the kidney and contracted pylorus 102
„ gangrene and perforation of the ileum, with peritonitis, caused by a large biliary calculus 203
Amputation of shoulder-joint, in case of fibro-plastic tumour 367
Amussat's operation, intestinal obstruction relieved by - 214
Anæmia, case of death from 438
Aneurysm of valves of the heart, enumeration of cases in the "Pathological Transactions" 120-1
„ at bases of the aortic valves 79
„ of the aorta fatal by bursting into œsophagus - - 182
„ of the ascending and transverse aorta - - - 97
„ of the arch of the aorta - 167
„ — fatal by rupture into an ulceration of the trachea - 74
„ of the transverse arch of the aorta, fatal by rupture into the pericardium - - 105
„ of the arch of the descending aorta - - - 83
„ of the root of the cœliac axis, spontaneous cure of - 172
„ of the innominate artery, opening into trachea - - 95
„ — spontaneously healed - 167
„ ruptured, of the popliteal artery 122
„ of the right profunda femoris artery - - - 125
Aneurysmal dilatation of the arch of the aorta - - 180
Aneurysmal pouch, with parietes of fibrinous coagulum connected with perforation of mitral valve - - - 117
„ — from adhesion of fibrin to the ulcerated opening of the mitral valve - - 131
„ — of cardiac valves, cases of true and false - - 117
Animals, specimens from the lower 456-64

Aorta, aneurysm of, fatal by bursting into the œsophagus - 182
„ ascending, aneurysm of - 97
„ transverse, aneurysm of - 97
„ arch of the, aneurysm of - 74
„ — aneurysmal dilatation of 180
„ transverse arch of, aneurysm of, fatal by rupture into the pericardium - - - 105
„ arch of the descending, aneurysm of - - - 83
„ abdominal, rupture of, in a child 85
Aortic valves, aneurysm at bases of 79
„ deposits on - - 76
„ diseased - - - 74
„ disease, with obstruction from membrane across the outlet from the ventricle - 184
„ obstructive and regurgitant disease of - - - 61
„ ulceration of - - 79
Apnœa, death by, in paralytic case 24
Apoplectic clots - - 18
Arachnoid membrane, pedunculated villous growth from visceral layer of - - 14
Armitage (Dr.) rupture of the abdominal aorta in a child - 85
„ contraction of the mitral orifice, with extensive fibrinous deposits in both kidneys - 87
Arsenic, neuralgia and paraplegia, supposed to arise from long continued use of - 442
Artery, basilar, dilatation of, fatal by rupture and hæmorrhage 69
„ cerebral, blocking of - 65
„ — obstruction of, by fibrinous plugs - - - 76
„ cœliac, aneurysm of the root of, spontaneously cured - 172
„ coronary, cyst of pericardium, probably owing to the rupture of a branch of - - 165
„ femoral, spontaneous laceration of - - - 159
„ iliac, injected preparation of 95
„ — external, ligature of - 125
„ innominate, aneurysm of the, opening into trachea - 95
„ intercostal, death by opening, in case of epithelial cancer of the œsophagus - - 202
Artery, *continued.*
„ popliteal, ruptured aneurysm of the - - - 122
„ right profunda femoris, aneurysm of - - - 125
„ pulmonary, clots in, undergoing changes - - 91
„ sub-clavian, occlusion of - 74
„ — obstruction of both - 95
„ — right, death by hæmorrhage from, in case of epithelial cancer of the œsophagus - 194
Arterial duct, persistent - 58
Ascites - - - 223
Asphyxia, villous growth from the vocal cords, causing death by 55
Asthenia, death from, in case of aneurysm of the aorta - 97
Auricle, left, old-standing coagulum in - - - 79
„ — globular vegetation, detached from, obstructing the mitral orifice - - - 89
„ — ulceration of the wall of 131
„ auriculo-ventricular orifice, ossific deposit at - - 102
Auricles, congenital and supernumerary, developed on the sides of the neck - 448
Axis and odontoid process, formation of false joint between 346

Balding (Mr. B.) epithelial cancer of the œsophagus, causing death by hæmorrhage from the right sub-clavian artery - 194
„ — *report* on, by Dr. Wilks and Dr. Brinton - - 195
„ — second *report* on, by Dr. Goodfellow and Mr. Sibley 197
„ urine containing cystine - 297
Ballard (Mr. Thomas) tuberculous abscess of the anterior mediastinal glands, bursting into the trachea - - 38
Barclay (Dr.) *see* Hatfield.
Barker (Dr. T. A.) apoplectic clots - - - 18
Basilar artery, dilatation of, fatal by rupture and hæmorrhage 69
Beale (Dr.) *see* Elin.
Bennett (Dr. R.) base of the skull attacked by epithelial cancer - - - 358

Bile, calculus of inspissated - 233
Biliary ducts, dilatation of - 228
„ medullary cancer of - 228
Birkett (Mr. John) a congeries of very large cysts containing milk, developed in the breast 386
„ case of carcinoma fibrosum, or scirrhous cancer of the breast, with cysts containing serum mixed with blood - 388
„ an uncommon variety of cystic disease of the breast - 390
„ five cases of tuberous cancer of the breast, illustrating the natural history and progress of the primary growth - 393
„ chondro-osteoid growth among the muscles of the posterior femoral region; excision; cure 397
„ congenital, supernumerary, and imperfectly developed auricles on the sides of the neck - 448
Bladder, urinary, two enormous calculi of - - 295
„ urinary calculus adherent to 296
„ calculus, three ounces and three quarters, adherent to, removed by lithotomy - - 342
Blocking of the cerebral arteries 65
Blood, states of the, etc., 427-56
Blood, effusion of, into the pons Varolii - - 7
Blood cyst from the thigh - 383
Bones, diseases, etc., of 343-362
Bones of the hand, enchondromatous tumours of - 382
Boyd (Dr.) *per Mr. Obré*, general paralysis; softening of the spinal cord; inflammation of the cerebral membranes - 8
„ softening of the spinal cord; general paralysis, combined with mania - - 10
„ — *report* on, by Dr. George Johnson and Dr. A. Clark, 11
„ abscess? in the pericardium 88
„ — *report* on, by Mr. J. Hutchinson - - - 89
Brain, carcinoma of the - 20
„ softening of the central parts of the - - - 25
Brain, *continued.*
„ softening of left cerebral hemisphere - - - 407
„ villous growth covering one of the hemispheres of - 14
„ arteries of, obstructed by fibrinous plugs - - 76
„ membranes of, cancerous growths connected with - - 2
„ — inflammation of - 8
Breast, cases of tuberous cancer of (primary growth) - 393
„ cystic disease of the, uncommon variety of - - 390
„ large cysts containing milk, developed in the - - 386
„ epithelioma of - - 375
„ epithelial tumour of the - 385
Bright's disease, degenerated kidney in - - - 308
Brinton (Dr. W.) diseased mitral and aortic valves - - 74
„ perforating ulcer of the large intestine in typhoid fever - 199
„ cancerous infiltration of a chronic gastric ulcer - 200
„ disease of the supra-renal capsules, without bronzed skin 414
„ *report* on Mr. Balding's case of epithelial cancer of the œsophagus - - - 195
Bristowe (Dr. J. S.) cancerous growths connected with membranes of the brain, and producing hydrocephalus - 2
„ effusion of blood into the pons Varolii - - - 7
„ gangrenous cavity behind the root of the lung, opening into the left bronchus and œsophagus - - - 46
„ diseased mitral valve, extreme consequent hypertrophy of the right ventricle - - 67
„ dilatation of the basilar artery, fatal by rupture and hæmorrhage - - - 69
„ aneurysm of the transverse arch of the aorta, fatal by rupture into the pericardium - 105
„ *see* Peacock (Dr.) on blocking of cerebral arteries.
„ cases illustrating the causes and effects of obstruction of the hepatic ducts - 218-228

BRISTOWE, *continued.*
„ on the connection between abscess of the liver and gastro-intestinal ulceration - 241
„ — four illustrative cases 252-269
„ on the modes in which hepatic abscesses may be formed in connection with disease of the tubes which ramify throughout the liver - - 273
„ — five illustrative cases 278-94
„ diseased kidney, with observations upon microscopic cysts of the kidney - - 309
„ fatal jaundice, without discoverable structural disease of the liver - - - 432
„ — *report* on, by Drs. Kirkes and J. W. Ogle - - 438
„ and Mr. J. HUTCHINSON, *report* on Dr. Wilks's specimen of fibrous tumours of the ovaries 301
„ *see Supra-renal capsules* (report)
BRONCHIAL GLANDS, diseases of 28-58
Bronchial tubes, fibrinous casts of, expectorated - - 53
Bronchus, left, gangrenous cavity opening into - - 46
Bronzed skin; one supra-renal capsule diseased - - 411
„ in case of limited disease of supra-renal capsules - 412
„ in a boy, with old disorganization of supra-renal capsules 414
„ cancerous right supra-renal capsule, without - - 400
„ disease of supra-renal capsules without - - - 414
„ absence of, in case of cirrhosed and fatty supra-renal capsules 407
„ absence of, in case of scrofulous deposit in supra-renal capsules 410
BRYANT (Mr. Thomas) aneurysm of the right profunda femoris artery—ligature of the external iliac - - - 125
„ extensive nævus, involving the whole of the right leg, in different stages of development 186
„ medullary cystic disease of the testicle - - - 340
BRYANT, *continued.*
„ necrosis of a large portion of the lower jaw - - 345
„ fibrous tumour developed within the lower jaw, surrounding the dental nerve - 351
„ impacted fracture of the neck of the thigh bone - - 357
„ fracture of the neck of the femur within the capsule - 357
„ three cases of disease of the hip-joint - - - 361
„ fibro-plastic tumour in the calf of the leg - - 379
BUCKNILL (Dr.) *per Dr. Quain*, limited disease of the supra-renal capsules in a lunatic; bronzing of the skin - 412

Calcareous matter in pericardial adhesions - - - 165
Calculi, biliary, gall-bladder filled with - - - 251
„ — obstruction of the common duct of the liver by - 285
„ — gangrene and perforation of the ileum, with peritonitis caused by - - 203
„ of inspissated bile, associated with fibrous tumours of the uterus - - - 233
„ urinary, adherent to the bladder 296
„ — weighing three ounces and three-quarters, adherent to bladder, removed by lithotomy 342
„ — two, of enormous size, filling the urinary bladder - 295
„ mulberry, studded with crystals, from the kidney of a horse 463
CALLENDER (Mr. George W.) perforation of the septum ventriculorum; clots in some of the pulmonary arteries undergoing various changes - - 91
„ recurrent fibroid tumour of the uterus with similar growths in the pericardium, the lungs, and in the body of the sixth cervical vertebra - - 327
Cancer of the liver 212, 224, 234
„ of walls of common hepatic duct - - - 224
„ of the lungs and heart - 29

Cancer, *continued.*
„ case of intra-thoracic, affecting lungs and heart, and projecting through the sternum 29
„ of the œsophagus - 211
„ of the omentum, involving coats of the colon - - 214
„ of lesser omentum - 225
„ of the peritonæum - 224
„ of pylorus, duodenum, etc., 225, 237
„ of the spine - - 350
„ of the stomach - 211, 224
„ of the cardiac extremity of the stomach with perforation 212
„ colloid, of the peritoneum involving omentum, ovaries, etc. 207
„ epithelial, base of the skull attacked by - - 358
„ — of the œsophagus 194, 202
„ medullary, of the common bile duct - - - 228
„ osteoid, combined with myeloid disease - - - 377
„ scirrhous, of the breast, with cysts containing serum and blood - - - 388
„ tuberous, of the breast (primary growth) - - - 393
Cancerous deposit in right suprarenal capsule - - 400
Cancerous growths connected with membranes of brain - 2
„ — in the pancreas - 228
Cancerous infiltration of a chronic gastric ulcer - - 200
Cancerous nodules in the substance of the heart - - 87
Cancerous tumours beneath the endocardium - - 128
Carcinoma of the brain - 20
„ fibrosum of the breast - 388
„ *see Cancer.*
Casts, fibrinous, of the bronchial tubes, expectorated - 53
„ — of the pharynx - 206
„ tubular exudation, of the intestine - - - 188
„ — of the trachea at its bifurcation - - - 52
Cat, absence of the left foot in a, 460
Cephalhæmatoma, double sub-pericranial - - - 380
Cerebral arteries, blocking of 65
Cervix uteri, cystic tumour of, removed by the écraseur 332
CHALK (Mr. Oliver), morbus coxæ; death from encephalitis 353
Chondro-osteoid growth among posterior femoral muscles (excision and cure) - - 397
CIRCULATION, ORGANS OF, diseases, malformation, etc. - 58-188
Cirrhosis - - - 222
„ of the liver - - 231
CLARK (Dr. Andrew) *report* on Dr. Boyd's cases of general paralysis, etc. - - 11
„ *report* on Mr. T. B. Curling's case of epithelial cancer of the larynx - - - 42
„ *report* on Mr. Hutchinson's case of tubular casts of the intestine 189
Clitoris, specimen of enlarged 305
Clots, apoplectic - - 18
Clot, fibrinous, from the right ventricle of the heart - 99
Coagulum, old-standing, in the left auricle - - - 79
„ fibrinous detached from the left auricle, obstructing the mitral orifice - - - 89
COCKLE (Dr.) aneurysm of the ascending and transverse aorta—death in three years from asthenia, the sac being unruptured — supervention of gangrene of the nose, three days prior to death - - 97
Cœliac axis, aneurysm of the root of, spontaneously cured - 172
Coghlan's (Mr.) case of spina-bifida in lumbo-sacral region, *see* ADAMS (W.)
Coleman's (Mr.) notes on cases of badly developed teeth, the effect of infantile syphilis - 453
Colloid cancer of the peritoneum 207
Colon, rupture of, from distention of the gases within it - 213
„ scirrhus cancer of the omentum, involving the coats of - 214
„ sigmoid flexure of, malignant disease of - - 213
Coma, deep, followed by return of consciousness before death 27
Congenital deficiency of the sternum - - - 71

Cornea, adhesion of retina to the cicatrix following removal of 362
Corpora lutea, ovaries shewing false 323
„ peculiar crystalloid bodies in the colouring matter of - 323
Coxæ, morbus - - 353
Crystalloid bodies, peculiar, in the colouring matter of the corpus luteum - - - 323
Curling (Mr. T. B.) epithelial cancer of the larynx, with extension of the disease to the œsophagus; tracheotomy twelve months' before death - 39
„ — *report* on, by Dr. Andrew Clark - - - 42
„ large hydrocele in the right groin; the testicle being undeveloped and detained in the inguinal canal - - - 316
„ *see* Page (Mr. B.).
Cysts, etc. - 367-400
Cysts containing serum and blood, in case of cancer of the breast 388
„ large, containing milk, developed in the breast - 386
„ of kidney - - 102
„ — microscopic - - 309
„ large rounded, in the substance of the liver - - 237
„ large, beneath visceral layer of the pericardium, filled with laminated blood - coagulum 165
„ blood, from the thigh - 383
„ ovarian, dilatation of kidneys and ureters from pressure of 318
„ — tapped four years' before, and not filled again until a week before, death of patient - 318
„ — multi-locular, successfully removed by ovariotomy - 321
Cystic disease of the breast, uncommon variety of - - 390
„ of the kidney - - 334
„ medullary, of the testicle - 340
„ tumour, multi-locular, from the breast of a bitch - 460
„ — of the cervix uteri, removed by the écraseur - - 332
Cystine, urine containing - 297
Daubeny (Dr. H.) Hydatids formed and discharged subsequent to injury to the tibia - 430
Death, sudden, case of, from contraction of the mitral orifice 89
Deficiency, congenital, of the latissimus dorsi and pectoralis major muscles - - 427
„ congenital of the sternum - 71
Deformity, in case of fracture of the femur - - - 343
Deposits, fibrinous, in the kidneys, minute anatomy of - 305
„ — in both kidneys, with contraction of the mitral orifice 87
„ ossific, at the left auriculo-ventricular orifice, - - 102
Diabetes, sugar in the tears, from a case of - - - 447
Digestive Organs, diseases, etc. of - - 188-295
Dilatation of basilar artery, fatal by rupture and hæmorrhage - 69
„ of biliary ducts - - 228
„ partial, of hepatic ducts - 220
„ and destruction of hepatic ducts 223, 285
„ hypertrophy of the heart without 124
„ of the kidneys and ureters, from pressure of ovarian cyst - 318
Diphtherite, cases of - - 217
„ fibrinous cast of the pharynx ejected by a patient suffering from - - - 206
Diseases, etc., of the nervous system - - 1-28
„ of the organs of respiration (bronchial and mediastinal glands) - - 28-58
„ of the organs of circulation 58-188
„ of the digestive organs 188-295
Diseases, etc., of digestive organs 188-295
„ — I. pharynx, œsophagus, stomach and intestines 188-218
„ — II. liver and its appendages 218-295
„ of the genito-urinary organs 295-342
„ of the osseous-system 343-362
„ of the organs of special sense 362-367
„ tumours, morbid growths, cysts, etc., - - 367-400

DISEASES, *continued.*
„ ductless glands; I. supra-renal capsules - 400-424
„ — II. the spleen - 425-426
„ miscellaneous specimens 427-456
„ specimens from the lower animals - - 456-464
Ducts, hepatic, *see Hepactic ducts*
Ductus arteriosus, persistent, - 58
DUNHILL'S (Dr.) case of tubular exudation casts of the intestine 188
Duodenum, cancer of - 225
„ perforating ulcer of the - 197
Dysentery, in case of abscess of the liver 252, 258, 264, 268
Dysphagia, in a case of softening of spinal cord, etc. - - 25

Ecraseur, cystic tumour of cervix uteri removed by the - 332
Effusion of blood into the pons Varolii - - - 7
ELIN (Dr.), *per Dr. Beale*, malformation of the rectum - 205
Emphysema, ulcer of the larynx in typhoid fever, producing 34
Empyema, paracentesis - 264
Encephalitis, death from, in case of morbus coxæ - - 353
Encephalocele, case of, presenting at the root of the nose - 1
Enchondroma of the testicle - 326
Enchondromatous tumours of the bones of the hand - 382
Endocarditis on the right side of the heart - - 128
Entozoic, pulmonary, disease of sheep - - - 456
Epithelial growth from the larynx 36
„ cancer of the larynx and œsophagus - - 39
„ — of the œsophagus 194, 202
„ — base of the skull attacked by 358
Epithelial tumour of the breast 385
„ — in sheath of sciatic nerve 11
Epithelioma of the female breast 375
Excision, head of the femur removed by - - 349
„ diseased knee-joint, removed by 347
Extraction, operation of, hæmorrhage supervening on - 364
Eyeball, appearances on dissection of, after excision - - 364
„ excision of, on hæmorrhage after extraction - - 364
„ malignant growth within the 365
Eyes, prominence of, in case of affection of the heart - 163

Fallopian tubes, enormous elongation of, in case of ovarian cyst 318
False-joint, formation of, between odontoid process and body of the axis - - - 346
Fatty tumour, two specimens of 384
Femoral artery, spontaneous laceration of - - - 159
Femur and hip-joint from a case of talipes equinus paralyticus 432
Femur, head of, removed by excision - - - 349
„ fracture of the neck of the 344
„ — within the capsule - 357
„ comminuted fracture of the lower extremity of - 343
Fibre, striated muscular, in mitral valve, a natural condition 109
Fibrin, aneurysmal pouch from adhesion of, to ulcerated opening of mitral valve - - 131
„ cavity in the heart's walls containing broken-down - 131
Fibrinous cast of the pharynx, in case of diphtherite - 206
Fibrinous clot, from the right ventricle of the heart - 99
„ — in the heart, in case of death from anæmia - - 438
Fibrinous coagulum detached from the left auricle, obstructing the mitral orifice - - 89
„ — parietes of aneurysmal pouch formed of - - 117
Fibrinous deposits in the kidneys, minute anatomy of - 305
„ — in both kidneys, with contraction of the mitral orifice 87
Fibrinous plugs, obstruction of cerebral arteries by - - 76
Fibro-cellular growth of the lung 31
Fibro-plastic tumour of the humerus, containing myeloid cells 367
„ — of upper extremity of the humerus - - 398
„ — in the calf of the leg 379

Fibroid tumour, recurrent of the uterus, pericardium, etc. 327
Fibrous tumour in the lower jaw, surrounding the dental nerve 351
„ — of the ovaries - - 299
„ — of the uterus - - 233
FLOWER (Mr. W. H.), epithelial tumour in the sheath of the sciatic nerve - - 11
Foot, absence of left foot in a cat 460
„ case of nine toes on one foot 427
Fracture of the neck of the femur 344
„ — within the capsule - 357
„ comminuted, of the lower extremity of the femur - 343
„ impacted, of the neck of the thigh-bone - - 357
FULLER (Dr.), large, tough, fibrinous clot from the right ventricle of the heart - 99
„ fibrinous cast of the pharynx, ejected by a patient suffering from diphtherite - - 206
„ ovarian cyst, tapped four years before the death of the patient, which did not fill again until a week before her death; elongation of Fallopian tubes, dilatation of kidneys, etc. - 318

Gall-bladder, enlargement of the 228
„ filled with four biliary calculi 231
Gangrene of the nose, prior supervention of, in case of death from asthenia - - 97
Gangrene and perforation of the ileum from biliary calculus 203
Gangrenous cavity behind the root of the lung opening into left bronchus and œsophagus - 46
GENERATION, ORGANS OF, diseases 295-342
GIBB (Dr.) cirrhosis of the liver—the gall-bladder filled with four biliary calculi, one of them encysted - - 231
„ calculus of inspissated bile, associated with fibrous tumours of the uterus - - 233
„ double sub-pericranial cephalhæmotoma - - 380
GIBB, *continued.*
„ neuralgia and paraplegia, supposed to be due to the long-continued use of arsenic, of which a trace was found in the liver and bones - - 442
„ sugar in the tears from a case of diabetes - - 447
„ mulberry calculi studded with crystals from the kidney of a horse - - 463
GIBBON (Dr. Septimus) scirrhus cancer of the omentum involving the coats of the colon—intestinal obstruction relieved by Amussat's operation - 214
GLANDS, enlarged, etc. 367-400
GLANDS (DUCTLESS) supra-renal capsules - 400-424
„ — spleen - - 425-426
Glands, anterio-mediastinal, tuberculous abscess of - 38
GOODFELLOW (Dr.), *report* on Mr. Balding's case of epithelial cancer of the œsophagus 197
Groux's (E. A.) case, congenital deficiency of the sternum 71
GROWTHS, MORBID, etc. 367-400

Hæmorrhage supervening on the operation of extraction - 364
„ from intercostal artery, death by, in case of epithelial cancer of the œsophagus - - 202
„ from right sub-clavian artery, death by, in case of epithelial cancer of the œsophagus - 194
Hand, enchondromatous tumours of the bones of the - - 382
HARE (Dr. C. J.) hydatids expectorated from the left lung 28
„ aneurysmal dilatation of the arch of the aorta, chiefly within the pericardium - - 180
HARLEY (Dr. George) living specimen of a rat, with both supra-renal capsules and spleen removed - - - 401
„ diseased supra-renal capsule, removal by operation, from a healthy animal - - 401
„ scrofulous disease of the supra-renal capsules - - 402

HARLEY, *continued.*
„ extensive scrofulous deposit in the supra-renal capsules; death by acute pulmonary phthisis, absence of bronzed skin - 410
„ *see Supra-renal capsules* (report)
HATFIELD (Mr.) *per Dr. Barclay*, oil from the cavity of the pleura - - - 32
Heart, affection of the, with enlargement of the thyroid, etc. - 163
„ bruise within the - - 125
„ case of cancer of - - 29
„ cancerous nodules in the substance of the - - 87
„ endocarditis on the right side of the - - - 128
„ fibrinous clots in the, in case of death from anæmia - 438
„ in which frothy blood was found 154
„ hypertrophy of the, with remarks on seventy cases - 173
„ — without dilatation or valvular disease - - - 124
„ — concentric - - 102
„ movements of, visible through congenital deficiency of the sternum - - - 71
„ sounds of the, peculiarity in 131
„ post-mortem examination of, in case of ulceration of the aortic valves - - - 81
„ valves of the, ulceration of, *table* of cases of - 134-144
„ — analysis of facts in ditto 145-8
HEATH (Mr. Christopher) cancer of the stomach and œsophagus 211
„ aneurysm of the innominate artery, opening into the trachea, with obstruction of both subclavian arteries - - 95
„ cancer of the liver and cardiac extremity of the stomach, with perforation - - 212
„ tubercular disease of the testicle 307
„ edentulous lower jaw having no mental foramina - - 360
„ large fibro-plastic tumour, connected with upper extremity of the humerus - - 398
„ see TODD.
Hemiplegia - - - 20
„ of the right side - - 407
HENRY (Mr. Mitchell) rupture of the urethra of many years' duration, without symptoms until shortly before death 337
„ calculus, weighing three ounces and three-quarters, adherent to the bladder, removed by lithotomy, from a boy - 342
„ fibro-plastic tumour of the humerus, containing myeloid cells; amputation of shoulder joint; recurrence of disease; death, etc. - - 367
„ diseased spleen of a pig - 462
Hepatic ducts, cancer of walls of common duct - - 224
„ partial dilatation of - 220
„ dilatation, suppuration and destruction of - - 285
„ dilatation and destruction of 219, 223
„ obstruction of, cases illustrating the causes and effects of 218-28
„ obstruction and dilatation of 223, 224, 225
„ obstruction of, by a gall-stone 219, 223
„ obstruction of, by a tumour in its walls - - - 220
„ stricture and dilatation of 222
HEWITT (Dr. Graily) persistent ductus arteriosus, etc. - 58
„ the left common iliac, the left external iliac and part of the femoral veins with part of the lower vena cava, from a case of phlegmasia dolens - 59
„ ovaries shewing false corpora lutea with commencing cystic disease; peculiar crystalloid bodies in the colouring matter of the corpus luteum - 323
„ *report* on Mr. Hutchinson's cases of infantile syphilis 455
HINTON (Mr. J.), pigment in the tympanum - - 363
Hip-joint, disease of, - - 353
„ — three cases - - 361
HOLMES (Mr. T.) case of intra-thoracic cancer, which affected the lungs and heart, and projected out of the chest through an opening in the sternum 29

HOLMES, *continued.*
„ secondary abscess from pyæmia within the walls of the heart 164
„ spontaneous cure of aneurysm of the root of the cœliac axis 172
„ pedunculated polypus from the rectum - - - 212
„ tumours, probably enchondromatous, of the bones of the hand - - - 382
„ blood cyst from the thigh - 383
„ scrofulous deposit in the supra-renal capsules - - 405
„ two supra-renal capsules affected by scrofulous matter, and taken from a patient who had died of phthisis and pneumothorax - - - 414
Horse, mulberry calculi, studded with crystals from the kidney of the - - - 463
HULKE (Mr. J. W.) Hæmorrhage supervening on extraction—immediate excision of the eyeball; appearances on dissection of eyeball - - 364
HULME (Mr. E. C.) malignant growth within the eyeball 365
Humerus, fibro-plastic tumour of, containing myeloid cells - 367
„ fibro-plastic tumour of upper extremity of - - 398
HUTCHINSON (Mr. J.) tubular exudation casts of the intestine 188
„ — *report* on, by Dr. Wilks and Dr. Andrew Clark - 189
„ enchondroma of the testicle 326
„ multi-locular ovarian tumour successfully removed by abdominal section - - 335
„ bronzing of the skin, in a boy, with old disorganization of both supra-renal capsules - 414
„ illustrations of the effects of infantile syphilis in marring the development of the teeth - 449
„ — Mr. Coleman's notes on the same cases - - - 453
„ — *report on*, by Dr. G. Hewitt, Mr. H. Lee, and Mr. H. Thompson - - - 455
„ *report* on Dr. Boyd's [doubtful] case of abscess in the pericardium - - - 89
„ *see* ROBERTS, BRISTOWE.
„ *see Supra-renal capsules* (report)

Hydatid abscess of liver - 290
Hydatids, large, in the liver - 294
„ expectorated from the left lung 28
„ formed and discharged subsequent to injury to the tibia 430
Hydrocele, large, in the right groin 316
Hydrocephalus, cancerous growths connected with membranes of the brain, producing - 2
Hypertrophy of the heart, with remarks on seventy cases - 173
„ — without dilatation or valvular disease - - - 124
„ — concentric - - 102
„ of the right ventricle, from diseased mitral valve - 67
„ of the right testicle - 317

Ileum, gangrene, and perforation of, from biliary calculus - 203
Inflammation of the cerebral membranes - - - 8
„ of the stomach and jejunum, 279
Inguinal canal, undeveloped testicle detained in - - 316, 317
INTESTINES, diseases of 188-218
Intestine, diseased, from a patient who died of typhoid fever, during relapse - - 209
„ tubular exudation casts of the 188
„ large, perforating ulcer of, in typhoid fever - - 199
Intestinal obstruction relieved by Amussat's operation - 214

Jaundice, intense - - 228
„ fatal, without discoverable structural disease of the liver 432
Jaw, lower, edentulous, having no mental foramina - - 360
„ — necrosis of - - 345
„ — fibrous tumour in, surrounding the dental nerve - 351
Jejunum, inflammation of the 279
JOHNSON (Mr. Athol) case of polydactylism, in which nine toes existed on one foot - 427
JOHNSON (Dr. Geo.) on the minute anatomy of the so-called fibrinous deposits in the kidneys - - - 305

JOHNSON, *continued.*
„ *report* on Dr. Boyd's case of general paralysis, etc. - 11
JOHNSON (Dr. Salkeld) necrosis of the tibia, from a child twenty-eight days old - - 352
Joints, *see Knee-joint, Hip-joint, Shoulder-joint.*
Joint, false, between the odontoid process and the axis - 346
JONES (Dr. Sydney) epithelial cancer of the œsophagus, causing death by opening an intercostal artery - - 202

Kidney, diseased - - 309
„ cyst of - - - 102
„ cystic disease of - - 334
„ microscopic cysts of - 309
„ degenerated, in Bright's disease 308
„ dilatation of, from pressure of ovarian cyst - - 318
„ fatty - - - 222
„ fibrinous deposits in, minute anatomy of - - 305
„ of a horse, mulberry calculi, studded with crystals from 463
KIRKES (Dr. W. S.) *report* on Dr. Bristowe's case of fatal jaundice - - - 438
Knee-joint, diseased, removed by excision - - - 347
„ fracture of the femur extending into - - - 343
„ ulceration of patella, after removal of - - 348

Laceration, spontaneous, of the femoral artery - - 159
Larynx, disease of the, supposed to be syphilitic - - 55
„ epithelial cancer of - 39
„ epithelial growth from the 36
„ ulcer of, in typhoid fever - 34
LEARED (Dr.) Case of death from anæmia; fibrinous clots in the heart - - - 438
LEE (Mr. Henry) *report* on Mr. Hutchinson's cases of infantile syphilis - - - 455
Leg, fibro-plastic tumour in the calf of - - - 379
„ specimen of enlarged clitoris 305
Legs, partial loss of sensibility and power of motion in - 25
LEGGATT (Mr. Alfred) spontaneous laceration of the femoral artery 159
Lithotomy, calculus three ounces and three quarters weight adherent to bladder, removed by 342
LIVER and its appendages, diseases of - - - 218-295
Liver, disease of the, supposed to be syphilitic - - 55
„ syphilitic disease of - 270
„ disease of the tubes of, in connection with hepatic abscesses 273
„ abscess, of the, 222, 252, 258, 264, 268
„ — with secondary ditto 283
„ — connection of, with gastro-intestinal ulceration - 241
„ — pyæmic - - 278
„ — secondary, due to obstruction of one of the ducts - 290
„ obstruction of the common duct of, by a calculus - - 285
„ cancer of the 212, 224, 234
„ colloid cancer of surface of 207
„ cirrhosis of the - - 231
„ large rounded cyst in the substance of - - 237
„ hydatid abscess of - 290
„ large hydatid in - - 294
„ knotty tumour of - - 223
„ see *Hepatic ducts*
Lung, disease of the, supposed to be syphilitic - - 55
„ case of cancer of - - 29
„ fibro-cellular growth of the 31
„ recurrent fibroid tumour of 327
„ gangrenous cavity behind the root of the - - 46
„ hydatids expectorated from the left - - - 28
„ communication of hepatic ducts with - - - 285

MALFORMATION of outward parts, etc. - - 427-56
Malformation, congenital, disease of aortic valves probably dependent on - - 61
„ of the rectum - - 205
„ fatal jaundice, without discoverable structural disease of 432
Malignant growth within the eyeball - - - 365

Mania, general paralysis combined with - - - 10
MARKHAM (Dr.), remains of a pleural abscess - - 51
„ simple hypertrophy of the heart without dilatation or valvular disease - - - 124
„ bruise within the heart - 125
„ affection of the heart, with enlargement of the thyroid and thymus glands, and prominence of the eyes - - 163
„ rupture of the colon produced by distention of the gases within it; malignant disease of the sigmoid flexure of the colon - - - 213
„ cystic disease of the kidney 334
MAY, jun. (Mr. G.) heart in which frothy blood was found - 154
MAYO (Mr. C.) *per Mr. T. Smith*, aneurysm of the arch of the descending aorta - - 83
MEDIASTINAL GLANDS, diseases of 28-58
Mediastinal glands, tuberculous abscess of anterior - 38
Medullary cystic disease of the testicle - - - 340
Membranes of the brain, cancerous growths connected with - 2
„ — inflammation of the - 8
Meningitis, scrofulous - 25
Milk, large cysts containing, developed in the breast - 386
Mitral orifice, contraction of, with fibrinous deposits in kidneys 87
„ sudden death from contraction of - - - 89
„ obstruction of, by a globular vegetation detached from the left auricle - - 89
Mitral valves, diseased - 74
„ diseased, with hypertrophy of right ventricle - - 67
„ deposits on - - 76
„ striated muscular fibre, in a natural condition - 109
„ perforation of, the result of ulceration - - 117
„ ulceration of - - 131
MURCHISON (Dr.) perforating ulcer of the duodenum - 197
„ cancerous deposit in the right supra-renal capsule; left one normal; no bronzed skin 400
Muscle, latissimus dorsi, congenital deficiency of - - 427
„ pectoralis major, congenital deficiency of - - 427
„ posterior femoral, chondro-osteoid growth among (excision and cure) - - 397
Muscular cords, substitution of, for tendinous ones in the heart 109
Muscular fibre, striated, in mitral valve, a natural condition 109
„ — enumeration of writers on the point, - - 111-112
Myeloid cells, fibro-plastic tumour of the humerus, containing 367
„ disease, case of osteoid cancer combined with - - 377

Nævus, extensive, involving the whole of the right leg - 186
Neck, congenital auricles developed on the sides of the - 448
Necrosis of lower jaw - 345
„ of the tibia, from a child twenty-eight days old - - 352
Nerve, dental, fibrous tumour in lower jaw, surrounding 351
„ sciatic, epithelial tumour in sheath of - - 11
NERVOUS SYSTEM, diseases, etc., of 1-28
Neuralgia, supposed to be from long-continued use of arsenic 442
Nose, case of encephalocele, presenting at the root of - 1
„ gangrene of the, prior supervention of, in case of death from asthenia - - 97
NUNN (Mr. T. W.) injected preparation of the iliac arteries from a male subject which presented an example of talipes equinus on the left side - - 95
„ series of eleven uteri and appendages with the left ovary at a greater distance than the right one - - 308
„ drawing of a case of congenital deficiency of the latissimus dorsi, and of the lower portion of the pectoralis major muscles 427

NUNN, *continued.*
„ femur and hip-joint taken from a patient who had been affected by talipes equinus paralyticus 432
OBRE (Mr.) *see* BOYD.
Obstruction of the hepatic ducts, cases illustrating the causes and effects of - - 218-228
Occlusion of the sub-clavian artery 74
Odontoid process, and the axis, formation of false joint between 346
ŒSOPHAGUS, etc., diseases of 188-218
Œsophagus, cancer of the - 211
„ epithelial cancer of the 39, 194
„ gangrenous cavity opening into 46
„ aneurysm of aorta fatal by bursting into - - - 182
OGLE (Dr. John W.) peculiar pedunculated villous growth from the visceral layer of the arachnoid membrane covering the upper part of one of the cerebral hemispheres - - 14
„ carcinoma of the brain, etc.; hemiplegia, paralysis of motion and sensibility; increased temperature of paralyzed parts; peculiar movement of paralyzed hand; death by apnœa 20
„ softening, without discoloration, of the spinal cord from the pressure of strumous matter; softening of the central parts of the brain and scrofulous meningitis - - - 25
„ heart, shewing striated muscular fibre in anterior segment of the mitral valve, and substitution of muscular for tendinous cords, with observations on ditto as a natural condition - 109
„ pouch, simulating a true aneurysmal pouch, with thick parietes of fibrinous coagulum connected with a perforation of the mitral valve, etc. - 117
„ ulceration partly of the mitral valve and partly of wall of the left auricle—aneurysmal pouch from adhesion of fibrin to the ulcerated opening—cavity in the heart's walls containing broken down fibrin—peculiarity in sounds of heart - - 131
„ large cyst beneath the visceral layer of the pericardium covering posterior surface of the right ventricle, etc., calcareous matter in pericardial adhesions 165
„ specimen shewing a large spontaneously-healed aneurysm of the innominate artery, along with a smaller one of the arch of the aorta—death by phthisis pulmonalis - - 167
„ large rounded cyst in the liver, containing fluid, and surrounded by carcinomatous material —cancer of the pylorus of the stomach - - - 237
„ large multi-locular ovarian tumour - - - 325
„ two supra-renal capsules of unusual form and position; substance, healthy - - 406
„ cirrhosed and fatty condition of the supra-renal capsules; absence of bronzing of the skin; softening of the left cerebral hemisphere; hemiplegia of the right side - - - 407
„ *report* on Dr. Bristowe's case of fatal jaundice - - 438
„ see *Supra-renal capsules* (report)
Oil from the cavity of the pleura 32
Omentum, cancer of lesser - 225
„ colloid cancer of great - 207
„ scirrhus cancer of, involving coats of the colon - 214
ORGANS OF SPECIAL SENSE, diseases, etc., of - 362-367
OSSEOUS SYSTEM, diseases of 343-362
Ossific deposit at the left auriculo-ventricular orifice - 102
Osteoid cancer combined with myeloid disease - 377
Ovarian cyst, dilatation of kidneys and ureters from pressure of 318
„ tapped four years before, and not filled again until a week before death of patient 318
„ multi-locular, successfully removed by ovariotomy - 321

Ovarian tumour, large multi-locular 325
„ multi-locular, successfully removed by abdominal section 335
Ovaries, colloid cancer of 207
„ fibrous tumours of the 299
„ shewing false corpora lutea, with cystic disease - - 323
Ovary, left, at a greater distance from the uterus than the right one (instances of) - 308
Ovariotomy, multi-locular ovarian cyst, successfully removed by 321

PAGE (Mr. B.) *per Mr. T. B. Curling*, undeveloped left testicle, detained in the groin, outside the abdominal ring; hypertrophy of the right testicle 317
Pancreas, cancerous growth in the 228
Paralysis, general - - 8
„ — combined with mania - 10
„ of motion and sensibility 20
Paralyzed hand, peculiar movement of - - - 23
Paralyzed parts, increased temperature of - - - 23
Paraplegia, supposed to be from long-continued use of ar enic 442
PART (Mr. James) aneurysm of the aorta fatal, by bursting into the œsophagus - - 182
„ fracture of the neck of the femur 344
Patella, ulceration of, after removal of the knee-joint - - 348
PEACOCK (Dr.) fibrinous casts of the bronchial tubes expectorated - - - 53
„ obstructive and regurgitant disease of the aortic valves, probably dependent on congenital malformation - - 61
„ case of aortic valvular disease, with obstruction caused by a band of membrane extending across the outlet from the ventricle - - - 184
„ intestine presenting old and recent disease, from a patient who died of typhoid fever during relapse - - 209

PEACOCK, *continued.*
„ *examination* of the heart in Mr. Shillitoe's case of ulceration of the aortic valves - - 81
„ and Dr. BRISTOWE, blocking of the cerebral arteries - 65
Pedunculated polypus from the rectum - - - 212
Pedunculated villous growth from visceral layer of the arachnoid 14
Perforation of hepatic veins, abscesses of liver from - 283
„ of the ileum, from biliary calculus - - - 203
„ of the septum ventriculorum 91
Pericardium, abscess? in the - 88
„ calcareous matter in adhesions of 165
„ large cyst beneath the visceral layer of - - - 165
„ recurrent fibroid tumour of 327
„ rupture of aneurysm of aorta into - - - 105
Peritoneum, cancer of - - 224
Peritonitis, in case of gangrene of the ileum - - 203
Pharynx, fibrinous cast of the, in case of diphtherite - 206
Phlebitis, extensive adhesive in connection with endocarditis 128
Phlegmasia dolens, iliac, and femoral veins from a case of - 59
Phthisis pulmonalis, death by, in case of aneurysm of the innominate artery - - 167
„ — incipient, in case of abscess of the liver - - 264
„ — death by acute - - 410
„ — and pneumo-thorax, case of death from - - 414
Pig, diseased spleen of a - 462
Pigment in the tympanum - 363
Pleura, oil from the cavity of the 32
Pleural abscess, remains of - 51
POLLOCK (Dr.) epithelial growth from the larynx - - 36
Polydactylism, case of, nine toes on one foot - - - 427
Polypus, pedunculated, from the rectum - - - 212
Pons Varolii, effusion of blood into the - - - 7

PRICE (Mr.) diseased knee-joint removed by the operation of excision - - - 347
„ ulceration of the under surface of the patella, occurring after removal of the knee-joint 348
„ head of the femur removed by the operation of excision 349
Prostate, enlargement of, affecting mainly its anterior portion 298
Ptosis, in a case of softening of spinal cord, etc. - - 25
Pulmonary arteries, clots in, undergoing changes - - 91
Pulmonary entozoic disease of sheep 456
Purpura, tubercular disease of the spleen, from a child suffering from - - - 425
Pus in the portal veins - 279
Pyæmia within the walls of the heart, secondary abscess from 164
Pyæmic abscess in the liver - 278
Pylorus, cancer of - 225,237
„ contracted - - 102

QUAIN (Dr. R.) see BUCKNILL.

RANKE (Dr. H.) pulmonary entozoic disease of sheep - 456
Rat, living, with both supra-renal capsules and spleen removed 401
„ removal of a diseased supra-renal capsule from - 401
Rectum, malformation of the - 205
„ pedunculated polypus from the 212
RESPIRATION, diseases, etc. of the organs of - 28-58
Retina, adhesion of, to the cicatrix following removal of the cornea 362
ROBERTS (Mr. B.) *per Mr. Hutchinson*, tubular cast of the trachea at its bifurcation - 52
Rupture of the abdominal aorta in a child - - - 85
„ of the colon from distention of the gases within it - 213
„ of the urethra, without symptoms until near death - 337

Sciatic nerve, epithelial tumour in sheath of - - - 11
Scirrhous cancer of the breast, with cysts containing serum and blood - - 388
Scirrhus of the omentum - 214
Scrofulous deposit and disease in the supra-renal capsules 402, 405, 410, 414
SENSE, organs of special, diseases, etc., of - - 362-367
Septum ventriculorum, perforation of - - - 91
SHAW (Mr. A.) case of encephalocele, presenting at the root of the nose - - - 1
„ formation of a false joint between the odontoid process and body of the axis - - 346
Sheep, pulmonary entozoic disease of - - - 456
SHILLITOE (Mr. Buxton) case of ulceration of the aortic valves with aneurysm at their bases; old-standing coagulum in the left auricle - - 79
„ — post-mortem examination of ditto [the heart by Dr. Peacock] - - - 80
Shoulder-joint, amputation of, in case of fibro-plastic tumour 367
SIBLEY (Mr. Septimus W.) endocarditis on the right side of the heart, caused by small cancerous tumours beneath the endocardium, in connection with extensive adhesive phlebitis 128
„ extensive tubercular disease of the spleen from a child suffering from purpura - 425
„ multi-locular cystic tumour, with villous intra - cystic growths, from the breast of a bitch - - - 460
„ *report* on Mr. Balding's case of epithelial cancer of the œsophagus - - - 197
„ *see Supra-renal capsules* (report)
Sigmoid flexure of colon, malignant disease of - - 213
Skin, diseases of, *see Bronzed skin.*
SMITH (Mr. T.) two specimens of fatty tumour - - 384
„ *see* MAYO.
Softening of the central parts of the brain - - - 25

Softening, *continued.*
„ of the left cerebral hemisphere, in case of diseased supra-renal capsules - - - 407
„ of the spinal cord - 8, 10
„ — without discoloration, from pressure of strumous matter 25
SPECIMENS (MISCELLANEOUS) 427-456
„ FROM THE LOWER ANIMALS 456-464
Spina-bifida in lumbo-sacral region, ruptured in utero - 440
Spine, cancer of the - - 350
Spinal cord, softening of the 8, 10
„ — without discoloration, from presence of strumous matter 25
Spleen, tubercular disease of, from a child suffering from purpura 425
„ removal of, from a living rat 401
„ diseased, of a pig - - 462
SQUIRE (Mr. W.) aneurysm of the arch of the aorta, fatal by rupture into an ulceration of the trachea; occlusion of the sub-clavian artery - - 74
Sternum, congenital deficiency of (E. A. Groux's case) - 71
„ case of intra-thoracic cancer, projecting through the - 29
STOMACH, etc., diseases of 188-218
Stomach, cancer of the 211, 224
„ cancer of cardiac extremity of, with perforation - - 212
„ inflammation of the - 279
„ chronic ulcer - - 279
Strumous matter, softening of spinal cord, from pressure of 25
Sub-clavian artery, occlusion of 74
Sugar in the tears, from a case of diabetes - - - 447
Suppuration in case of chronic ulcer of the stomach - - 279
SUPRA-RENAL CAPSULES 400-24
Supra-renal capsules of unusual form and position, substance healthy - - - 406
„ one diseased; with bronzed skin 411
„ limited disease of, with ditto 412
Supra-renal capsules, *continued.*
„ old disorganization of; with ditto - - - 414
„ scrofulous deposit in, with ditto 405
„ disease of, without bronzed skin 414
„ cancerous deposit in right, without ditto - - - 400
„ cirrhosed and fatty condition of without ditto - - 407
„ scrofulous deposit in, without ditto - - - 410
„ scrofulous disease of - 402
„ affected by scrofulous matter, from patient who had died of phthisis - - - 414
„ removal of, from a living rat 401
„ diseased, from a healthy rat 401
„ SPECIAL REPORT on the specimens of disease of, exhibited to the Society during the session of 1857-8 - - 417
„ — *table A*, cases of disease, with bronzing of the skin 420-421
„ — *table B*, cases of disease, without bronzing of the skin 422-423
„ — *table C*, bronzing of skin, unaccompanied by important disease of the capsules - 424
Syphilis, infantile, effects of, in marring the development of the teeth - - - 449
Syphilitic disease of the liver - 270
„ supposed, of lung, larynx, and liver - - - 55
Talipes equinus, preparation of iliac arteries from a male subject, an example of - - 95
„ paralyticus, femur and hip-joint, from a case of - 432
Talipes varus in both feet in case of spina-bifida in lumbo-sacral region - - - 440
TAYLOR (Mr. Robert) adhesion of the retina to the cicatrix, following the removal of the cornea - - - 362
Tears, sugar in the, from a case of diabetes - - - 447
Teeth, effects of infantile syphilis in marring the development of 449

Testicle, undeveloped left, detained in the groin - - 317
„ undeveloped and detained in the inguinal canal - 316
„ hypertrophy of the right - 317
„ enchondroma of the - 326
„ medullary cystic disease of 340
„ tubercular disease of the - 307
Thigh, blood-cyst from the - 383
Thigh-bone, impacted fracture of the neck of - - 357
THOMPSON (Mr. Henry) villous growth from the vocal cords, causing death by asphyxia 55
„ large hydatid in the liver - 294
„ two calculi of enormous size, filling the urinary bladder 295
„ enlargement of the prostate, affecting mainly its anterior portion - - - 298
„ bronzed skin; one supra-renal capsule diseased - - 411
„ *report on* Mr. Hutchinson's cases of infantile syphilis - 455
Thymus gland, enlargement of, in case of affection of the heart 163
Thyroid gland, enlargement of, in case of affection of the heart 163
Tibia, injury to, and subsequent formation and discharge of hydatids - - - 430
„ necrosis of, from a child, twenty-eight days old - - 352
Tissue, fibrous, surrounded by spiral elastic fibres, opinions of different physiologists on 16-17
TODD (Dr.) *per Mr. C. Heath*, cancer of the spine - - 350
Toes, case of nine on one foot 427
Trachea, tubular cast of, at its bifurcation - - - 52
„ tuberculous abscess of mediastinal glands, bursting into 38
„ ulceration of, aneurysm of aorta fatal by rupture into - 74
„ aneurysm of the innominate artery, opening into - 95
Tracheotomy in cancer of the larynx 39
TRAVERS (Mr. Benj., jun.) *per Mr. W. Adams*, comminuted fracture of the lower extremity of the femur, extending into the knee-joint; united with shortening and deformity - 343
Tubercular disease of the spleen 425
„ of the testicle - - 307
Tuberculous abscess of the anterio-mediastinal glands - 38
TUMOURS, morbid growths, etc. 367-400
Tumour, cystic, of the cervix uteri, removed by the ecraseur 332
„ — multi-locular, from the breast of a bitch - - 460
„ enchondromatous, of the bones of the hand - - 382
„ epithelial, of the breast 385
„ — in sheath of sciatic nerve 11
„ fatty, two specimens of 384
„ fibro-plastic, of the humerus, containing myeloid cells 367
„ — of upper extremity of humerus - - - 398
„ — in the calf of the leg 379
„ recurrent fibroid, of the uterus, pericardium, etc. - 327
„ fibrous, in the lower jaw, surrounding the dental nerve 351
„ — of the ovaries - - 299
„ — of the uterus, with calculus of inspissated bile - - 233
„ knotty, of liver - - 223
„ ovarian, large multi-locular 325
„ — multi-locular, successfully removed by abdominal section 335
„ secondary, in the lungs, in case of fibro-plastic tumour of the humerus - - 367
Tympanum, pigment in the 363
Typhoid fever, ulcer of the larynx in - - - 34
„ perforating ulcer of large intestine in - - - 199
„ diseased intestine from patient who died of, during relapse 209

Ulcer of the larynx in typhoid fever producing general emphysema 34
„ chronic, of the stomach - 279
„ — cancerous infiltration of 200
„ perforating, of the duodenum 197
„ — of the large intestine in typhoid fever - - 199
Ulceration of the aortic valves 79
„ of the wall of the left auricle 131

Ulceration of the mitral valve 131
„ perforation of mitral valve the result of - - - 117
„ of the valves of the heart, *table* of cases of - 134-144
„ — analysis of facts in ditto 145-148
„ — summary of opinions of authors on - 148-152
„ gastro-intestinal, connection of, with abscess of the liver - 241
„ of the patella, after removal of the knee-joint - - 348
„ of trachea, aneurysm of aorta fatal by rupture into - 74
Ureters, dilatation of, from pressure of ovarian cyst - - 318
Urethra, rupture of the, without symptoms until near death 337
Urinary Organs, diseases of 295-342
Urine containing cystine - 297
Uterus, recurrent fibroid tumour of 327
Uteri, series of eleven with the left ovary at a greater distance than the right one - 308
Uteri, cervix, cystic tumour of, removed by the écraseur 332

Valves, aortic, diseased - 74
„ — obstructive and regurgitant disease of - - 61
„ — aneurysm at bases of - 79
„ — deposits on - - 76
„ — ulceration of - - 79
Valves of the heart, perforation of, the result of congenital malformation, *table* of cases of - 153
„ — hypertrophy of the heart without disease of - 124
„ — ulceration of, *table* of cases of - - 134-144
„ — analysis of facts in ditto 145-148
„ — cases of true and false aneurysmal pouching of - 117
Valves, mitral, diseased - 74
„ — diseased, with hypertrophy of right ventricle - 67
„ — deposits on - - 76
„ — perforation of, the result of ulceration - - 117
„ — ulceration of - - 131

Van der Byl (Dr.) obstruction of the cerebral arteries by fibrinous plugs, in connection with deposits on the aortic and mitral valves - - 76
„ case of sudden death from contraction of the mitral orifice, and its obstruction, produced by a globular vegetation detached from the left auricle 89
„ specimens of hypertrophy of the heart, with remarks on seventy cases - - - 173
„ colloid cancer of the peritoneum, involving the great omentum, the ovaries, and the surface of the liver and the gall-bladder 207
„ medullary cancer of the common bile-duct—dilatation of all the biliary ducts—enlargement of the gall-bladder — cancerous growth in the pancreas—intense jaundice - - 228
„ specimen of cancer of the liver, with remarks on twenty-nine cases - - - 234
„ urinary calculus adherent to the bladder - - - 296
„ epithelial tumour of the breast 385
Vena cava, part of the lower, from a case of phlegmasia dolens 59
Veins, cases of supposed death from presence of air in - 156
„ femoral, part of from a case of phlegmasia dolens - 59
„ hepatic, abscesses of liver from perforation of - - 283
„ the left common and left external iliac from a case of phlegmasia dolens - - 59
„ portal, communication of hepatic ducts with - - 285
„ — pus in - - - 279
Ventricle, obstruction from membrane across the outlet from 184
„ perforation of septum of - 91
„ right, large fibrinous clot from 99
„ — hypertrophy of, from diseased mitral valve - - 67

Vertebra, sixth cervical, recurrent fibroid tumour in - 327
Villous growth from the vocal cords, causing death by asphyxia - - - 55
„ pedunculated, from visceral layer of the arachnoid - - 14
„ — intra-cystic, from the breast of a bitch - - 460
Vision, double, in a case of softening of spinal cord, etc. - 25
Vocal cords, villous growth from the, causing death by asphyxia 55
Vomiting, in a case of softening of spinal cord, etc. - - 25

WARD (Dr. Ogier) cases of Diphtherite - - 217
„ absence of the left foot in a cat 460
WELLS (Mr. Spencer) multi-locular ovarian cyst, successfully removed by ovariotomy - 321
„ Cystic tumour of the cervix uteri, removed by the écraseur 332
„ Epithelioma of the female breast 375
WILKS (Dr.) Fibro-cellular growth of the lung - - 31
„ ulcer of the larynx in typhoid fever, producing general emphysema - - - 34
„ specimens of disease of the lung, larynx and liver supposed to be syphilitic - - 55
„ cancerous nodules in the substance of the heart - 87
„ specimens of syphilitic disease of the liver - - - 270
„ three specimens of fibrous tumours of the ovaries - 299
„ — *report* on, by Dr. Bristowe and Mr. Hutchinson - 301
„ extremely degenerated kidney in Bright's disease - 308
„ case of osteoid cancer combined with myeloid disease - 377
„ *report* of Mr. Hutchinson's case of tubular casts of the intestine 189
„ *report* on Mr. Balding's case of epithelial cancer of the œsophagus - - - 195
„ see *Supra-renal capsules* (report.)
WILLIAMS (Dr. C. J. B.) congenital deficiency of the sternum, rendering visible the movements of the heart - 71
WOOD (Mr. John) case of ruptured aneurysm of the popliteal artery 122

Printed by J. W. ROCHE, 1, Lucas Street, Rotherhithe.

11D101

H. HOLZER
BOSTON, MASS.